

Clinical Reasoning: Longitudinally Extensive Spinal Cord Lesions in a Middle-aged Man

Nina Xie, MD, and Yafang Zhou, MD, PhD

Neurology® 2022;98:419-424. doi:10.1212/WNL.0000000000013260

Correspondence

Dr. Zhou
zyf_1981@csu.edu.cn

Abstract

An immunocompetent 47-year-old man presented with a five-month history of progressive lower limb weakness, back pain, sphincter dysfunction, and intermittent fever, suggesting myelopathy in a chronic deteriorating course. A comprehensive analysis comprising of blood tests, neuroimaging, CSF profiling, molecular analysis, and histopathology was performed. Notably, enhanced spinal cord MRI revealed longitudinally extensive intradural-extramedullary lesions involving the cervical, thoracic, and lumbosacral spinal cord, with homogeneous enhancement and spinal cord compression. Serum treponema pallidumhemagglutination (TPHA) and rapid plasma reagin (RPR) tests were positive. CSF profiling showed pleocytosis, significant protein elevations, hypoglycorrhachia, and positive TPHA test. 18F-FDG-PET/CT indicated slightly increased intraspinal fluorodeoxyglucose (FDG) uptake. Spinal cord biopsy further showed small round blue cells in poorly differentiated tissues. Immunostaining was positive for NKX2.2, CD56, CD99, Synaptophysin, and Ki67 (50%). Molecular analysis detected a novel MALAT-CYSLTR1 fusion protein and variants in oncogenic genes including *PTCH1*, *TERT*, *CREBBP*, *SPEN*, and *STK11*. The diagnosis of intraspinal extraosseous Ewing sarcoma (ES) was confirmed. Briefly, our case details the diagnosis of a patient with intradural-extramedullary ES and highlights the value of spinal cord biopsy in progressive myelopathy of unknown causes.

From the Department of Geriatric Neurology (N.X., Y.Z.), Xiangya Hospital, Central South University; and National Clinical Research Center for Geriatric Disorders (N.X., Y.Z.), Changsha, Hunan, China.

Go to [Neurology.org/N](https://www.neurology.org/N) for full disclosures. Funding information and disclosures deemed relevant by the authors, if any, are provided at the end of the article.

Section 1

An immunocompetent 47-year-old man presented with a five-month history of worsening lower limb weakness. Initially, he noticed numbness and weakness in the left leg and had slight gait difficulty. Over the next 5 months, the symptoms progressed to the right leg, to the point of being unable to walk. Two weeks ago, he also developed neck pain, urinary retention, and constipation. The pain was severe and persistent, radiating into the shoulders and lumbosacral region. One week before, he experienced intermittent fever. On physical examination, he was alert and oriented, with a temperature of 38.2°C and nuchal rigidity. Cranial nerves

were intact. The strength and tone of upper limbs were normal. Lower limb strength was rated 0/5 bilaterally, with decreased muscle tone. Deep tendon reflexes of the upper limbs were rated 2+. Lower limbs were areflexic. Abdominal reflexes were bilaterally absent. Babinski sign was present bilaterally. There was no ankle clonus. Sensation to pinprick and vibration were diminished below the sternal angle, suggesting a T2 sensory level.

Questions for Consideration:

1. Where would you localize the lesion?
2. What is your initial investigation approach?

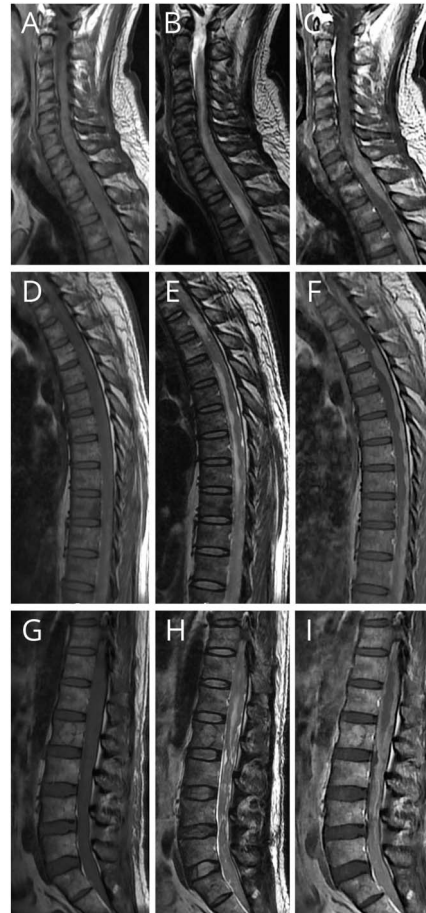GO TO SECTION 2

Section 2

Progressive lower limb weakness, sphincter dysfunction, and T2 sensory level are classic features of myelopathy. Longitudinally, the neck pain, T2 sensory level, absence of abdominal reflexes, and flaccid paralysis in lower limbs suggested involvement of the cervical, thoracic, and lumbosacral segments. Transversely, impaired structures may include anterior horns (areflexic lower limbs), posterior funiculus (diminished vibratory sensation), corticospinal tracts (presence of Babinski sign), posterior horn, and spinothalamic tracts (diminished sensation to pinprick). Temporally, because this patient has a chronic deteriorating course, disorders that worsen rapidly such as spinal cord infarction or disc herniation were less likely. Taken together, longitudinally extensive transverse myelopathy with a chronic deteriorating course should be considered at this stage. Differential diagnoses include infection, neoplasms, sarcoidosis, spinal arteriovenous fistula, demyelination, and metabolic disorders. The initial investigation approach should include routine screenings for these etiologies, as well as CSF analysis and enhanced cerebrospinal MRI.

Blood tests were notable for increased inflammatory markers and positive syphilis antibodies (eTable 1, [links.lww.com/WNL/B734](https://www.lww.com/WNL/B734)). Pulmonary CT and ECG were unremarkable. Enhanced brain and spinal cord MRI revealed longitudinally extensive lesions involving the cervical, thoracic, and lumbosacral spinal cord. The spinal cord was compressed, slightly hypointense on T1-weighted images, and hyperintense on T2-weighted images. The lesions were posterior to the spinal cord, iso-to hyperintense on T1-weighted images and hypointense on T2-weighted images, with well-defined borders and homogeneous enhancement (Figure 1). On lumbar puncture, CSF pressure was 390 mmH₂O. Less than 2 mL of yellow-colored CSF was collected because of hypercoagulability. CSF profiling showed pleocytosis (total cell count 120*10⁶/L, a white blood cell count 12*10⁶/L, polynuclear cells 60%), significant protein elevations (5.56 g/L), decreased glucose levels (1.6 mmol/L), a positive TPHA test, and a negative rapid plasma reagin test. Blood,

Figure 1 Spinal Cord MRI



(A-C) Cervical T1WI, T2WI, and enhanced spinal cord MRI. (D-F) Thoracic T1WI, T2WI, and enhanced spinal cord MRI. (G-I) Lumbosacral T1WI, T2WI, and enhanced spinal cord MRI.

urine, and stool cultures detected no bacteria or fungi, nor did the result of CSF next-generation sequencing.

Question for Consideration:

1. What is your differential diagnosis at this stage?

GO TO SECTION 3

Section 3

The ascending sensory disturbance, late-onset sphincter dysfunctions, significantly elevated CSF protein levels, and unique spinal MRI findings suggested an intradural-extramedullary lesion extending through multiple segments. In addition, the CSF hyperproteinosis, xanthochromia, and hypercoagulability indicated Froin syndrome, which together with the CSF pleocytosis and hypoglycorrhachia are highly suggestive of infectious or neoplastic disorders.

Infections that can form long segmental abscesses or granulomas in the subdural space need to be considered. Tuberculosis, fungus, and brucella were excluded as the exposure history, and relevant pathogen tests were negative. The patient was positive for TPHA in both serum and CSF, suggesting neurosyphilis. Antisyphilitic treatment with penicillin was indicated. However, the spinal MRI findings of our patient were very uncommon for neurosyphilis. Pathologically, intradural-extramedullary syphilitic myelopathy is most likely caused by syphilitic gumma.¹ The MRI findings typically present as short-segment T2 hyperintensities, with nodular or ring-like enhancement.²⁻⁶ The “flip-flop” sign, an enhanced lesion shown as hypointense signals on T2-weighted images, and the “candle guttering” sign, a flame-like enhancement of the spinal parenchyma beneath the pia mater, were thought to be characteristic.^{4,5} Our patient’s MRI lacked most of the above features.

The avid contrast enhancement on MRI and CSF changes prompt the consideration of intradural-extramedullary neoplasms. Neurofibroma, lymphoma, myxopapillary ependymoma, and spinal metastasis are not very likely, although they can cause long segmental lesions with clear margination and enhancement. Their lesions are usually hypointense on

T1-weighted images and hyperintense on T2-weighted images.^{7,8} Other neoplasms, such as melanotic schwannomas and extraosseous Ewing sarcoma, cannot be excluded because they can seem hyperintense on T1-weighted images and hypointense on T2-weighted images.^{7,9} Confirmatory diagnosis requires a biopsy.

Other diagnoses were less likely. Sarcoidosis can cause CSF changes similar to those in our patient. However, sarcoidosis typically presents as longitudinally extensive transverse myelitis with dorsal subpial enhancement.¹⁰ Intradural-extramedullary sarcoidosis is uncommon and seldom solely presents as myelopathy. Our patient lacked multisystemic manifestations such as hepatomegaly and hilar lymphadenopathy. The angiotensin converting enzyme levels and pulmonary CT were also unremarkable.

Spinal arteriovenous fistula (sAVF) can occur in the intradural-extramedullary space, spanning multiple continuous segments. Nevertheless, CSF glucose levels are often normal in sAVF. Spinal cord edema and tortuous vessels typically seem as diffuse hyperintensities and perimedullary flow voids on T2-weighted images, with linear, heterogeneous, or diffuse patchy enhancement.¹¹ The CSF profiling and absence of flow void signals in our patient argued against sAVF.

The normal brain MRI, spared optic nerves, and negative antibodies excluded primary progressive multiple sclerosis and neuromyelitis optica spectrum disorder. The normal vitamin B12 and copper levels ruled out subacute combined degeneration and copper deficiency.

Question for Consideration:

1. What would you do next?

GO TO SECTION 4

Section 4

To further distinguish between infection and neoplasm, whole-body PET/CT and spinal cord biopsy were indicated. The 18F-FDG-PET/CT indicated slightly increased intraspinal FDG uptake (SUVmax = 8.6) (Figure 1D). He underwent the surgery of laminectomy and spinal cord mass resection at the C6-T1 level. The tumor was 46*14*8 mm in size, projecting in the subarachnoid space and destroying the dorsal spinal cord. Histopathology showed small round blue cells microscopically. Immunostaining was positive for NKX2.2, CD56, CD99, synaptophysin, and Ki67 (50%) (Figure 2). Molecular analysis detected a MALAT-CYSLTR1 fusion protein and variants in oncogenic genes including *PTCH1*, *TERT*, *CREBBP*, *SPEN*, and *STK11*. The diagnosis of extrasosseous Ewing sarcoma (ES) was confirmed.

Discussion

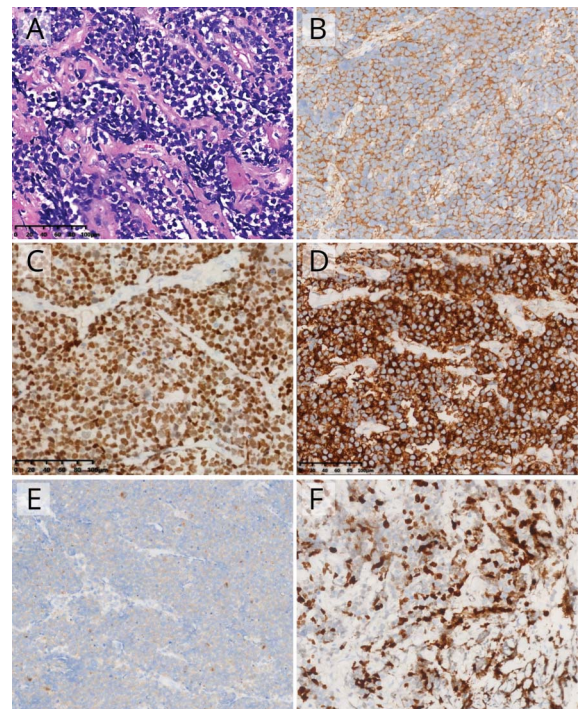
ES is an aggressive bone and soft-tissue cancer that occurs much more frequently in children than in adults. Tumors most often arise in the long bones of the limbs and pelvis, causing nonspecific symptoms such as localized pain, swelling, and weight loss. Atypically, ES can occur in extrasosseous sites, such as the liver, kidneys, uterus, orbit, bone marrow, adrenal glands, and brain, where symptoms are determined by the tumor size and location. The characteristic histopathologic findings were small round blue cells in poorly differentiated tissue, which overlaps with several other malignancies including lymphoma and metastasis from nonbone tumors. Therefore, the diagnosis of ES requires a comprehensive analysis of pathology, immunochemistry, and genetics.

Histochemically, prominent membrane expression of CD99, along with frequent expression of NKX2.2, CD56, and synaptophysin, supports the diagnosis of ES. An absence of CD99 essentially eliminates the diagnosis of ES. Genetically, the most common chromosomal translocation in ES is between *EWSR* and *FLT*. Other fusion proteins were also reported, suggesting the heterogeneity in ES is driven by the genetic signatures to some extent.¹² Multimodal treatment comprising surgery, chemotherapy, or radiotherapy remains to be the mainstay option. The prognosis is generally poor. Older age, metastasis, and high lactate dehydrogenase levels are unfavorable factors. Multidisciplinary treatment is beneficial to improve long-term survival.

Adult intradural-extramedullary ES is exceedingly rare. To our knowledge, this is the longest primary intraspinal ES lesion reported to date. The coexistence between extrasosseous ES and neurosyphilis was also reported for the first time. Syphilis has been reported to correlate with an increased risk of various cancers. However, whether there is a causal relationship between them remains undetermined.¹³

Owing to low volume of CSF sample obtained, CSF cytology was not performed. Meningeal involvement of Ewing sarcoma

Figure 2 Histopathology and Immunostaining



(A) Hematoxylin and eosin staining showed small round blue cells (magnification $\times 200$). Immunostaining was positive for (B) CD99, (C) NKX2.2, (D) CD56, (E) synaptophysin, and (F) Ki67 (magnification $\times 200$).

can yield identifiable atypical cells in CSF. Atypical cells have high nuclear cytoplasmic ratios, with irregular nuclear outlines and multiple nucleoli.¹⁴ CSF cytology should not be omitted when the CSF sample volume is adequate.

Of note, the MALAT1-CYSLTR1 fusion protein is a notable finding. MALAT1 is a long noncoding RNA that mainly functions as a cell-cycle regulator. The overexpression of MALAT1 was correlated with metastasis and poor survival in various cancers. In ES cells, MALAT1 is transcriptionally activated through the SYK/c-MYC pathway. The silencing of MALAT1 robustly induced cell apoptosis and G1 cell-cycle arrest, implicating an oncogenic role of MALAT1 in ES pathogenesis.¹⁵ More functional studies are needed to dissect the roles of MALAT1-CYSLTR1 in ES.

This patient received chemotherapy using vincristine, cyclophosphamide, and epirubicin postsurgery. His back pain was abated. However, sphincter dysfunction and paraplegia were not improved. In summary, our case detailed the diagnosis of a patient with intradural-extramedullary ES and highlighted the value of spinal cord biopsy in progressive myelopathy of unknown causes.

Data Availability

Anonymized data not published within this study will be made available by request from any qualified investigator.

Acknowledgment

We thank the patient and his family for granting permission to publish this information.

Study Funding

The authors report no targeted funding.

Disclosure

The authors report no disclosures relevant to the manuscript. Go to [Neurology.org/N](https://www.neurology.org/N) for full disclosures.

Appendix Authors

Name	Location	Contribution
Nina Xie, MD	Xiangya hospital, Central South University, Changsha, China	Clinical information collection, analysis, and manuscript preparation
Yafang Zhou, MD PhD	Xiangya hospital, Central South University, Changsha, China	Clinical information collection, analysis, and manuscript preparation

References

- Berger JR, Dean D. Neurosyphilis. *Handb Clin Neurol*. 2014;121:1461-1472.
- Nagappa M, Sinha S, Taly AB, et al. Neurosyphilis: MRI features and their phenotypic correlation in a cohort of 35 patients from a tertiary care university hospital. *Neuroradiology*. 2013;55(4):379-388.
- Dong H, Liu Z, Duan Y, et al. Syphilitic meningomyelitis misdiagnosed as spinal cord tumor: case and review. *J Spinal Cord Med*. 2021;44(5):789-793.
- Cui L, Xu Z, Hou H. Diagnosis and treatment of spinal syphilitic gumma: a case report. *Front Neurol*. 2019;10:1352.
- Yang C, Li G, Fang J, Liu H, Yang B, Xu Y. Spinal intramedullary syphilitic gumma: an unusual presentation of neurosyphilis. *World Neurosurg*. 2016;95:622 e617-622 e623.
- Yuan JL, Wang WX, Hu WL. Clinical features of syphilitic myelitis with longitudinally extensive myelopathy on spinal magnetic resonance imaging. *World J Clin Cases*. 2019;7(11):1282-1290.
- Koeller KK, Shih RY. Intradural extramedullary spinal neoplasms: radiologic-pathologic correlation. *Radiographics*. 2019;39(2):468-490.
- Iunes EA, Stavale JN, de Cassia Caldas Pessoa R, et al. Multifocal intradural extramedullary ependymoma. Case report. *J Neurosurg Spine*. 2011;14(1):65-70.
- Scantland JT, Gondim MJ, Koivuniemi AS, Fulkerson DH, Shih CS. Primary spinal intradural extraosseous ewing sarcoma in a pediatric patient: case report and review of the literature. *Pediatr Neurosurg*. 2018;53(4):222-228.
- Murphy OC, Salazar-Camelo A, Jimenez JA, et al. Clinical and MRI phenotypes of sarcoidosis-associated myelopathy. *Neurol Neuroimmunol Neuroinflamm*. 2020;7(4):e722.
- Krings T, Geibprasert S. Spinal dural arteriovenous fistulas. *AJNR Am J Neuroradiol*. 2009;30(4):639-648.
- Riggi N, Suva ML, Stamenkovic I. Ewing's sarcoma. *N Engl J Med*. 2021;384(2):154-164.
- Michalek AM, McLaughlin CC, Murphy D, Metzger BB. Historical and contemporary correlates of syphilis and cancer. *Int J Epidemiol*. 1994;23(2):381-385.
- Yu L, Craver R, Baliga M, et al. Isolated CNS involvement in Ewing's sarcoma. *Med Pediatr Oncol*. 1990;18(5):354-358.
- Sun H, Lin DC, Cao Q, et al. Identification of a novel SYK/c-MYC/MALAT1 signaling pathway and its potential therapeutic value in ewing sarcoma. *Clin Cancer Res*. 2017;23(15):4376-4387.

Announcing...

Child Neurology: A Case-Based Approach Cases From the Neurology® Resident & Fellow Section

This collaboration between the American Academy of Neurology (AAN) and the Child Neurology Society (CNS) represents a collection of reprinted cases from the past 15 years from the Neurology Resident & Fellow Section.

An invaluable resource for both adult and pediatric neurologists and trainees! FREE download: [NPub.org/cnbook](https://www.npub.org/cnbook)

The Neurology® Null Hypothesis Online Collection...

Contributing to a transparent research reporting culture!



The *Neurology* journals have partnered with the Center for Biomedical Research Transparency (CBMRT) to promote and facilitate transparent reporting of biomedical research by ensuring that all biomedical results—including negative and inconclusive results—are accessible to researchers and clinicians in the interests of full transparency and research efficiency.

Neurology's Null Hypothesis Collection is a dedicated online section for well conducted negative, inconclusive, or replication studies. View the collection at: [NPub.org/NullHypothesis](https://www.npub.org/NullHypothesis)

Neurology®

Clinical Reasoning: Longitudinally Extensive Spinal Cord Lesions in a Middle-aged Man

Nina Xie and Yafang Zhou

Neurology 2022;98:419-424 Published Online before print December 22, 2021

DOI 10.1212/WNL.0000000000013260

This information is current as of December 22, 2021

Updated Information & Services	including high resolution figures, can be found at: http://n.neurology.org/content/98/10/419.full
References	This article cites 15 articles, 3 of which you can access for free at: http://n.neurology.org/content/98/10/419.full#ref-list-1
Subspecialty Collections	This article, along with others on similar topics, appears in the following collection(s): All Spinal Cord http://n.neurology.org/cgi/collection/all_spinal_cord Spinal cord tumor http://n.neurology.org/cgi/collection/spinal_cord_tumor
Permissions & Licensing	Information about reproducing this article in parts (figures, tables) or in its entirety can be found online at: http://www.neurology.org/about/about_the_journal#permissions
Reprints	Information about ordering reprints can be found online: http://n.neurology.org/subscribers/advertise

Neurology® is the official journal of the American Academy of Neurology. Published continuously since 1951, it is now a weekly with 48 issues per year. Copyright © 2021 American Academy of Neurology. All rights reserved. Print ISSN: 0028-3878. Online ISSN: 1526-632X.

