

Teaching NeuroImages: The Trigeminal Pontine Sign

Centripetal Migration of Herpes Virus to the Central Nervous System

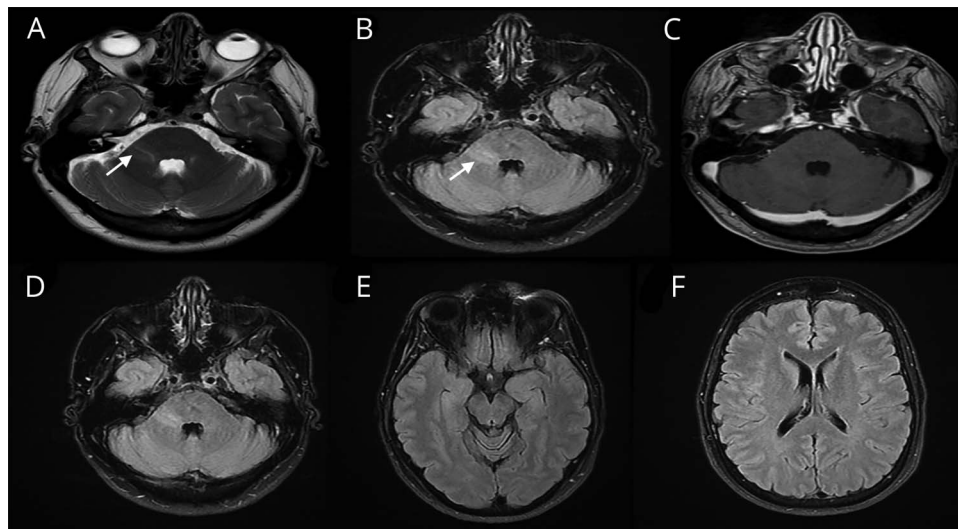
Fajun Wang, MD, and Hesham Abboud, MD, PhD

Neurology® 2021;96:e1387-e1388. doi:10.1212/WNL.00000000000010845

Correspondence

Dr. Abboud
hesham.abboud@
uhhospitals.org

Figure Brain MRI Findings



(A and B) T2-weighted and fluid-attenuated inversion recovery (FLAIR) axial images depict hyperintense band signal within the right trigeminal root entry zone (white arrow) representing sequela of limited (nondisseminated) centripetal herpetic migration from the gasserian ganglion to the trigeminal fibers. (C) T1-weighted axial postcontrast image showed no enhancement suggesting chronic sequela rather than active infection, hence the negative CSF viral studies. (D–F) FLAIR axial images 4 months later showing persistent trigeminal pontine sign and no new demyelinating lesions.

A 53-year-old woman with recurrent right lower lip cold sores presented with a 2-year history of hyperesthesia in the right V3 distribution. Brain MRI showed a nonenhancing band-like T2 hyperintensity from the trigeminal root entry zone to the dorsolateral pons (figure). Spinal fluid was negative for oligoclonal bands, HSV1/2 PCR, and varicella PCR/IgG. Repeat MRI after 4 months showed no new lesions. The trigeminal pontine sign reflects possible limited centripetal migration of herpes virus from the Gasserian ganglion to the intrapontine trigeminal fibers and sensory nucleus causing demyelination and cell death.^{1,2} It must be differentiated from other causes of demyelination like MS.

Study Funding

No targeted funding reported.

Disclosure

Dr. Wang reports no disclosures. Dr. Abboud is a consultant for Biogen, Genentech, Sanofi Genzyme, Celgene, Alexion, and Viela Bio. Go to [Neurology.org/N](https://www.neurology.org/N) for full disclosures.

MORE ONLINE

→ **Teaching Slides**
links.lww.com/WNL/B218

From the Multiple Sclerosis and Neuroimmunology Program, University Hospitals Cleveland Medical Center; and Case Western Reserve University, Cleveland, OH. Go to [Neurology.org/N](https://www.neurology.org/N) for full disclosures.

Appendix Authors

Name	Location	Contribution
Fajun Wang, MD	University Hospitals of Cleveland/Case Western Reserve University, Cleveland	Study concept and design, first draft, and literature review
Hesham Abboud, MD, PhD	University Hospitals of Cleveland/Case Western Reserve University, Cleveland	Study concept and design, data acquisition, literature review, and revised the manuscript for intellectual content

References

1. D'Amico A, Russo C, Ugga L, et al. Can pontine trigeminal T2-hyperintensity suggest herpetic etiology of trigeminal neuralgia? *Quant Imaging Med Surg* 2016;6:490–495.
2. Haanpää M, Dastidar P, Weinberg A, et al. CSF and MRI findings in patients with acute herpes zoster. *Neurology* 1998;51:1405–1411.

Neurology®

Teaching NeuroImages: The Trigeminal Pontine Sign: Centripetal Migration of Herpes Virus to the Central Nervous System

Fajun Wang and Hesham Abboud

Neurology 2021;96:e1387-e1388 Published Online before print September 14, 2020

DOI 10.1212/WNL.0000000000010845

This information is current as of September 14, 2020

Updated Information & Services	including high resolution figures, can be found at: http://n.neurology.org/content/96/9/e1387.full
References	This article cites 2 articles, 1 of which you can access for free at: http://n.neurology.org/content/96/9/e1387.full#ref-list-1
Subspecialty Collections	This article, along with others on similar topics, appears in the following collection(s): All Demyelinating disease (CNS) http://n.neurology.org/cgi/collection/all_demyelinating_disease_cns Viral infections http://n.neurology.org/cgi/collection/viral_infections
Permissions & Licensing	Information about reproducing this article in parts (figures, tables) or in its entirety can be found online at: http://www.neurology.org/about/about_the_journal#permissions
Reprints	Information about ordering reprints can be found online: http://n.neurology.org/subscribers/advertise

Neurology® is the official journal of the American Academy of Neurology. Published continuously since 1951, it is now a weekly with 48 issues per year. Copyright © 2020 American Academy of Neurology. All rights reserved. Print ISSN: 0028-3878. Online ISSN: 1526-632X.

