

# Pediatric Parainfectious Encephalitis Associated With COVID-19

Maria Gaughan, MB, BAO, BCH, Sean Connolly, MD, FRCPI, Sean O'Riordan, MD, FRCPI, Niall Tubridy, MD, FRCPI, Chris McGuigan, MD, FRCPI, and Justin A. Kinsella, MB, PhD, MRCPI

*Neurology*® 2021;96:541-544. doi:10.1212/WNL.0000000000011476

## Correspondence

Maria Gaughan  
pansophelia@gmail.com

Neurologic presentations in children with COVID-19 infection are rare. Reports of pediatric multi-inflammatory syndrome have dominated the literature, although cases of pure neurologic manifestations have been described.<sup>1-3</sup> Akinetic mutism has previously been reported in steroid-responsive COVID-19-related encephalitis.<sup>4</sup> We present the case of a 16-year-old girl who presented with visual hallucinations and ritualistic behaviors. She subsequently developed a severe encephalopathy with akinetic mutism in the context of COVID-19 infection.

## MORE ONLINE

### COVID-19 Resources

For the latest articles, invited commentaries, and blogs from physicians around the world

[NPub.org/COVID19](https://www.npub.org/COVID19)

## Methods

Consent was obtained to report this case. SARS-CoV-2 was tested via RT-PCR amplification of virus nucleic acid from a nasopharyngeal swab. SARS-COV-2 was tested in the CSF using RealStar Altona (E and S gene) RT-PCR assay. MRI brain was performed using axial T1, T2, FLAIR, and DWI and T1 postcontrast sequences.

## Case

Before presentation, the patient was medically very well but did have mild learning needs, requiring minor assistance in a mainstream school. In mid-March 2020, she complained of a sore throat. Three days later, she became very anxious before developing insomnia, anorexia, paranoia, and ritualistic behaviors. Visual hallucinations prompted referral to the emergency department for urgent psychiatric review. On attendance, temperature was elevated at 38.6°C. SARS-CoV-2 was detected and remained detectable on 6 nasopharyngeal swabs over subsequent weeks. She was persistently pyrexial and tachycardic for the first 10 days of admission. She was not hypoxic and had minimal respiratory symptoms throughout her clinical course.

Examination on admission was limited because the patient was unable to cooperate fully with commands. She was awake and tracked movement within the room. Tone, power, and reflexes seemed initially normal. She described visual and auditory hallucinations, including lions in the room leaping toward her, in a whispered manner. She feared that she had harmed members of her family. Five days postadmission, she developed mutism. She exhibited little to no voluntary motor activity. She was fed via nasogastric tube and had fecal and urinary incontinence. She demonstrated motor perseveration with repetitive scissoring movements involving her legs and circular movements involving her arms, which persisted for hours at a time and were a constant feature for the first 2 weeks of her clinical course.

Ten days after admission, bilateral limb rigidity with subtle high frequency tremor were noted; however, at this point, she had been treated with olanzapine and haloperidol, raising the possibility of an iatrogenic response.

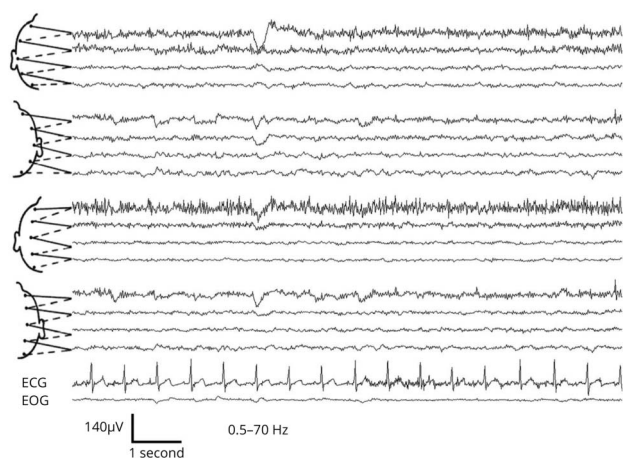
From the Neurology Department (M.G., S.O, N.T., C.M., J.A.K.), St. Vincent's University Hospital, Elm Park, Dublin 4; and Clinical Neurophysiology Department (S.C.), St. Vincent's University Hospital, Elm Park, Dublin 4.

Go to [Neurology.org/N](https://www.neurology.org/N) for full disclosures. Funding information and disclosures deemed relevant by the authors, if any, are provided at the end of the article.

**Table** Laboratory Investigations at 3 Time Points During Admission

	Time 1: D 3 post admission	Time 2: D 20–30 post admission	Time 3: D > 40 post admission
CSF WCC	2 per cmm	2 per cmm	
CSF protein	0.43 g/L	0.59 g/L	
CSF glucose	2.9 mmol/L	2.7 mmol/L	
CSF oligoclonal bands	No OCBs present	No OCBs present	
CSF HSV PCR	Negative		
CSF anti-VGKC	Negative	Negative	
CSF anti-GABA-b	Negative	Negative	
CSF anti-AMPA1 CSF anti-AMPA2	Negative	Negative	
CSF antiglycine receptor	Negative	Negative	
CSF anti-GAD	Negative	Negative	
CSF anti-NMDA	Negative	Negative	
CSF 14-3-3		Negative	
CSF S-100b		Negative	
Serum anti-AMPA1/AMPA2		Negative	Negative
Serum anti-NMDA	Negative	Negative	Negative
Serum GABAb		Negative	Negative
Serum anti-DPPX		Negative	Negative
Anti-CASPR2		Negative	Negative
Anti-LGI1		Negative	Negative
Anti-GAD antibody		Positive: 39 U/L (0–10)	Positive 10 U/L (0–10)
Anti-HIV		Negative	
Hepatitis serology		Negative	
Anti-Yo		Negative	Negative
Anti-Hu		Negative	Negative
Anti-Ri		Negative	Negative
Anti-Ma2		Negative	Negative
Anti-CV2		Negative	Negative
Anti-SOX-1		Negative	Negative
Anti-Zic-4		Negative	Negative
Anti-TR		Negative	Negative
ANA		Negative	Negative
ANCA		Negative	Negative
ENA		Positive	Negative
Anti-Ro Ab		7.7 U/mL (0.0–6.9)	
C reactive protein	3.8 mg/L (0–5)	2.6 mg/L	2.6 mg/L

**Figure** Electroencephalogram (EEG) of a 16-Year-old Girl 6 Weeks After COVID-19 Infection, Awake and Uncooperative



Ten to 20 international system of scalp electrode placement; ECG = electrocardiogram; EOG = electrooculogram;  $\mu\text{V}$  = microVolts; Hz = Hertz; bipolar montage; the tracing depicts an excess of theta and delta activity especially in the right temporal channels.

## Investigations

Laboratory investigations on admission showed normal white cell and lymphocyte count but elevated transaminases and ferritin levels. Chest X Ray was normal. CSF examination showed 2 white cells with normal protein (0.43 g/L) and glucose (2.9 mmol/L). CSF analysis for SARS-CoV-2 virus was negative. Brain MRI demonstrated 2 tiny, punctate T2/FLAIR hyperintensities in the centrum semiovale bilaterally, with no diffusion restriction or contrast enhancement. They were felt to be nonspecific based on consensus review. Autoimmune antibody panel including anti-NMDA receptor antibody, anti-glutamic acid decarboxylase (GAD), anti-DPPX, anti-AMPA1,2, anti-GABAb, anti-VGKC antibody, anti-LGI1, anti-CASPR, and antiglycine antibody was negative in CSF and serum. Infectious screen in the CSF, including HSV and VZV PCR, were negative. Two weeks later, after therapeutic intravenous immunoglobulin (IVIG), anti-GAD antibody level was positive in serum at a titre of 39 U/mL (0–10) but was negative in CSF. ANA and ANCA were negative. ENA was transiently positive with a low-positive Ro post-IVIG and was subsequently negative. Oligoclonal band testing in CSF was negative. Antibody screening was repeated in serum and CSF and was negative (table).

EEGs, performed on days 7, 32, and 72 postadmission, featured delta slowing, more prominent in the right hemisphere posteriorly; there were no epileptiform discharges, triphasic complexes, or periodic phenomena; no sleep periods were recorded (figure).

## Management

One course of IVIG (0.4 mg/kg/d) was completed over 5 days from day 3 of admission for initially suspected autoimmune encephalitis, followed by IV methylprednisolone 1 g per day over 3 days. A second course of IVIG was commenced on

day 14 but was discontinued after the patient developed a widespread rash. We did not proceed with second-line immunosuppression because of normal neuroimaging and autoantibody profile, and subtle clinical improvement. She was treated with low-dose benzodiazepines and low-dose antipsychotic medication early in her clinical course because of hallucinations and injury during perseveration.

Four weeks after initial presentation, she began to improve, with increased voluntary movement, attempts at speech with immediate family members only, and a reduction in limb rigidity and abnormal movements. Interestingly, spontaneous singing was noted before spontaneous speech. Gait remained hesitant, with a festinant quality. She was discharged home on day 98 requiring significant support in her continence, washing, and feeding, awaiting admission to an appropriate facility for ongoing rehabilitation. Although this patient had significant ongoing cognitive and physical difficulties 4 months after the onset of symptoms, at 6 months, she has exhibited significant improvement. Neurologic examination, including gait, has normalized. Speech is fluent with an engaged affect. She has regained her activities of daily living and has resumed local dance classes. She has ongoing difficulties with memory and fatigue and is awaiting detailed psychological assessment. Psychiatric symptoms have fully abated. She is due to return to school on a part-time basis. She recalls little of her prolonged hospital stay.

## Discussion

This case demonstrates severe COVID-19-associated encephalopathy in a teenage patient with mild COVID-19 respiratory symptoms. There were several clinical features characteristic of akinetic mutism including lack of voluntary spontaneous movements, absence of speech, and preserved visual tracking. Furthermore, the patient did not eat or drink of her own volition but could do so when she was fed. Motor perseveration in the context of akinetic mutism has been well described. These symptoms drove the suspicion of autoimmune encephalitis.<sup>5</sup> As with multiple other clinical cases described,<sup>6,7</sup> imaging and CSF remained normal, although advanced imaging including MR angiography was not performed in the acute phase because of resource restrictions at the height of the pandemic. Transiently positive anti-Ro and GAD antibody were felt to be most likely due to IVIG, which was commenced urgently due to the severity of symptoms.

This was a devastating, presumed parainfectious encephalopathy, with slow and incomplete recovery to date. The patient will require close neurologic and psychiatric long-term follow-up.

## Study Funding

The authors report no targeted funding.

## Disclosure

M. Gaughan, S. Connolly, S. O’Riordan, N. Tubridy, C. McGuigan, and J. Kinsella reports no disclosures relevant

to the manuscript. Go to [Neurology.org/N](https://www.neurology.org/N) for full disclosures.

## Publication History

Received by *Neurology* September 21, 2020. Accepted in final form December 23, 2020.

## Appendix Authors

Name	Location	Contribution
<b>Maria Gaughan, MB, BAO, BCH</b>	University College Dublin, St. Vincent's University Hospital	Designed and conceptualized the study, analyzed the data, and drafted the manuscript for intellectual content
<b>Sean Connolly, MD, FRCPI</b>	St. Vincent's University Hospital	Data collection and analysis and drafting and revision of manuscript

## References

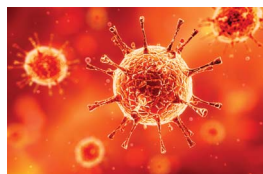
1. Dugue R, Cay-Martinez KC, Thakur KT, et al. Neurologic manifestations in an infant with COVID-19. *Neurology* 2020;94:1100–1102.
2. McAbee GN, Brosgol Y, Pavlakis S, Agha R, Gaffoor M. Encephalitis associated with COVID-19 infection in an 11-year-old child. *Pediatr Neurol* 2020;109:94.

## Appendix (continued)

Name	Location	Contribution
<b>Sean O'Riordan, MD, FRCPI</b>	St. Vincent's University Hospital	Revision of manuscript
<b>Niall Tubridy, MD, FRCPI</b>	St. Vincent's University Hospital	Drafting and revision for intellectual content
<b>Chris McGuigan, MD, FRCPI</b>	St. Vincent's University Hospital	Drafting and revision for intellectual content
<b>Justin A. Kinsella, MB, PhD, MRCPI</b>	St. Vincent's University Hospital	Study design and drafting and revision of manuscript

3. Swarz JA, Daily S, Niemi E, Hilbert SG, Ibrahim HA, Gaitanis JN. COVID-19 infection presenting as acute-onset focal status epilepticus. *Pediatr Neurol* 2020;112:7.
4. Pilotto A, Odolini S, Masciocchi S, et al. Steroid-responsive encephalitis in coronavirus disease 2019. *Ann Neurol* 2020;88:423–427.
5. Mohammad SS, Fung VSC, Grattan-Smith P, et al. Movement disorders in children with anti-NMDAR encephalitis and other autoimmune encephalopathies. *Mov Disord* 2014;29:1539–1542.
6. Guilmot A, Maldonado Sloom S, Sellimi A, et al. Immune-mediated neurological syndromes in SARS-CoV-2-infected patients. *J Neurol Epub* 2020 Jul 30.
7. Paterson RW, Brown RL, Benjamin L, et al. The emerging spectrum of COVID-19 neurology: clinical, radiological and laboratory findings. *Brain* 2020;43:3104–20.

## COVID-19 and Neurologic Disease: Call for Papers!



The editors of *Neurology* are interested in papers that address the neurological aspects of COVID-19 infection and challenges to the management of patients with chronic neurological conditions who have, or are at risk for, the infection. Relevant papers that pass initial internal review will undergo expedited peer review and online publication. We will consider papers posted in preprint servers.

Submit observational studies and clinical trials as Articles and case series and case reports under the Clinical/Scientific Notes category to <https://submit.neurology.org/> today!



## Practice Current: An interactive exchange on controversial topics

- Share your own best practices.
- Read commentary with expert opinion.
- Explore results on an interactive world map.

[NPub.org/NCP/practicecurrent](https://www.npub.org/NCP/practicecurrent)

*Neurology*® Clinical Practice

# Neurology<sup>®</sup>

## **Pediatric Parainfectious Encephalitis Associated With COVID-19**

Maria Gaughan, Sean Connolly, Sean O'Riordan, et al.

*Neurology* 2021;96;541-544 Published Online before print January 4, 2021

DOI 10.1212/WNL.0000000000011476

**This information is current as of January 4, 2021**

<b>Updated Information &amp; Services</b>	including high resolution figures, can be found at: <a href="http://n.neurology.org/content/96/11/541.full">http://n.neurology.org/content/96/11/541.full</a>
<b>References</b>	This article cites 6 articles, 1 of which you can access for free at: <a href="http://n.neurology.org/content/96/11/541.full#ref-list-1">http://n.neurology.org/content/96/11/541.full#ref-list-1</a>
<b>Citations</b>	This article has been cited by 1 HighWire-hosted articles: <a href="http://n.neurology.org/content/96/11/541.full##otherarticles">http://n.neurology.org/content/96/11/541.full##otherarticles</a>
<b>Subspecialty Collections</b>	This article, along with others on similar topics, appears in the following collection(s): <b>All Pediatric</b> <a href="http://n.neurology.org/cgi/collection/all_pediatric">http://n.neurology.org/cgi/collection/all_pediatric</a> <b>COVID-19</b> <a href="http://n.neurology.org/cgi/collection/covid_19">http://n.neurology.org/cgi/collection/covid_19</a> <b>Post-infectious</b> <a href="http://n.neurology.org/cgi/collection/postinfectious_">http://n.neurology.org/cgi/collection/postinfectious_</a>
<b>Permissions &amp; Licensing</b>	Information about reproducing this article in parts (figures, tables) or in its entirety can be found online at: <a href="http://www.neurology.org/about/about_the_journal#permissions">http://www.neurology.org/about/about_the_journal#permissions</a>
<b>Reprints</b>	Information about ordering reprints can be found online: <a href="http://n.neurology.org/subscribers/advertise">http://n.neurology.org/subscribers/advertise</a>

*Neurology*® is the official journal of the American Academy of Neurology. Published continuously since 1951, it is now a weekly with 48 issues per year. Copyright © 2021 American Academy of Neurology. All rights reserved. Print ISSN: 0028-3878. Online ISSN: 1526-632X.

