

# Teaching NeuroImages: Diffuse intrinsic pontine glioma in white matter

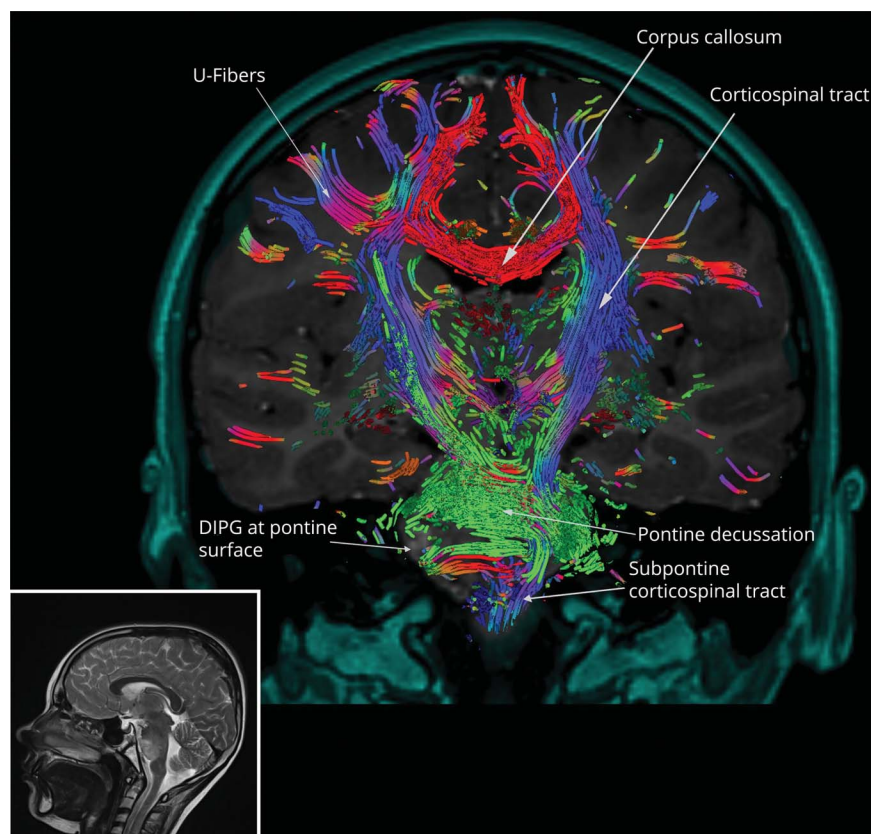
Victor M. Lu, MD, PhD, Desmond A. Brown, MD, PhD, Alfredo Quiñones-Hinojosa, MD, Kaisorn L. Chaichana, MD, and David J. Daniels, MD, PhD

## Correspondence

Dr. Daniels  
daniels.david@mayo.edu

*Neurology*® 2020;95:e608-e609. doi:10.1212/WNL.00000000000009927

**Figure** MRI of diffuse intrinsic pontine glioma (DIPG) with overlaid tractography



Coronal T1 gadolinium-enhanced MRI of DIPG with overlaid tractography, with sagittal T2 MRI provided for reference. This image was generated by Synaptive Modus Plan software featuring BrightMatter AutoSeg (Synaptive Medical Inc., Toronto, Canada).

We present an image of diffuse intrinsic pontine glioma (DIPG) showing its relationship to white matter structures based on reconstructed tractography (figure). An 8-year-old girl presented with diplopia, right abducens nerve palsy, and mild ataxia. Reconstruction showed at the level of the pontine decussation a right-sided disruption of the pontocerebellar fibers anterior to the descending corticospinal fibers involving the pontine nuclei region. Understanding the white matter tract anatomy of DIPG in relation to surrounding structures

## MORE ONLINE

→ **Teaching slides**

[links.lww.com/WNL/B128](https://links.lww.com/WNL/B128)

From the Department of Neurologic Surgery (V.M.L., D.A.B., D.J.D.), Mayo Clinic, Rochester, MN; and Department of Neurologic Surgery (A.Q.-H., K.L.C.), Mayo Clinic, Jacksonville, FL. Go to [Neurology.org/N](https://Neurology.org/N) for full disclosures. Funding information and disclosures deemed relevant by the authors, if any, are provided at the end of the article.

critical for function by this method may have the potential to assist in minimizing functional deficit risk during biopsy, but requires future validation.

### Study funding

No targeted funding reported.

### Disclosure

The authors report no disclosures relevant to the manuscript. Go to [Neurology.org/N](http://Neurology.org/N) for full disclosures.

### Appendix Authors

Name	Location	Contributions
<b>Victor M. Lu, MD, PhD</b>	Mayo Clinic, Rochester, MN	Drafted the manuscript for intellectual content
<b>Desmond A. Brown, MD, PhD</b>	Mayo Clinic, Rochester, MN	Drafted the manuscript for intellectual content
<b>Alfredo Quiñones-Hinojosa, MD</b>	Mayo Clinic, Jacksonville, FL	Revised the manuscript for intellectual content
<b>Kaisorn L. Chaichana, MD</b>	Mayo Clinic, Jacksonville, FL	Revised the manuscript for intellectual content
<b>David J. Daniels, MD, PhD</b>	Mayo Clinic, Rochester, MN	Revised the manuscript for intellectual content

# Neurology®

## Teaching NeuroImages: Diffuse intrinsic pontine glioma in white matter

Victor M. Lu, Desmond A. Brown, Alfredo Quiñones-Hinojosa, et al.

*Neurology* 2020;95:e608-e609 Published Online before print July 13, 2020

DOI 10.1212/WNL.0000000000009927

### This information is current as of July 13, 2020

<b>Updated Information &amp; Services</b>	including high resolution figures, can be found at: <a href="http://n.neurology.org/content/95/5/e608.full">http://n.neurology.org/content/95/5/e608.full</a>
<b>Subspecialty Collections</b>	This article, along with others on similar topics, appears in the following collection(s): <b>All Pediatric</b> <a href="http://n.neurology.org/cgi/collection/all_pediatric">http://n.neurology.org/cgi/collection/all_pediatric</a> <b>MRI</b> <a href="http://n.neurology.org/cgi/collection/mri">http://n.neurology.org/cgi/collection/mri</a> <b>Primary brain tumor</b> <a href="http://n.neurology.org/cgi/collection/primary_brain_tumor">http://n.neurology.org/cgi/collection/primary_brain_tumor</a>
<b>Permissions &amp; Licensing</b>	Information about reproducing this article in parts (figures, tables) or in its entirety can be found online at: <a href="http://www.neurology.org/about/about_the_journal#permissions">http://www.neurology.org/about/about_the_journal#permissions</a>
<b>Reprints</b>	Information about ordering reprints can be found online: <a href="http://n.neurology.org/subscribers/advertise">http://n.neurology.org/subscribers/advertise</a>

*Neurology*® is the official journal of the American Academy of Neurology. Published continuously since 1951, it is now a weekly with 48 issues per year. Copyright © 2020 American Academy of Neurology. All rights reserved. Print ISSN: 0028-3878. Online ISSN: 1526-632X.

