

Teaching NeuroImages: Nonketotic hyperglycemic hyperosmolar state mimicking acute ischemic stroke

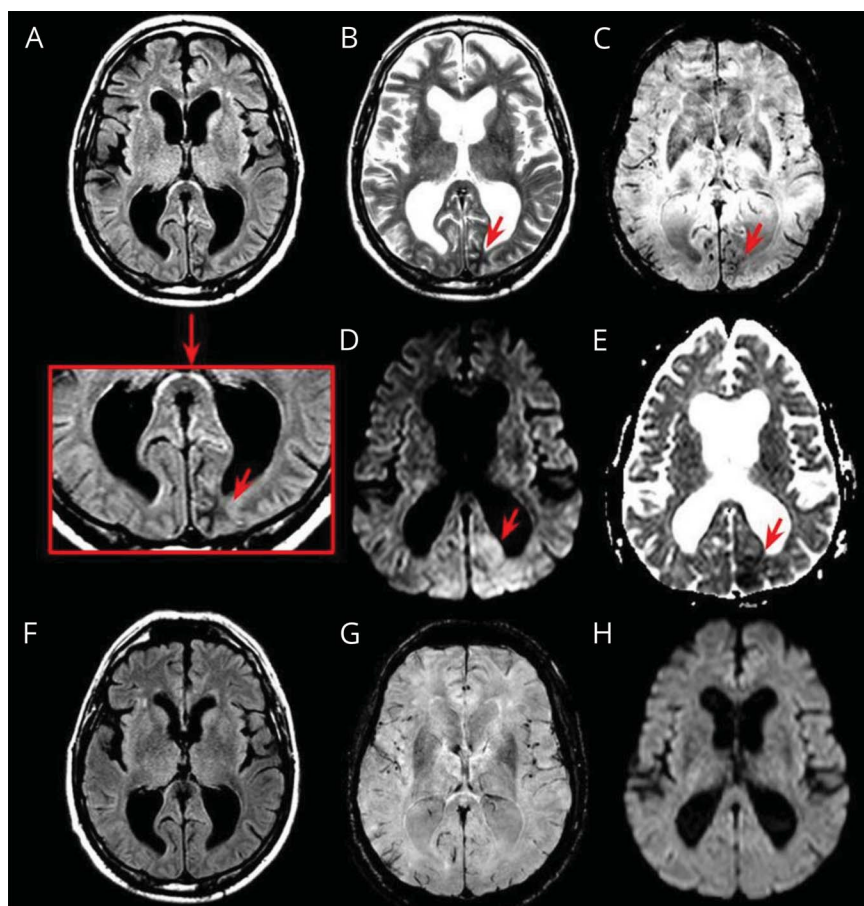
Marta I. Bala, MD, Anibal Chertcoff, MD, Miguel Saucedo, MD, Fabio Gonzalez, MD, Luis A. Miquelini, MD, Pablo Bonardo, MD, and Ricardo Reisin, MD

Neurology® 2020;95:e2600-e2601. doi:10.1212/WNL.000000000010649

Correspondence

Dr. Bala
martainesbb@gmail.com

Figure Occipital MRI changes in nonketotic hyperglycemic hyperosmolar state



On admission, brain MRI showed a left subcortical occipital lesion that was hypointense on fluid-attenuated inversion recovery, T2, susceptibility-weighted imaging, and apparent diffusion coefficient map (A–C and E) and hyperintense on diffusion-weighted imaging (D). A control brain MRI performed at 3 months was normal (F–H).

A 55-year-old man with diabetes mellitus type 2 presented with persistent right homonymous hemianopia of 72 hours evolution. At admission, the laboratory examination revealed blood glucose of 497 mg/dL and hyperosmolality without ketosis; the EEG did not show epileptic discharges. EEG done during the following days did not show any abnormalities. Brain MRI

MORE ONLINE

→ **Teaching slides**
links.lww.com/WNL/B190

From the Departments of Neurology (M.I.B., A.C., M.S., F.G., P.B., R.R.) and Neuroradiology (L.A.M.), Hospital Británico de Buenos Aires, Argentina.

Go to Neurology.org/N for full disclosures. Funding information and disclosures deemed relevant by the authors, if any, are provided at the end of the article.

showed a subcortical lesion on the left occipital lobe (figure). The patient's symptoms and MRI abnormalities resolved after glucose-lowering treatment.

Nonketotic hyperglycemic hyperosmolar state is a condition associated with neurologic deficits that could mimic an acute ischemic stroke. The underlying mechanisms for MRI findings in this condition have not been fully elucidated, but it has been postulated that increased plasma osmolality with the subsequent development of hyperviscosity may lead to a hypoxic–ischemic insult resulting in the release of free radicals in the brain.^{1,2}

Study funding

No targeted funding reported.

Disclosure

The authors report no disclosures relevant to the manuscript. Go to Neurology.org/N for full disclosures.

Appendix Authors

Name	Location	Contribution
Marta I. Bala, MD	Hospital Britanico, Buenos Aires, Argentina	Study concept and design, drafting of the manuscript, critical revision of the manuscript

Appendix (continued)

Name	Location	Contribution
Anibal Chertcoff, MD	Hospital Britanico, Buenos Aires, Argentina	Drafting of the manuscript, critical revision of the manuscript
Miguel Saucedo, MD	Hospital Britanico, Buenos Aires, Argentina	Drafting of the manuscript, critical revision of the manuscript
Fabio Gonzalez, MD	Hospital Britanico, Buenos Aires, Argentina	Drafting of the manuscript, critical revision of the manuscript
Luis A. Miquelini, MD	Hospital Britanico, Buenos Aires, Argentina	Drafting of the manuscript, critical revision of the manuscript
Pablo Bonardo, MD	Hospital Britanico, Buenos Aires, Argentina	Drafting of the manuscript, critical revision of the manuscript
Ricardo Reisin, MD	Hospital Britanico, Buenos Aires, Argentina	Drafting of the manuscript, critical revision of the manuscript

References

1. Raghavendra S, Ashalatha R, Thomas SV, Kesavadas C. Focal neuronal loss, reversible subcortical focal T2 hypointensity in seizures with a nonketotic hyperglycemic hyperosmolar state. *Neuroradiology* 2007;49:299–305.
2. Strowd RE, Wabnitz A, Balakrishnan N, Craig J, Tegeler CH. Clinical reasoning: acute-onset homonymous hemianopia with hyperglycemia. *Neurology* 2014;82:e129–e133.

Neurology®

Teaching NeuroImages: Nonketotic hyperglycemic hyperosmolar state mimicking acute ischemic stroke

Marta I. Bala, Anibal Chertcoff, Miguel Saucedo, et al.

Neurology 2020;95:e2600-e2601 Published Online before print August 14, 2020

DOI 10.1212/WNL.0000000000010649

This information is current as of August 14, 2020

Updated Information & Services	including high resolution figures, can be found at: http://n.neurology.org/content/95/18/e2600.full
References	This article cites 2 articles, 1 of which you can access for free at: http://n.neurology.org/content/95/18/e2600.full#ref-list-1
Subspecialty Collections	This article, along with others on similar topics, appears in the following collection(s): All Cerebrovascular disease/Stroke http://n.neurology.org/cgi/collection/all_cerebrovascular_disease_stroke Clinical neurology history http://n.neurology.org/cgi/collection/clinical_neurology_history Endocrine http://n.neurology.org/cgi/collection/endocrine Infarction http://n.neurology.org/cgi/collection/infarction Visual loss http://n.neurology.org/cgi/collection/visual_loss
Permissions & Licensing	Information about reproducing this article in parts (figures, tables) or in its entirety can be found online at: http://www.neurology.org/about/about_the_journal#permissions
Reprints	Information about ordering reprints can be found online: http://n.neurology.org/subscribers/advertise

Neurology® is the official journal of the American Academy of Neurology. Published continuously since 1951, it is now a weekly with 48 issues per year. Copyright © 2020 American Academy of Neurology. All rights reserved. Print ISSN: 0028-3878. Online ISSN: 1526-632X.

