

Teaching NeuroImages: X-linked adrenoleukodystrophy

Spinocerebellar variant

Lisa W.C. Au, MD, Anne Y.Y. Chan, MD, and Vincent C.T. Mok, MD

Neurology® 2019;93:e731-e732. doi:10.1212/WNL.0000000000007958

Correspondence

Dr. Au
lisaau@cuhk.edu.hk

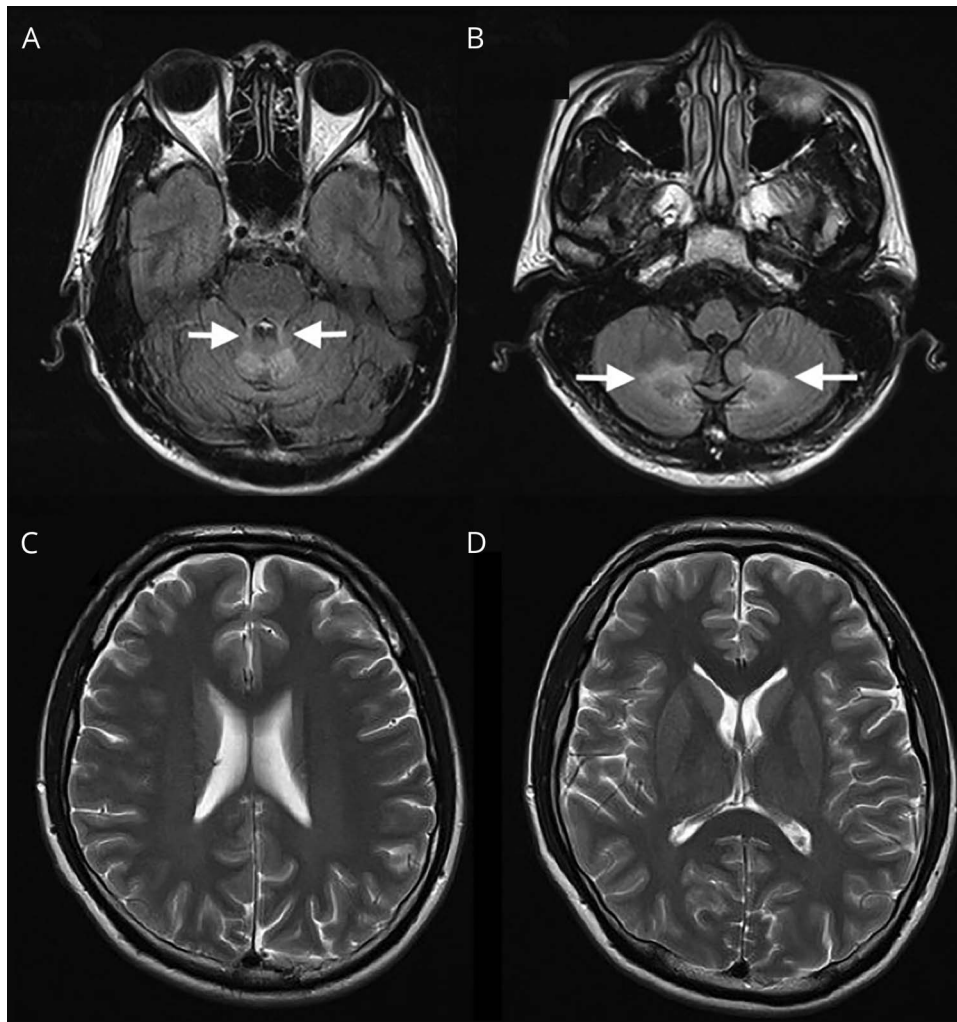
A 29-year-old previously healthy man presented with 2 months' history of progressive dysarthria and unsteady gait. Examination revealed dysmetria, lower limbs hyperreflexia, and ankle

MORE ONLINE

→Teaching slides

links.lww.com/WNL/A940

Figure MRI brain of the patient



Axial fluid-attenuated inversion recovery images show hyperintensity over bilateral middle cerebellar peduncles (A) and cerebellar white matter (B). The cerebral cortex is spared, as shown on axial T2 images (C, D).

From Lui Che Woo Institute of Innovative Medicine, Margaret K.L. Cheung Research Centre for Management of Parkinsonism, Chinese University of Hong Kong. Go to Neurology.org/N for full disclosures. Funding information and disclosures deemed relevant by the authors, if any, are provided at the end of the article.

clonus. MRI showed symmetrical T2/fluid-attenuated inversion recovery hyperintensity over bilateral middle cerebellar peduncles and cerebellar white matter but sparing the cerebral cortex (figure). Very long-chain fatty acids were detected in blood. Genetic testing showed hemizygous p.Arg554His mutation in the *ABCD1* gene, confirming the diagnosis of adrenoleukodystrophy (ALD). ALD is an X-linked peroxisomal disorder.¹ Lesions are typically found in the cerebral white matter. The spinocerebellar variant is a rare phenotype and has been estimated to account for 1%–2% of ALD.²

Study funding

No targeted funding reported.

Disclosure

The authors report no disclosures relevant to the manuscript. Go to Neurology.org/N for full disclosures.

Appendix Authors

Name	Location	Role	Contribution
Lisa W.C. Au, MD	Chinese University of Hong Kong, HKSAR	Author	Designed and conceptualized study, analyzed the data, drafted the manuscript for intellectual content
Anne Y.Y. Chan, MD	Chinese University of Hong Kong, HKSAR	Author	Major role in the acquisition of data
Vincent C.T. Mok, MD	Chinese University of Hong Kong, HKSAR	Author	Revised the manuscript for intellectual content

References

1. Kemp S, Pujol A, Waterham HR, et al. *ABCD1* mutations and the X-linked adrenoleukodystrophy mutation database: role in diagnosis and clinical correlations. *Hum Mutat* 2001;18:499–515.
2. Chen YH, Lee YC, Tsai YS, et al. Unmasking adrenoleukodystrophy in a cohort of cerebellar ataxia. *PLoS One* 2017;12:e0177296.

Neurology®

Teaching NeuroImages: X-linked adrenoleukodystrophy: Spinocerebellar variant

Lisa W.C. Au, Anne Y.Y. Chan and Vincent C.T. Mok

Neurology 2019;93:e731-e732

DOI 10.1212/WNL.0000000000007958

This information is current as of August 12, 2019

Updated Information & Services	including high resolution figures, can be found at: http://n.neurology.org/content/93/7/e731.full
References	This article cites 2 articles, 0 of which you can access for free at: http://n.neurology.org/content/93/7/e731.full#ref-list-1
Subspecialty Collections	This article, along with others on similar topics, appears in the following collection(s): Gait disorders/ataxia http://n.neurology.org/cgi/collection/gait_disorders_ataxia Leukodystrophies http://n.neurology.org/cgi/collection/leukodystrophies
Permissions & Licensing	Information about reproducing this article in parts (figures, tables) or in its entirety can be found online at: http://www.neurology.org/about/about_the_journal#permissions
Reprints	Information about ordering reprints can be found online: http://n.neurology.org/subscribers/advertise

Neurology® is the official journal of the American Academy of Neurology. Published continuously since 1951, it is now a weekly with 48 issues per year. Copyright © 2019 American Academy of Neurology. All rights reserved. Print ISSN: 0028-3878. Online ISSN: 1526-632X.

