

Teaching NeuroImages: Acute convexity subarachnoid hemorrhage

An underrecognized presentation of CAA-ri

Aikaterini Theodorou, MD, Stefanos Lachanis, MD, Palaiologos Alexopoulos, MD, Lina Palaiodimou, MD, Nikoletta Kollia, MD, Konstantinos Voumvourakis, MD, PhD, and Georgios Tsvigoulis, MD, PhD, MSc, FESO

Neurology® 2019;93:e524-e525. doi:10.1212/WNL.0000000000007873

Correspondence

Dr. Theodorou
kattheo24@gmail.com

MORE ONLINE

→Teaching slides

links.lww.com/WNL/A935

Nontraumatic acute convexity subarachnoid hemorrhage (cSAH) is a common manifestation of cerebral amyloid angiopathy (CAA), but has been rarely reported in patients with CAA-related inflammation (CAA-ri).^{1,2}

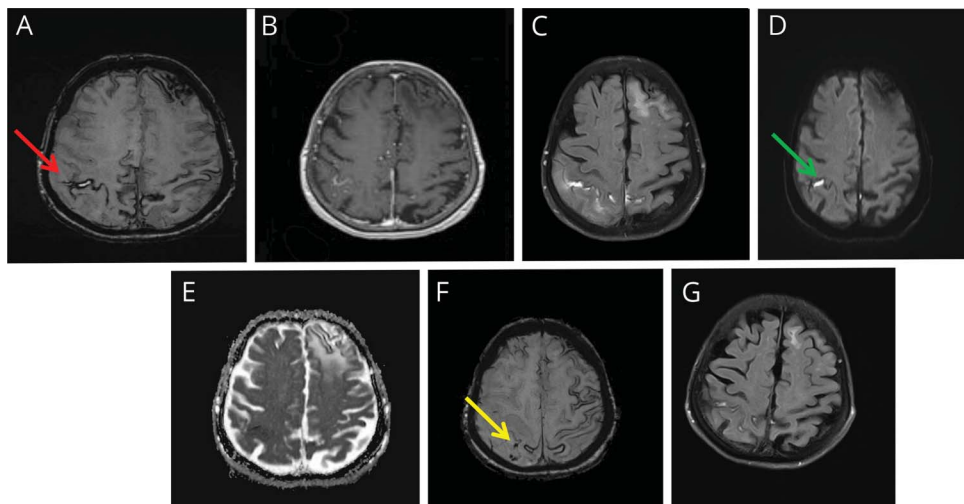
We describe the neuroimaging findings of an 89-year-old woman presenting with a 1-month history of visual hallucinations, disorientation, and agitation. Brain MRI (figure, A–F) showed disseminated cortical superficial siderosis, cerebral microbleeds, and asymmetric white matter hyperintensities in both hemispheres. There was also subacute cSAH in right parietal lobe with diffusion restriction and gadolinium enhancement in subarachnoid space.

The patient fulfilled CAA-ri diagnostic criteria and was treated with IV methylprednisolone with clinical and radiologic (figure, G) improvement.

Study funding

No targeted funding reported.

Figure Imaging



Axial susceptibility-weighted imaging (SWI) shows convexity subarachnoid hemorrhage (red arrow, A). There was evidence of gadolinium enhancement in the subarachnoid space (B) and asymmetric white matter hyperintensities on fluid-attenuated inversion recovery sequences (C). Diffusion restriction was documented on right parietal lobe (green arrow, D; E). Cortically located cerebral microbleeds were also documented on SWI (yellow arrow, F). Right parietal white matter hyperintensities resolved following corticosteroid treatment (G).

From the Second Department of Neurology (A.T., P.A., L.P., N.K., K.V., G.T.), National and Kapodistrian University of Athens, School of Medicine, "Attikon" University Hospital; Iatropolis Magnetic Resonance Diagnostic Centre (S.L.), Athens, Greece; and Department of Neurology (G.T.), The University of Tennessee Health Science Center, Memphis.

Go to Neurology.org/N for full disclosures. Funding information and disclosures deemed relevant by the authors, if any, are provided at the end of the article.

Disclosure

The authors report no disclosures relevant to the manuscript. Go to Neurology.org/N for full disclosures.

Appendix Authors

Name	Location	Role	Contribution
Aikaterini Theodorou, MD	"Attikon" University Hospital, Athens, Greece	Author	Drafting and revising the manuscript
Stefanos Lachanis, MD	Iatropolis Magnetic Resonance Diagnostic Centre, Athens, Greece	Author	Data collection, critical comments during manuscript revision
Palaiologos Alexopoulos, MD	"Attikon" University Hospital, Athens, Greece	Author	Critical comments during manuscript revision
Lina Palaodimou, MD	"Attikon" University Hospital, Athens, Greece	Author	Data collection, critical comments during manuscript revision

Appendix *(continued)*

Name	Location	Role	Contribution
Nikoletta Kollia, MD	"Attikon" University Hospital, Athens, Greece	Author	Data collection, critical comments during manuscript revision
Konstantinos Voumvourakis, MD, PhD	"Attikon" University Hospital, Athens, Greece	Author	Data collection, critical comments during manuscript revision
Georgios Tsigoulis, MD, PhD, MSc, FESO	"Attikon" University Hospital, Athens, Greece; The University of Tennessee Health Science Center, Memphis	Author	Data collection, drafting the manuscript

References

1. Salvarani C, Morris JM, Giannini C, et al. Imaging findings of cerebral amyloid angiopathy, A β -related angiitis (ABRA), and cerebral amyloid angiopathy-related inflammation: a single-institution 25-year experience. *Medicine* 2016;95:e3613.
2. Chung KK, Anderson NE, Hutchinson D, Synek B, Barber PA. Cerebral amyloid angiopathy related inflammation: three case reports and a review. *J Neurol Neurosurg Psychiatry* 2011;82:20–26.

Neurology[®]

Teaching NeuroImages: Acute convexity subarachnoid hemorrhage: An underrecognized presentation of CAA-ri

Aikaterini Theodorou, Stefanos Lachanis, Palaiologos Alexopoulos, et al.

Neurology 2019;93:e524-e525

DOI 10.1212/WNL.00000000000007873

This information is current as of July 29, 2019

Updated Information & Services	including high resolution figures, can be found at: http://n.neurology.org/content/93/5/e524.full
References	This article cites 2 articles, 1 of which you can access for free at: http://n.neurology.org/content/93/5/e524.full#ref-list-1
Subspecialty Collections	This article, along with others on similar topics, appears in the following collection(s): Hallucinations http://n.neurology.org/cgi/collection/hallucinations MRI http://n.neurology.org/cgi/collection/mri Subarachnoid hemorrhage http://n.neurology.org/cgi/collection/subarachnoid_hemorrhage
Permissions & Licensing	Information about reproducing this article in parts (figures, tables) or in its entirety can be found online at: http://www.neurology.org/about/about_the_journal#permissions
Reprints	Information about ordering reprints can be found online: http://n.neurology.org/subscribers/advertise

Neurology® is the official journal of the American Academy of Neurology. Published continuously since 1951, it is now a weekly with 48 issues per year. Copyright © 2019 American Academy of Neurology. All rights reserved. Print ISSN: 0028-3878. Online ISSN: 1526-632X.

