



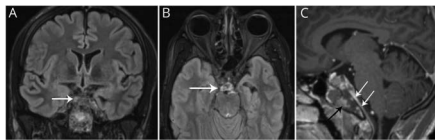
John J. Millichap, MD, FAAN, Editor  
Roy E. Strowd III, MD, Deputy Editor



## A summary of recently published articles in the *Neurology*<sup>®</sup> Resident & Fellow Section

 [facebook.com/AANResidentsAndFellows](https://www.facebook.com/AANResidentsAndFellows)

 [#NeurologyRF](https://twitter.com/NeurologyRF)



## September 3, 2019 issue

This issue contains a Global & Community Health piece that discusses neurologic care for Latinos in South Philadelphia. Two Teaching NeuroImages are also featured in this issue. The first describes an

unusual case report of cranial neuropathies following clival infarct while the second case illustrates frontal lobe *Streptococcus* abscess.

### Global & Community Health: Neurologic care for Latinos in South Philadelphia: Global health at home

In this article, we highlight 2 patient narratives from our residency program's work with Puentes de Salud, a local nonprofit organization in Philadelphia that offers medical care to the Latino community.

Page 461

### Teaching NeuroImages: Cranial neuropathies following clival infarct

This article describes an unusual case report of bony infarct of the clivus secondary to sickle cell disease resulting in cranial neuropathies.

Page e1031

### Teaching NeuroImages: Frontal lobe *Streptococcus* abscess

In this case, we describe a 21-year-old woman who presented generalized tonic-clonic seizure and 2 days of worsening headaches.

Page e1032

## September 10, 2019 issue

This issue starts with a Child Neurology article that discusses the approach to patients with multiple abnormal movements. The issue also includes a Teaching NeuroImages case that demonstrates a sleep-onset REM period during routine EEG. A Teaching Video NeuroImage describes characteristic head jerks due to Joubert syndrome.

### MORE ONLINE

#### Editor's Blog

[NPub.org/rf/blog](https://www.npub.org/rf/blog)

#### Neurology Podcast

[NPub.org/rf](https://www.npub.org/rf)

#### Resident & Fellow Clinical Reasoning Book

[NPub.org/crb](https://www.npub.org/crb)

#### Resident & Fellow ePearls

[NPub.org/epearls](https://www.npub.org/epearls)

## **Child Neurology: Spastic paraparesis and dystonia with a novel *ADCY5* mutation**

In this article, we discuss the approach to patients with multiple abnormal movements, with a focus on childhood-onset spastic paraparesis, as well as a review of the *ADCY5* gene and *ADCY5*-related dyskinesias.

[Page 510](#)

## **Teaching NeuroImages: Sleep-onset REM period during routine EEG**

In this article, we demonstrate a manifestation of sleep-onset REM period, a clearly abnormal but underappreciated EEG finding that in the inpatient setting frequently represents sleep deprivation rather than narcolepsy.

[Page e1123](#)

## **Teaching Video NeuroImages: Characteristic head jerks in congenital oculomotor apraxia due to Joubert syndrome**

A 29-year-old man presented in our clinic due to repetitive head jerks since his first year of life, which were previously diagnosed as tics. Examination revealed difficulties initiating voluntary saccades in the horizontal plane and disturbed hand-eye coordination with compensatory head thrusts.

[Page e1125](#)

## **September 17, 2019 issue**

The Clinical Reasoning article in this issue presents a case of a 58-year-old man with hand tremor and episodes of neck pain. The 2 Teaching NeuroImages featured in this issue describe cases dealing with neurolymphomatosis and Sneddon syndrome.

## **Clinical Reasoning: A 58-year-old man with hand tremor and episodes of neck pain**

We present a case of *SNCA* duplication debuting with hand tremor, severe dysautonomia, and dementia. Despite fulfilling the diagnostic criteria for dementia with Lewy bodies, the tempo of progression and the presence of positive family history led us to consider targeted genetic testing.

[Page 557](#)

## **Teaching NeuroImages: Neurolymphomatosis**

We present a PET scan showing neoplastic invasion of nerve roots and plexi with neuroanatomy visualized in rare detail, fitting with the patient's symptoms and examination.

[Page e1229](#)

## **Teaching NeuroImages: Sneddon syndrome**

A 34-year-old woman presented with acute onset left facial weakness and dysarthria. Examination showed diffuse livedo racemose.

[Page e1227](#)

## **September 24, 2019 issue**

The Mystery Case in this issue discusses bilateral Claude syndrome. This issue also features 2 Teaching NeuroImages. The first reports a case with adult-onset cerebral X-linked adrenoleukodystrophy with frontal lobe involvement. The second describes thermal imaging in Horner syndrome.

## **Mystery Case: Bilateral Claude syndrome**

A 59-year-old man with hypertension, hyperlipidemia, and type 2 diabetes presented with sudden-onset, bilateral ptosis, ataxia, and confusion. Examination showed bilateral ophthalmoparesis sparing minimal adduction and abduction, poorly reactive and dilated pupils, and global ataxia.

[Page 599](#)

## **Teaching NeuroImages: Frontal lobe involvement in adult-onset cerebral X-linked adrenoleukodystrophy**

We report a case with adult-onset cerebral X-linked adrenoleukodystrophy with frontal lobe involvement.

[Page e1326](#)

## **Teaching NeuroImages: Thermal imaging in Horner syndrome**

A 50-year-old woman with a history of fibromuscular dysplasia presented to the Emergency Department with 1 day of right ear pain.

[Page e1324](#)

# Neurology<sup>®</sup>

**Resident & Fellow Rounds**  
John J. Millichap and Roy E. Strowd III  
*Neurology* 2019;93;597-598  
DOI 10.1212/WNL.00000000000008170

**This information is current as of September 24, 2019**

**Updated Information & Services**

including high resolution figures, can be found at:  
<http://n.neurology.org/content/93/13/597.full>

**Permissions & Licensing**

Information about reproducing this article in parts (figures, tables) or in its entirety can be found online at:  
[http://www.neurology.org/about/about\\_the\\_journal#permissions](http://www.neurology.org/about/about_the_journal#permissions)

**Reprints**

Information about ordering reprints can be found online:  
<http://n.neurology.org/subscribers/advertise>

*Neurology*® is the official journal of the American Academy of Neurology. Published continuously since 1951, it is now a weekly with 48 issues per year. Copyright © 2019 American Academy of Neurology. All rights reserved. Print ISSN: 0028-3878. Online ISSN: 1526-632X.

