

# Teaching NeuroImages: Sneddon syndrome

Ahmad Almutlaq, MBBS, Mohammed Alshurem, MD, FRCPC, Myriam Levesque-Roy, MD, and Rami Massie, MD, FRCPC

*Neurology*® 2019;93:e1227-e1228. doi:10.1212/WNL.0000000000008137

## Correspondence

Dr. Almutlaq  
Ahmad.almutlaq@  
mail.mcgill.ca

## MORE ONLINE

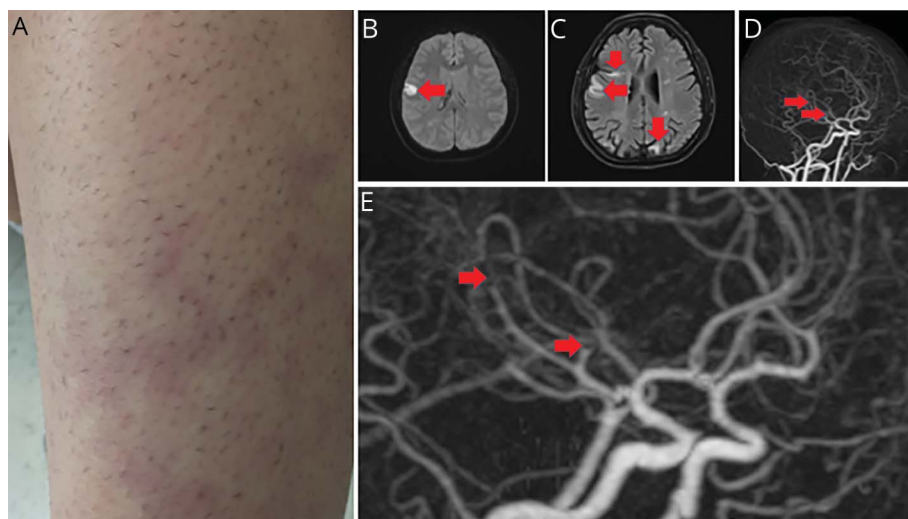
### →Teaching slides

[links.lww.com/WNL/A954](https://links.lww.com/WNL/A954).

A 34-year-old woman presented with acute onset left facial weakness and dysarthria. Examination showed diffuse livedo racemosa (figure, A). Brain MRI demonstrated right frontal acute stroke (figure, B), with numerous chronic ischemic lesions in the deep white matter (figure, C). CT angiogram revealed multiple irregularities along the cortical branches of intracranial vessels (figure, D and E). Skin biopsy was nonspecific.<sup>1</sup> Extensive immunologic, hematologic, and infectious workup was unremarkable.<sup>2</sup> The patient was diagnosed with Sneddon syndrome and discharged on aspirin.

Sneddon syndrome is a noninflammatory arteriopathy presenting classic neurovascular and dermatological signs. Often associated with antiphospholipid syndrome or autoimmune disorders, its pathophysiology remains unknown.

**Figure** Skin examination, brain MRI, and conventional angiography



(A) Skin examination shows network-like violaceous-erythematous patches in the legs consistent with livedo racemosa (arms and trunk are not shown). (B) Brain MRI shows restricted diffusion in the right frontal lobe (arrows) with corresponding reduced signal on apparent diffusion coefficient consistent with acute ischemic stroke (not shown). (C) Fluid attenuated inversion recovery sequence shows numerous chronic ischemic lesions in the deep white matter and cortical-subcortical regions of both cerebral hemispheres (arrow). (D and E) Brain CT angiogram shows multiple irregularities along the cortical branches of the right and left middle cerebral arteries, mainly at the M2 and M3 levels (arrows). Similar irregularities are present along the right posterior cerebral artery (not shown).

## Study funding

No targeted funding reported.

From the Department of Neurology and Neurosurgery (A.A., M.A., M.L., R.M.), McGill University, Montreal, QC, Canada, National Neuroscience Institute (A.A.), King Fahad Medical City, Riyadh, Saudi Arabia, Department of Neurology (M.A.), College of Medicine, Imam Abdulrahman Bin Faisal University, Dammam, Saudi Arabia.

Go to [Neurology.org/N](https://Neurology.org/N) for full disclosures. Funding information and disclosures deemed relevant by the authors, if any, are provided at the end of the article.

---

## Appendix Authors

Name	Location	Role	Contribution
<b>Ahmad Almutlaq, MBBS</b>	McGill University, Montreal, Canada	Author	Literature review, data analysis, and drafting and revision of the manuscript
<b>Mohammed Alshurem, MD FRCPC</b>	McGill University, Montreal, Canada	Author	Primary clinical care of the patient and revision of the manuscript
<b>Myriam Levesque-Roy, MD</b>	McGill University, Montreal, Canada	Author	Data drafting and revision of the manuscript
<b>Rami Massie, MD, FRCPC</b>	McGill University, Montreal, Canada	Author	Primary clinical care of the patient and revision of the manuscript

## Disclosure

The authors report no disclosures relevant to the manuscript. Go to [Neurology.org/N](http://Neurology.org/N) for full disclosures.

## References

1. Sneddon IB. Cerebrovascular lesions and livedo reticularis. *Br J Dermatol* 1965;77:180–185.
2. Francès C, Papo T, Wechsler B, Laporte JL, Biousse V, Piette JC. Sneddon syndrome with or without antiphospholipid antibodies: a comparative study in 46 patients. *Medicine (Baltimore)* 1999;78:209–219.

# Neurology®

## Teaching NeuroImages: Sneddon syndrome

Ahmad Almutlaq, Mohammed Alshurem, Myriam Levesque-Roy, et al.

*Neurology* 2019;93:e1227-e1228

DOI 10.1212/WNL.00000000000008137

**This information is current as of September 16, 2019**

<b>Updated Information &amp; Services</b>	including high resolution figures, can be found at: <a href="http://n.neurology.org/content/93/12/e1227.full">http://n.neurology.org/content/93/12/e1227.full</a>
<b>References</b>	This article cites 2 articles, 0 of which you can access for free at: <a href="http://n.neurology.org/content/93/12/e1227.full#ref-list-1">http://n.neurology.org/content/93/12/e1227.full#ref-list-1</a>
<b>Subspecialty Collections</b>	This article, along with others on similar topics, appears in the following collection(s): <b>All Cerebrovascular disease/Stroke</b> <a href="http://n.neurology.org/cgi/collection/all_cerebrovascular_disease_stroke">http://n.neurology.org/cgi/collection/all_cerebrovascular_disease_stroke</a> <b>Other cerebrovascular disease/ Stroke</b> <a href="http://n.neurology.org/cgi/collection/other_cerebrovascular_disease_stroke">http://n.neurology.org/cgi/collection/other_cerebrovascular_disease_stroke</a> <b>Stroke in young adults</b> <a href="http://n.neurology.org/cgi/collection/stroke_in_young_adults">http://n.neurology.org/cgi/collection/stroke_in_young_adults</a>
<b>Permissions &amp; Licensing</b>	Information about reproducing this article in parts (figures, tables) or in its entirety can be found online at: <a href="http://www.neurology.org/about/about_the_journal#permissions">http://www.neurology.org/about/about_the_journal#permissions</a>
<b>Reprints</b>	Information about ordering reprints can be found online: <a href="http://n.neurology.org/subscribers/advertise">http://n.neurology.org/subscribers/advertise</a>

*Neurology*® is the official journal of the American Academy of Neurology. Published continuously since 1951, it is now a weekly with 48 issues per year. Copyright © 2019 American Academy of Neurology. All rights reserved. Print ISSN: 0028-3878. Online ISSN: 1526-632X.

