

Teaching NeuroImages: Steroid-responsive leukoencephalopathy in inflammatory cerebral amyloid angiopathy

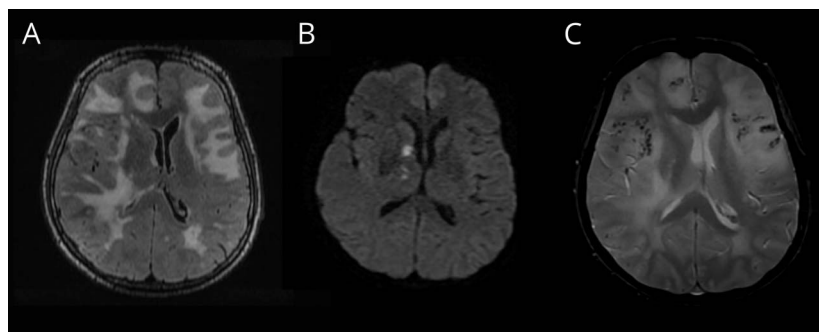
David Dongkyung Kim, MD, Teneille Gofton, MD, and G. Bryan Young, MD

Neurology® 2019;92:e2732-e2733. doi:10.1212/WNL.0000000000007612

Correspondence

Dr. Young
Bryan.young@lhsc.on.ca

Figure 1 Initial MRI



(A) T2-weighted confluent leukoencephalopathy extending to the subcortical white matter with mass effect. (B) Diffusion-weighted imaging 10 days later with associated changes on the apparent diffusion coefficient sequence (not pictured) was consistent with infarction. (C) Gradient echo sequence revealed microhemorrhages.

An obtunded previously healthy 60-year-old woman was intubated with a 2-week history of headaches and 1-month history of memory loss. MRI was performed (figure 1). Digital subtraction angiography of the head, varicella-zoster virus PCR, immunoglobulin G in the CSF, hepatitis B/C, CSF cryptococcal antigen, HIV, Lyme serology, and syphilis screen were negative. The initial differential diagnosis included CNS vasculitis and intracerebral lymphoma. She was diagnosed with inflammatory cerebral amyloid angiopathy based on clinoradiologic criteria (which has a sensitivity of 82% and specificity of 97%),¹ with infarction suggesting amyloid- β -related angiitis subtype. Within a few days of steroids, she was fully alert, and repeat MRI 5 months later showed improvement of leukoencephalopathy (figure 2). Montreal Cognitive Assessment scores were 23/30 2 weeks after initiation of therapy and 22/30 5 months later.

MORE ONLINE

→Teaching slides

links.lww.com/WNL/A895

Author contributions

D.D. Kim: study concept and design, preparation of manuscript. T. Gofton, G.B. Young: study concept and design, supervision of manuscript.

Study funding

No targeted funding reported.

Disclosure

The authors report no disclosures relevant to the manuscript. Go to Neurology.org/N for full disclosures.

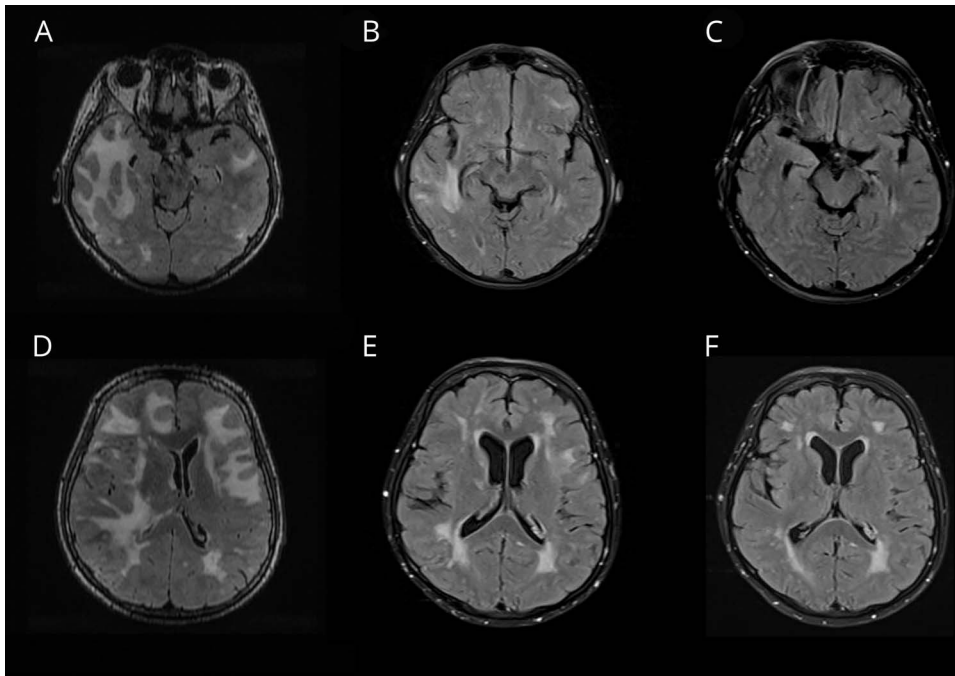
Reference

1. Auriel E, Charidimou A, Gurol ME, et al. Validation of clinoradiological criteria for the diagnosis of cerebral amyloid angiopathy-related inflammation. *JAMA Neurol* 2016;73:197–202.

From the Department of Clinical Neurological Sciences, Western University, London, Canada.

Go to Neurology.org/N for full disclosures.

Figure 2 Radiologic improvement after steroids



Comparison between initial imaging (A, D), around 3 weeks after initiation of steroid therapy (B, E), and after 5 months of corticosteroid therapy (C, F) showed improvement of leukoencephalopathy.

Neurology®

Teaching NeuroImages: Steroid-responsive leukoencephalopathy in inflammatory cerebral amyloid angiopathy

David Dongkyung Kim, Teneille Gofton and G. Bryan Young

Neurology 2019;92:e2732-e2733

DOI 10.1212/WNL.00000000000007612

This information is current as of June 3, 2019

Updated Information & Services	including high resolution figures, can be found at: http://n.neurology.org/content/92/23/e2732.full
References	This article cites 1 articles, 0 of which you can access for free at: http://n.neurology.org/content/92/23/e2732.full#ref-list-1
Subspecialty Collections	This article, along with others on similar topics, appears in the following collection(s): All Clinical Neurology http://n.neurology.org/cgi/collection/all_clinical_neurology All Cognitive Disorders/Dementia http://n.neurology.org/cgi/collection/all_cognitive_disorders_dementia MRI http://n.neurology.org/cgi/collection/mri
Permissions & Licensing	Information about reproducing this article in parts (figures, tables) or in its entirety can be found online at: http://www.neurology.org/about/about_the_journal#permissions
Reprints	Information about ordering reprints can be found online: http://n.neurology.org/subscribers/advertise

Neurology® is the official journal of the American Academy of Neurology. Published continuously since 1951, it is now a weekly with 48 issues per year. Copyright © 2019 American Academy of Neurology. All rights reserved. Print ISSN: 0028-3878. Online ISSN: 1526-632X.

