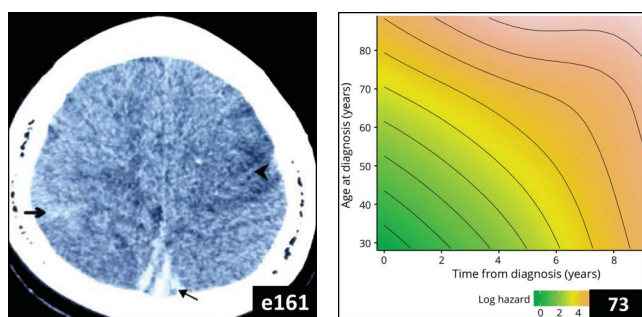
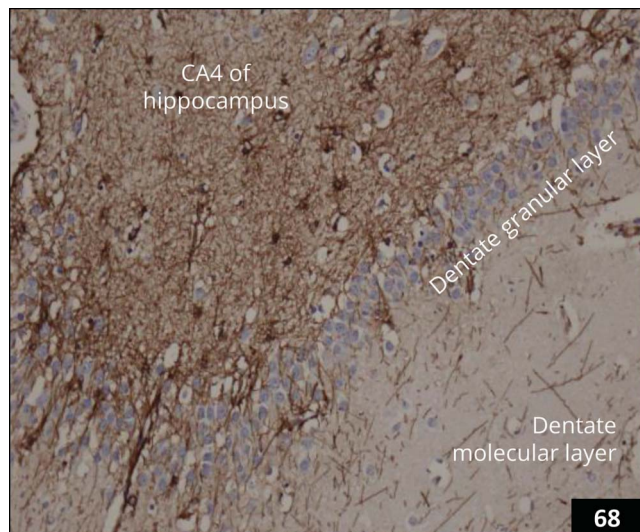
Select figures listed on the Table of Contents only appear within the full-length articles online.

In Focus

- 59 **Spotlight on the January 8 issue**
- 60 **This Week's *Neurology*® Podcast**

Editorials

- 61 **Cerebrotendinous xanthomatosis: The rare "treatable" disease you never consider**
G.V. Raymond and R. Schiffmann
- 63 **A synaptic protein defect associated with reflex seizure disorder**
P. Striano and P. Huppke
- 65 **ECG monitoring after acute ischemic stroke: Does patient selection matter?**
M. Katan and S.A. Lubitz

Articles: Short Format

Full articles at Neurology.org/N

- 67 **Long-term treatment effect in cerebrotendinous xanthomatosis depends on age at treatment start**
B.M.L. Stelten, H.H. Huidekoper, B.P.C. van de Warrenburg, E.H. Brilstra, C.E.M. Hollak, H.R. Haak, L.A.J. Kluijtmans, R.A. Wevers, and A. Verrips
🎧 CME Course ➔ Editorial, p. 61
- 68 **SYNGAP1 encephalopathy: A distinctive generalized developmental and epileptic encephalopathy**
D.R.M. Vlaskamp, B.J. Shaw, R. Burgess, D. Mei, M. Montomoli, H. Xie, C.T. Myers, M.F. Bennett, W. XiangWei, D. Williams, S.M. Maas, A.S. Brooks, G.M.S. Mancini, I.M.B.H. van de Laar, J.M. van Hagen, T.L. Ware, R.I. Webster, S. Malone, S.F. Berkovic, R.M. Kalnins, F. Sicca, G.C. Korenke, C.M.A. van Ravenswaaij-Arts, M.S. Hildebrand, H.C. Mefford, Y. Jiang, R. Guerrini, and I.E. Scheffer
➔ Editorial, p. 63 Open Access Article ➔ Video
- 69 **Spectrum and time course of epilepsy and the associated cognitive decline in MECP2 duplication syndrome**
D. Marafi, B. Suter, R. Schultz, D. Glaze, V.N. Pavlik, and A.M. Goldman
- 70 **Development and validation of a score to detect paroxysmal atrial fibrillation after stroke**
T. Uphaus, M. Weber-Krüger, M. Grond, G. Toenges, A. Jahn-Eimermacher, M. Jauss, P. Kirchhof, R. Wachter, and K. Gröschel
➔ Editorial, p. 65 🎧 Podcast ➔ Class of Evidence
- 71 **Brain networks' functional connectivity separates aphasic deficits in stroke**
A. Baldassarre, N.V. Metcalf, G.L. Shulman, and M. Corbetta
- 72 **Tau imaging detects distinctive distribution of tau pathology in ALS/PDC on the Kii Peninsula**
H. Shinotoh, H. Shimada, Y. Kokubo, K. Tagai, F. Niwa, S. Kitamura, H. Endo, M. Ono, Y. Kimura, S. Hirano, M. Mimuro, M. Ichise, N. Sahara, M.-R. Zhang, T. Suhara, and M. Higuchi
Open Access Article
- 73 **Age and time course of long-term motor and nonmotor complications in Parkinson disease**
S. Prange, T. Danaila, C. Laurencin, C. Caire, E. Metereau, H. Merle, E. Broussolle, D. Maucort-Boulch, and S. Thobois

What's Happening

- 74 **What's happening in *Neurology*® Clinical Practice**
- 75 **What's happening in Innovations in Care Delivery**

Contemporary Issues

- 76 **Neurology residency training in 2017: A survey of preparation, perspectives, and plans**
A. Mahajan, C. Cahill, E. Scharf, S. Gupta, S. Ahrens, E. Joe, and L. Schneider

➔ Ahead of Print Articles and Editorials

NPub.org/aheadofprint

Continued

Views & Reviews

84 Translating the biology of aging into novel therapeutics for Alzheimer disease

Y. Hara, N. McKeenan, and H.M. Fillit

[Open Access](#)

Clinical/Scientific Notes

94 Paroxysmal dyskinesias with drowsiness and thalamic lesions in GABA transaminase deficiency

H. Morales-Briceño, F.C.F. Chang, C. Wong, A. Mallawaarachchi, N. Wolfe, R. Pellegrino da Silva, H. Hakonarson, S.A. Sandaradura, Y. Guo, J. Christodoulou, J. Lagopoulos, P. Grattan-Smith, and V.S.C. Fung

[CME Course](#) [Video](#)

Reflections: Neurology and the Humanities

98 Patience

J.N. LaBuzetta

[Audio](#)

NeuroImages

99 Diagnosis and treatment evaluation of in-stent restenosis of carotid artery stenting using optical coherence tomography

R. Liu, Q. Yin, M. Li, R. Ye, W. Zhu, and X. Liu

Resident & Fellow Section

101 Pearls & Oysters: Challenging diagnosis of Gerstmann-Sträussler-Scheinker disease: Clinical and imaging findings

M.J. Kang, J. Suh, S.S. An, S.Y. Kim, and Y.H. Park

e161 Clinical Reasoning: A 14-year-old girl with headache, seizures, and confusion

L. Xiao, W. Gu, B. Jiao, Y. Liu, and X. Yang

e168 Teaching NeuroImages: Leigh-like features expand the picture of PMPCA-related disorders

A. Rubegni, R. Pasquariello, C. Dosi, G. Astrea, R. Canapicchi, F.M. Santorelli, and C. Nesti

e170 Teaching Video NeuroImages: A 20-year-old man with distal paresthesia

A. Stafford and C. Osman

[Video](#)

Global Perspectives

104 Barriers to diagnosis and management of CNS infections in Indonesia

D. Imran, S. Satiti, P. Sugianto, R. Estiasari, K. Maharani, D. Pangeran, P.W. Andini, B. Munir, A.H.P. Mawuntu, N.M. Susilawathi, K. Ritarwan, O.S. Hartanto, M. Frida, A.R. Ganiem, D. Gunawan, S. Dian, A.A.R. Sudewi, and R. van Crevel

Disputes & Debates: Editors' Choice

107 Editors' note: Teaching NeuroImages: DWI and EEG findings in Creutzfeldt-Jakob disease

A. Lewis and S. Galetta

107 Reader response: Teaching NeuroImages: DWI and EEG findings in Creutzfeldt-Jakob disease

J. Yuan and W. Hu

108 Author response: Teaching NeuroImages: DWI and EEG findings in Creutzfeldt-Jakob disease

A. Ganesh and M.M.C. Yeung

109 Editors' note: Practice guideline recommendations summary: Disease-modifying therapies for adults with multiple sclerosis: Report of the Guideline Development, Dissemination, and Implementation Subcommittee of the American Academy of Neurology

A. Lewis and S. Galetta

109 Reader response: Practice guideline recommendations summary: Disease-modifying therapies for adults with multiple sclerosis: Report of the Guideline Development, Dissemination, and Implementation Subcommittee of the American Academy of Neurology

L. Saltonstall

110 Author response: Practice guideline recommendations summary: Disease-modifying therapies for adults with multiple sclerosis: Report of the Guideline Development, Dissemination, and Implementation Subcommittee of the American Academy of Neurology

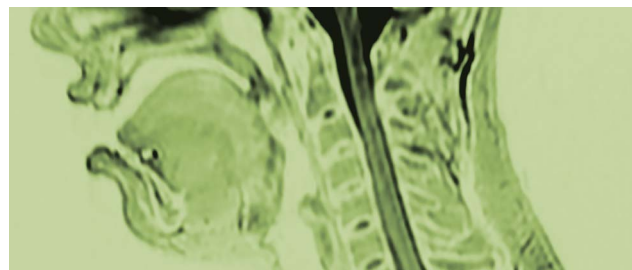
A. Rae-Grant

Correction

112 Practice guideline recommendations summary: Disease-modifying therapies for adults with multiple sclerosis: Report of the Guideline Development, Dissemination, and Implementation Subcommittee of the American Academy of Neurology

Department

In the Next Issue of *Neurology*[®]



[Cover image](#)

MRI sagittal T2 of a 20-year-old man with progressive distal paresthesia. Colorized by Cindy Abair, *Neurology* Senior Graphics Editor.

[See page e170](#)

Neurology®

92 (2)
Neurology 2019;92:e115-112

This information is current as of January 1, 2019

Updated Information & Services

including high resolution figures, can be found at:
<http://n.neurology.org/content/92/2.full>

Permissions & Licensing

Information about reproducing this article in parts (figures, tables) or in its entirety can be found online at:
http://www.neurology.org/about/about_the_journal#permissions

Reprints

Information about ordering reprints can be found online:
<http://n.neurology.org/subscribers/advertise>

Neurology® is the official journal of the American Academy of Neurology. Published continuously since 1951, it is now a weekly with 48 issues per year. Copyright . All rights reserved. Print ISSN: 0028-3878. Online ISSN: 1526-632X.

