



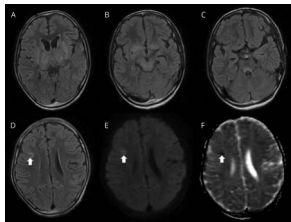
John J. Millichap, MD, FAAN, Editor
Roy E. Strowd III, MD, Deputy Editor



A summary of recently published articles in the *Neurology*[®] Resident & Fellow Section

 [facebook.com/AANResidentsAndFellows](https://www.facebook.com/AANResidentsAndFellows)

 [#NeurologyRF](https://twitter.com/NeurologyRF)



April 2, 2019 issue

This issue contains a Pearls & Oysters article of a case of toxic-metabolic encephalopathy due to bismuth toxicity from prolonged topical application. One Teaching NeuroImages case shows myoclonus as the presenting feature of Wilson disease and the second shows a rare case of Jacobsen syndrome. The Teaching Video NeuroImages case discusses myoclonus as

the presenting feature of Wilson disease.

Pearls & Oysters: Bismuth neurotoxicity from use of topical bismuth dressing for burns

We present a case of toxic-metabolic encephalopathy due to bismuth toxicity from prolonged topical application. It is important to recognize and consider this cause of altered mental status as it is reversible and potentially fatal.

Page e680

Teaching Video NeuroImages: Myoclonus as the presenting feature of Wilson disease

We report the case of a 10-year-old boy presenting with a 1-year history of repeated falls resulting from myoclonic jerks. The possibility of Wilson disease should be thought of in a child presenting with myoclonic jerks and appropriate workup should be carried out to avoid diagnostic delay.

Page e1667

Teaching NeuroImages: A rare case of Jacobsen syndrome with global diffuse hypomyelination of brain

An 8-month-old patient presented with developmental delay, diffuse hypotonia, hypoplastic left heart syndrome, undescended testes, neonatal thrombocytopenia, and unusual facies.

Page e1665

Teaching NeuroImages: In vivo visualization of Edinger comb and Wilson pencils

We revive 2 anatomical structures that were described by Edinger and Wilson about a century ago and that we were able to directly visualize using 7T MRI using a specialized cardiac-gated FLASH sequence.

Page e1663

MORE ONLINE

Editor's Blog

[NPub.org/rfblog](https://www.npub.org/rfblog)

Clinical Reasoning Book Free Download

[NPub.org/crb](https://www.npub.org/crb)

Global and Community Health Subsection

[NPub.org/gch](https://www.npub.org/gch)

Resident & Fellow e-Pearls

[NPub.org/epearls](https://www.npub.org/epearls)

April 9, 2019 issue

This issue starts with a Global & Community Health article on epilepsy in the Republic of Guinea. The issue also features 3 Teaching NeuroImages showing lacunar stroke and polyarteritis nodosa, lower cervical spine dural arteriovenous fistula presenting as subarachnoid hemorrhage, and the third discussing mucormycosis-associated vasculitis: a new sequence to show an old invasive infection.

Global & Community Health: The *djina* disease: On epilepsy in the Republic of Guinea

The article discusses the significance and effect of beliefs about epilepsy on patient care in the Republic of Guinea. Epilepsy in the Republic of Guinea remains relatively understudied, and this article describes critical factors that limit access to care for people with epilepsy throughout the country.

Page 725

Teaching NeuroImages: Lacunar stroke and polyarteritis nodosa: Consider ADA2 deficiency (DADA2)

A 14-year-old boy with a 7-year history of livedo reticularis and initial diagnosis of cutaneous polyarteritis nodosa presented with acute impaired taste and tactile sensation on the tongue.

Page e1801

Teaching NeuroImages: Lower cervical spine dural arteriovenous fistula presenting as subarachnoid hemorrhage

A 39-year-old man presented with sudden neck pain and headache. CT showed subarachnoid hemorrhage around medulla oblongata.

Page e1798

Teaching NeuroImages: Mucormycosis-associated vasculitis: A new sequence to show an old invasive infection

High-resolution vessel wall imaging with MRI has been shown to be an emergent technique in cases of vasculitis due to its ability to demonstrate enhancement in areas of inflammation. I propose to present the imaging features in a case of mucormycosis with this sequence.

Page e1796

April 16, 2019 issue

The first of 3 Teaching NeuroImages in this issue focuses on Waardenburg syndrome type 2. The second is about a diagnosis of aortoembolic stroke while the third describes a brainstem “kink” in a fetal MRI. The Right Brain article provides a perspective on our undiagnosed cases and the heavy yet fulfilling burden of the neurology resident.

Teaching NeuroImages: Waardenburg syndrome type 2

We present a 5-year-old patient admitted with bilateral congenital sensorineural hearing loss and iris pigmentary disturbance (vivid blue eyes) with no dystopia canthorum. Temporal bones images showed shortened and thick posterior semicircular canal. The final diagnosis was Waardenburg syndrome type 2.

Page e1935

Teaching NeuroImages: A disintegrating rock

We present a descriptive sequence of images that lead to the diagnosis of aortoembolic stroke in a patient who presented with recurrent confusion. This case may bring awareness about this uncommon but likely overlooked imaging of embolic stroke.

Page e1937

Teaching NeuroImages: The curious case of the brainstem kink

A 25-year-old woman presented for routine prenatal ultrasound that was concerning for severe hydrocephalus. Fetal MRI at 22 weeks showed a brainstem kink that suggested arrest or impairment in brain maturation around 7 weeks gestation, a sign of severe neurodysgenesis.

Page e1933

Right Brain: Silence

In this poem, a different perspective is given on our undiagnosed cases and the heavy yet fulfilling burden of the neurology resident.

Page 772

April 23, 2019 issue

A 71-year-old man receiving treatment for cryptococcal meningitis, developing new-onset lethargy, is described in the Clinical Reasoning article. The Teaching Video NeuroImage shows cautious walking gait in siblings with hereditary hyperekplexia. The first Teaching NeuroImages case discusses a clinical pitfall with congenital variant misdiagnosed as cerebral venous sinus thrombosis, and the second highlights a diagnostic clue in beaking in the brainstem.

Clinical Reasoning: A 71-year-old man receiving treatment for cryptococcal meningitis developing new-onset lethargy

In this clinical reasoning case, we describe a 71-year-old man with cryptococcal meningitis who developed sudden onset lethargy and was subsequently found to have bilateral thalamic strokes.

Page 815

Teaching Video NeuroImages: Cautious walking gait in siblings with hereditary hyperekplexia

A 48-year-old man and his 41-year-old sister complained of pathogenic startles since birth. They carried a homozygous deletion mutation in *GLRA1*: c.754delC (p. L252X).

Page e2068

Teaching NeuroImages: Congenital variant misdiagnosed as cerebral venous sinus thrombosis: Clinical pitfall

This case highlights clinical and radiographic signs of a common congenital variant that was misdiagnosed and led to complications.

Page e2064

Teaching NeuroImages: Beaking in the brainstem: A diagnostic clue

We submit a case of a 2-year-old boy, who presented with developmental regression, progressive stiffening of limbs, and strabismus since the age of 8 months. MRI brain was suggestive of claval hypertrophy, vertically oriented splenium of the corpus callosum, and cerebellar atrophy, and gave a clue to the diagnosis of INAD, which was confirmed by gene sequencing.

Page e2066

April 30, 2019 issue

This issue features the Mystery Case of a 23-year-old man with headaches, confusion, and lower extremity weakness. The Teaching Video NeuroImages highlights a case of Holmes tremor (or rubral tremor) in a patient with multiple sclerosis due to a lesion in the inferior cerebellar peduncle. The first Teaching NeuroImages case describes the wishbone pattern of iron accumulation, and the second highlights a case of idiopathic hypereosinophilic syndrome presenting as multiple multifocal infarcts.

Mystery Case: A 23-year old man with headaches, confusion, and lower extremity weakness

We present a case report of autoimmune glial fibrillary acidic protein astrocytopathy. We recently took care of a patient presenting with a meningoencephalomyelitis who was ultimately diagnosed with this condition. The case required a thoughtful differential diagnosis at several levels.

Page 863

Teaching Video NeuroImages: A patient with Holmes tremor due to demyelinating lesion of the inferior cerebellar peduncle

We present a case of Holmes tremor (or rubral tremor) in a patient with multiple sclerosis due to a lesion in the inferior cerebellar peduncle. A video of the tremor is included as is MRI showing the culprit lesion.

Page e2179

Teaching NeuroImages: Wishbone pattern of iron accumulation: A characteristic imaging sign in GM1 gangliosidosis

Through this article, we bring to attention a characteristic imaging pattern of iron deposition in late onset/type 3 GM1 gangliosidosis, which enables differentiation from neurodegeneration with brain iron accumulation. These disorders have a similar presentation of neuroregression in children, often leading to a diagnostic dilemma.

Page e2176

Teaching NeuroImages: Multifocal cerebral infarcts as a presentation of idiopathic hypereosinophilic syndrome

We report an original case of idiopathic hypereosinophilic syndrome presenting as multiple multifocal infarcts.

Page e2178

Now Accepting Applications for Women Leading in Neurology Program

Applications are now open for the prestigious Women Leading in Neurology Program, an empowering and inspirational leadership development opportunity designed to tackle gender disparities head-on and help women leaders advance to the top levels of leadership in their fields and within the American Academy of Neurology. The application deadline is June 17. Learn more and apply at AAN.com/view/WLN.

Neurology[®]

Resident & Fellow Rounds
John J. Millichap and Roy E. Strowd III
Neurology 2019;92;860-862
DOI 10.1212/WNL.0000000000007415

This information is current as of April 29, 2019

Updated Information & Services	including high resolution figures, can be found at: http://n.neurology.org/content/92/18/860.full
Permissions & Licensing	Information about reproducing this article in parts (figures, tables) or in its entirety can be found online at: http://www.neurology.org/about/about_the_journal#permissions
Reprints	Information about ordering reprints can be found online: http://n.neurology.org/subscribers/advertise

Neurology® is the official journal of the American Academy of Neurology. Published continuously since 1951, it is now a weekly with 48 issues per year. Copyright © 2019 American Academy of Neurology. All rights reserved. Print ISSN: 0028-3878. Online ISSN: 1526-632X.

