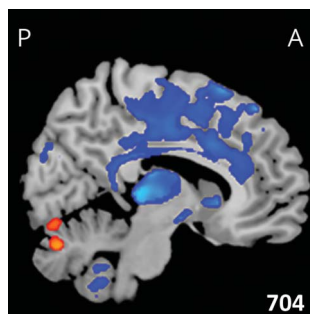
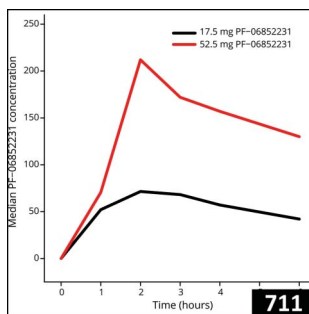
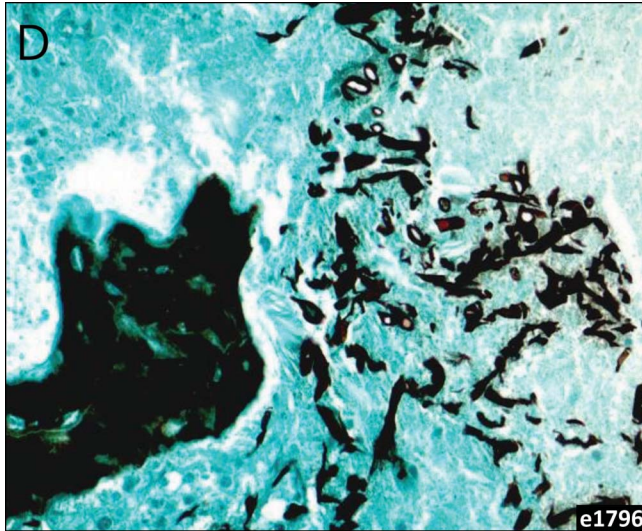Select figures listed on the Table of Contents only appear within the full-length articles online.

In Focus

- 685 **Spotlight on the April 9 issue**
- 686 **This Week's *Neurology*® Podcast**

Editorials

- 687 **White matter lesions in cerebral small vessel disease: Underperfusion or leaky vessels?**
A.H. Hainsworth
- 689 **Winners, losers, and controls**
J.M. Simard
- 691 **Measuring early lesion growth in boys with cerebral demyelinating adrenoleukodystrophy**
K. van Haren, M. Engelen, and N. Wolf

- 694 **Evolution of regional brain atrophy in children with multiple sclerosis: Gray matters**
E.A. Yeh and A. Eshaghi
- 696 **Dimethyl fumarate-induced changes in the MS lymphocyte repertoire: No need for subset monitoring**
J. Killestein and A.T. Reder
- 698 **Mind the gap: Quantifying gender representation as a first step to solve the problem?**
E. Waubant and W. Gilmore

Articles: Short Format

Full articles at Neurology.org/N

- 700 **Blood-brain barrier impairment and hypoperfusion are linked in cerebral small vessel disease**
S.M. Wong, J.F.A. Jansen, C.E. Zhang, E.I. Hoff, J. Staals, R.J. van Oostenbrugge, and W.H. Backes
📌 Editorial, p. 687
- 701 **Lower serum retinoic acid level for prediction of higher risk of mortality in ischemic stroke**
W.-J. Tu, H.-C. Qiu, Y. Zhang, J.-I. Cao, H. Wang, J.-Z. Zhao, Q. Liu, and X. Zeng
- 702 **Pooled analysis suggests benefit of catheter-based hematoma removal for intracerebral hemorrhage**
P. Mandava, S.B. Murthy, N. Shah, Y. Samson, M. Kimmel, and T.A. Kent
📌 CME Course 📌 Editorial, p. 689
- 703 **MRI brain lesions in asymptomatic boys with X-linked adrenoleukodystrophy**
A.P. Liberato, E.J. Mallack, R. Aziz-Bose, D. Hayden, A. Lauer, P.A. Caruso, P.L. Musolino, and F.S. Eichler
📌 Editorial, p. 691
- 704 **Dynamic gray matter volume changes in pediatric multiple sclerosis: A 3.5 year MRI study**
E. De Meo, A. Meani, L. Moiola, A. Ghezzi, P. Veggiotti, M. Filippi, and M.A. Rocca
📌 Editorial, p. 694
- 705 **Effect of dimethyl fumarate on lymphocytes in RRMS: Implications for clinical practice**
D. Mehta, C. Miller, D.L. Arnold, E. Bame, A. Bar-Or, R. Gold, J. Hanna, L. Kappos, S. Liu, A. Matta, J.T. Phillips, D. Robertson, C.A. von Hehn, J. Campbell, K. Spach, L. Yang, and R.J. Fox
📌 Editorial, p. 696 [Open Access Article](#)

➔ Ahead of Print Articles and Editorials

NPub.org/aheadofprint

Continued

- 706 **How much do periventricular lesions assist in distinguishing migraine with aura from CIS?**
C. Lapucci, L. Saitta, G. Bommarito, M.P. Sormani, M. Pardini, L. Bonzano, G.L. Mancardi, C. Gasperini, A. Giorgio, M. Inglese, N. De Stefano, and L. Roccatagliata
CME Course Podcast Class of Evidence
- 707 **Relative risk for Alzheimer disease based on complete family history**
L.A. Cannon-Albright, N.L. Foster, K. Schliep, J.M. Farnham, C.C. Teerlink, H. Kaddas, J. Tschanz, C. Corcoran, and J.S.K. Kauwe
Open Access Article
- 708 **Measurement of symptoms in idiopathic hypersomnia: The Idiopathic Hypersomnia Severity Scale**
Y. Dauvilliers, E. Evangelista, L. Barateau, R. Lopez, S. Chenini, C. Delbos, S. Beziat, and I. Jaussent
- 709 **Immune myopathy with large histiocyte-related myofiber necrosis**
A. Pestronk, N. Sinha, Z. Alhumayyd, C. Ly, R. Schmidt, and R. Bucelli
- 710 **Community exercise is feasible for neuromuscular diseases and can improve aerobic capacity**
A. Wallace, A. Pietrusz, E. Dewar, M. Dudzic, K. Jones, P. Hennis, A. Sterr, G. Baio, P.M. Machado, M. Laurá, I. Skorupinska, M. Skorupinska, K. Butcher, M. Trenell, M.M. Reilly, M.G. Hanna, and G.M. Ramdharry
Class of Evidence Open Access Article
- 711 **Photosensitive epilepsy: Robust clinical efficacy of a selective GABA potentiator**
R. Gurrell, D. Gorman, M. Whitlock, A. Ogden, D.S. Reynolds, B. DiVentura, B. Abou-Khalil, M. Gelfand, J. Pollard, R.E. Hogan, G. Krauss, M. Sperling, B. Vazquez, R.T. Wechsler, D. Friedman, R.P. Butt, and J. French
Class of Evidence

What's Happening

- 712 **What's happening in *Neurology*[®] *Clinical Practice***

Views & Reviews

- 713 **Visibility and representation of women in multiple sclerosis research**
A. Thomson, R. Horne, C. Chung, M. Marta, G. Giovannoni, J. Palace, and R. Dobson
Editorial, p. 698 Open Access

Reflections: Neurology and the Humanities

- 720 **The neurological exam**
P. Kwan
Audio

Video NeuroImages

- 723 **Vestibular paroxysmia presenting with irritative nystagmus**
A.S. Young, B. Jonker, and M.S. Welgampola
Video

Resident & Fellow Section

- 725 **Global & Community Health: The *djina* disease: On epilepsy in the Republic of Guinea**
P. Anand

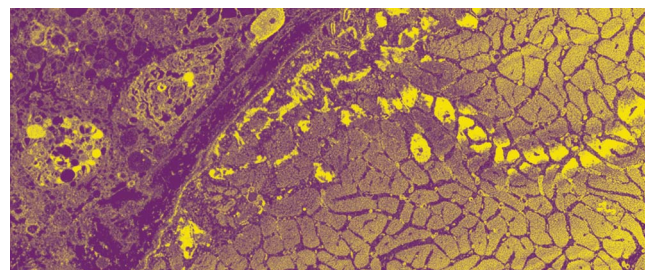
- e1796 **Teaching NeuroImages: Mucormycosis-associated vasculitis: A new sequence to show an old invasive infection**
L. de Moura Feitoza, A. Altemani, N. Adolfo da Silva, Jr., and F. Reis
- e1798 **Teaching NeuroImages: Lower cervical spine dural arteriovenous fistula presenting as subarachnoid hemorrhage**
P. Gao, S. Du, J. Ren, G. Li, and H. Zhang
- e1801 **Teaching NeuroImages: Lacunar stroke and polyarteritis nodosa: Consider ADA2 deficiency (DADA2)**
T.S. Gonçalves, C.A.P.F. Alves, J.A. da Paz, and L.T. Lucato

Disputes & Debates: Editors' Choice

- 728 **Editors' note: Association of orthostatic hypotension with incident dementia, stroke, and cognitive decline**
J.E. Siegler III and S. Galetta
- 728 **Reader response: Association of orthostatic hypotension with incident dementia, stroke, and cognitive decline**
T.M. Young
- 729 **Reader response: Association of orthostatic hypotension with incident dementia, stroke, and cognitive decline**
T. Kawada
- 730 **Author response: Association of orthostatic hypotension with incident dementia, stroke, and cognitive decline**
A.M. Rawlings and R.F. Gottesman
- 731 **Editors' note: Late-life blood pressure association with cerebrovascular and Alzheimer disease pathology**
J.E. Siegler III and S. Galetta
- 731 **Reader response: Late-life blood pressure association with cerebrovascular and Alzheimer disease pathology**
S. Lattanzi and M. Silvestrini
- 732 **Author response: Late-life blood pressure association with cerebrovascular and Alzheimer disease pathology**
Z. Arvanitakis and A.W. Capuano

Department

In the Next Issue of *Neurology*[®]



- Cover image
Focal, subsarcolemmal dissolution of myofibrils in a muscle fiber. Histiocytic cells are present in the neighboring endomysial connective tissue. Stylized by Kaitlyn Aman Ramm, *Neurology* Editorial Assistant.
See page 709

Neurology®

92 (15)

Neurology 2019;92:e1698-732

This information is current as of January 1, 2019

Updated Information & Services

including high resolution figures, can be found at:
<http://n.neurology.org/content/92/15.full>

Permissions & Licensing

Information about reproducing this article in parts (figures, tables) or in its entirety can be found online at:
http://www.neurology.org/about/about_the_journal#permissions

Reprints

Information about ordering reprints can be found online:
<http://n.neurology.org/subscribers/advertise>

Neurology® is the official journal of the American Academy of Neurology. Published continuously since 1951, it is now a weekly with 48 issues per year. Copyright . All rights reserved. Print ISSN: 0028-3878. Online ISSN: 1526-632X.

