



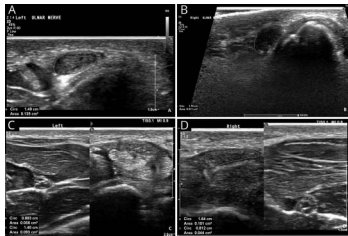
John J. Millichap, MD, FAAN, Editor  
Roy E. Strowd III, MD, Deputy Editor



## A summary of recently published articles in the *Neurology*<sup>®</sup> Resident & Fellow Section

 [facebook.com/AANResidentsAndFellows](https://www.facebook.com/AANResidentsAndFellows)

 [#NeurologyRF](https://twitter.com/NeurologyRF)



## March 5, 2019 issue

This issue contains 2 Clinical Reasoning articles. The first case is a hereditary neuropathy presenting in a teenage boy and the second involves a middle-aged man with a hereditary myopathy. One Teaching NeuroImages case shows a potential side effect from acupuncture and the second shows a notable feature of cerebral sparganosis on follow-up imaging.

### Clinical Reasoning: A 15-year-old boy with bilateral wrist pain in the setting of weight loss

This case features a stepwise diagnostic approach to hereditary neuropathy with liability to pressure palsy.

Page 486

### Clinical Reasoning: A 54-year-old man with dyspnea and muscle weakness

A patient with a rare hereditary myopathy is presented. The differential diagnoses and clinical pearls regarding this neuromuscular respiratory insufficiency are discussed.

Page e1136

### Teaching NeuroImages: CSF leakage observed from skin after acupuncture

A patient with an orthostatic headache was diagnosed with intracranial hypotension after receiving acupuncture repetitively a few weeks prior.

Page e1141

### Teaching NeuroImages: Migrating sparganum captured on brain MRI

Migration is a notable feature of cerebral sparganosis on follow-up MRI. A 16-year-old girl with cerebral sparganosis located in the brainstem is presented.

Page e1143

## March 12, 2019 issue

This issue starts with an Education Research article that studies the effect of a curriculum that teaches important nonmedical skills. The Teaching NeuroImages article shows an interesting stroke localization. Finally, the Teaching Video NeuroImages presents a case of a serious CNS infection in a teenager.

### MORE ONLINE

#### Editor's Blog

[NPub.org/rf/blog](https://www.npub.org/rf/blog)

#### Clinical Reasoning Book Free Download

[NPub.org/crb](https://www.npub.org/crb)

#### Global and Community Health Subsection

[NPub.org/gch](https://www.npub.org/gch)

#### Resident & Fellow e-Pearls

[NPub.org/epearls](https://www.npub.org/epearls)

## Education Research: Evaluation of curriculum to teach resilience skills to neurology residents

This pilot study demonstrated that resilience skills training is feasible and acceptable to neurology residents. Their knowledge, beliefs, and self-efficacy shifted in the desired direction, with several statistically significant improvements detected despite our small sample size.

Page 538

## Teaching Video NeuroImages: Stroke presenting with isolated toe-spreading palsy

A patient presented with sudden onset of a palsy isolated to the spreading of his right toes. This finding can help to clarify the topographic distribution of leg movements in the primary motor cortex.

Page e1268

## Teaching Video NeuroImages: An unusual case of fulminant subacute sclerosing panencephalitis

A 15-year-old girl had abnormal behavior of 3 weeks duration. There was frequent eye blinking (eyelid myoclonus) and periodic movements of right lower limb.

Page e1270

## March 19, 2019 issue

The first article in this issue is from the recently expanded Global & Community Health subsection and describes a clinical rotation in an African country. Next is a Clinical Reasoning case that describes a stepwise approach to localizing the cause of distal limb weakness. There are 2 Teaching NeuroImages. The first describes a case of a rare myopathy and neuropathy, and the second is the presentation of a malignant tumor in a young child with neurofibromatosis.

## Global & Community Health: A perspective on neurologic care at Mulago Hospital in Uganda

This article details the aspects of neurologic care in a resource-limited setting from the perspective of a US neurology resident completing an international elective rotation in Uganda.

Page 579

## Clinical Reasoning: A 58-year-old man with distal hand weakness

This is the case of a patient with distal weakness in the left hand due to a symptomatic meningoencephalocele of the right rolandic region. A focused nerve conduction study discovered a bilateral Martin-Gruber anastomosis that led to other investigations to explain his symptoms.

Page e1395

## Teaching NeuroImages: Intracranial malignant triton tumor: An uncommon location of a rare tumor

A 5-year-old girl with neurofibromatosis type I presented with a 1-month history of progressive left hemiparesis. Brain MRI revealed a large extra-axial right frontal mass.

Page e1401

## Teaching NeuroImages: Neuromyopathy in a patient with hereditary transthyretin

### Thr60Ala amyloidosis

This case highlights a rare cause of concomitant myopathy and neuropathy and importance of muscle and skin biopsy for this diagnosis.

Page e1403

## March 26, 2019 issue

In addition to international topics, the new Global & Community Health subsection also publishes submissions that discuss community health initiatives and volunteer experiences within the United States. The evaluation of a patient with the common presenting symptom of headache is described in the Clinical Reasoning article. The first Teaching NeuroImages case describes the presentation of hemorrhage, and the second highlights the ophthalmologic examination of a man with a lysosomal storage disease.

## Global & Community Health: Brief in-hospital cognitive screening anticipates complex admissions and may detect dementia

This utility of screening adults for cognitive impairment with the 6-item screener during an emergency department visit was studied. Despite the possibility that acute illness would limit its usefulness, this rapid assessment retained a surprising degree of sensitivity and specificity for previously documented cognitive impairment.

Page 631

## Clinical Reasoning: A teenager with persistent headache

Cerebral venous sinus thrombosis accounts for 0.5%–1% of all strokes. A patient with protein S deficiency and hyperhomocysteinemia presented with persistent headache.

Page e1526

## Teaching NeuroImages: Scleral thickening and optic disc edema from glycosaminoglycan deposition in Hunter syndrome

A 43-year-old man with a history of Hunter syndrome presented to the neuro-ophthalmology clinic with decreased peripheral vision.

Page e1532

## Teaching NeuroImages: Raccoon eye in subarachnoid hemorrhage

This image shows that subarachnoid hemorrhage is an important differential diagnosis of periorbital ecchymosis combined with sudden, severe headache.

Page e1534

# Neurology<sup>®</sup>

**Resident & Fellow Rounds**  
John J. Millichap and Roy E. Strowd III  
*Neurology* 2019;92;629-630  
DOI 10.1212/WNL.00000000000007196

**This information is current as of March 25, 2019**

**Updated Information & Services**

including high resolution figures, can be found at:  
<http://n.neurology.org/content/92/13/629.full>

**Permissions & Licensing**

Information about reproducing this article in parts (figures, tables) or in its entirety can be found online at:  
[http://www.neurology.org/about/about\\_the\\_journal#permissions](http://www.neurology.org/about/about_the_journal#permissions)

**Reprints**

Information about ordering reprints can be found online:  
<http://n.neurology.org/subscribers/advertise>

*Neurology*® is the official journal of the American Academy of Neurology. Published continuously since 1951, it is now a weekly with 48 issues per year. Copyright © 2019 American Academy of Neurology. All rights reserved. Print ISSN: 0028-3878. Online ISSN: 1526-632X.

