

Corneomandibular reflex in a patient with pontine hemorrhage without impaired consciousness

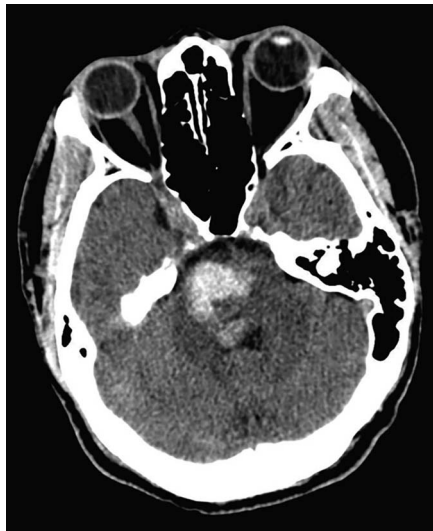
Marta Caballero-Ávila, MD, Eduard Juanola, MD, Artur Izquierdo, MD, Alejandro Martínez-Domeño, MD, and Joan Martí-Fàbregas, MD, PhD

Neurology® 2019;92:48-49. doi:10.1212/WNL.0000000000006701

Correspondence

Dr. Caballero-Ávila
mcaballero@santpau.cat

Figure CT scan shows a bilateral pontine hemorrhage, predominantly right



A 40-year-old man was admitted because of sudden loss of consciousness. CT scan showed a bilateral pontine hemorrhage, predominantly right (figure). Neurologic examination 19 days after onset showed ophthalmoplegia, anarthria, and tetraparesis. A prominent unilateral left corneomandibular reflex was observed and the patient was conscious and responsive to the examiner (video 1). This reflex consists of contralateral jaw deviation produced by corneal stimulation and has mostly been described in patients in coma.¹ It helps to distinguish structural from metabolic processes in comatose patients. We emphasize that this sign can also be elicited in alert patients with destructive brainstem damage.

MORE ONLINE

▶ Video

Study funding

No targeted funding reported.

Disclosure

The authors report no disclosures relevant to the manuscript. Go to Neurology.org/N for full disclosures.

From the Department of Neurology, Hospital de la Santa Creu i Sant Pau, Biomedical Research Institute Sant Pau, IIB Sant Pau Avda, Barcelona, Spain.

Go to Neurology.org/N for full disclosures. Funding information and disclosures deemed relevant by the authors, if any, are provided at the end of the article.

Appendix 1. Author contributions

Name	Contribution
Marta Caballero-Ávila	design and conceptualized study; analyzed the data; drafted the manuscript for intellectual content
Eduard Juanola	interpreted the data; revised the manuscript for intellectual content
Artur Izquierdo	interpreted the data; revised the manuscript for intellectual content
Alejandro Martínez-Domeño	interpreted the data; revised the manuscript for intellectual content
Joan Martí-Fàbregas	design and conceptualized study; analyzed the data; drafted the manuscript for intellectual content

Publication history

Received by *Neurology* August 6, 2018. Accepted in final form September 20, 2018.

Reference

1. Guberman A. Clinical significance of the corneomandibular reflex. *Arch Neurol* 1982; 39:578–580.

Disputes & Debates: Rapid online correspondence

The editors encourage comments on recent articles through Disputes & Debates:

Access an article at *Neurology.org/N* and click on “COMMENT” beneath the article header. Responses will be posted within 3 business days.


Before submitting a comment to Disputes & Debates, remember the following:

- Disputes & Debates is restricted to comments about studies published in *Neurology* within the last eight weeks
- Read previously posted comments; redundant comments will not be posted
- Your submission must be 200 words or less and have a maximum of five references; reference one must be the article on which you are commenting
- You can include a maximum of five authors (including yourself)

Visit the *Neurology*® Website at *Neurology.org/N*

- More article-based content on home pages
- Streamlined menus and navigation
- Enhanced blog sections for specialty areas
- Same experience on desktop, tablet, and mobile devices
- Audio summaries of current issues
- Improved article reading experience; links more evident (pdf, analytics, social media)
- *Neurology*® *Clinical Practice* initiative “Practice Current” global surveys will be accessible across sites

 Find *Neurology*® on Facebook: <http://tinyurl.com/neurologyfan>

 Follow *Neurology*® on Twitter: <https://twitter.com/GreenJournal>

Neurology[®]

Corneomandibular reflex in a patient with pontine hemorrhage without impaired consciousness

Marta Caballero-Ávila, Eduard Juanola, Artur Izquierdo, et al.

Neurology 2019;92;48-49

DOI 10.1212/WNL.0000000000006701

This information is current as of December 24, 2018

Updated Information & Services	including high resolution figures, can be found at: http://n.neurology.org/content/92/1/48.full
References	This article cites 1 articles, 0 of which you can access for free at: http://n.neurology.org/content/92/1/48.full#ref-list-1
Subspecialty Collections	This article, along with others on similar topics, appears in the following collection(s): All Cerebrovascular disease/Stroke http://n.neurology.org/cgi/collection/all_cerebrovascular_disease_stroke Clinical neurology examination http://n.neurology.org/cgi/collection/clinical_neurology_examination Coma http://n.neurology.org/cgi/collection/coma Intracerebral hemorrhage http://n.neurology.org/cgi/collection/intracerebral_hemorrhage
Permissions & Licensing	Information about reproducing this article in parts (figures, tables) or in its entirety can be found online at: http://www.neurology.org/about/about_the_journal#permissions
Reprints	Information about ordering reprints can be found online: http://n.neurology.org/subscribers/advertise

Neurology® is the official journal of the American Academy of Neurology. Published continuously since 1951, it is now a weekly with 48 issues per year. Copyright © 2018 American Academy of Neurology. All rights reserved. Print ISSN: 0028-3878. Online ISSN: 1526-632X.

