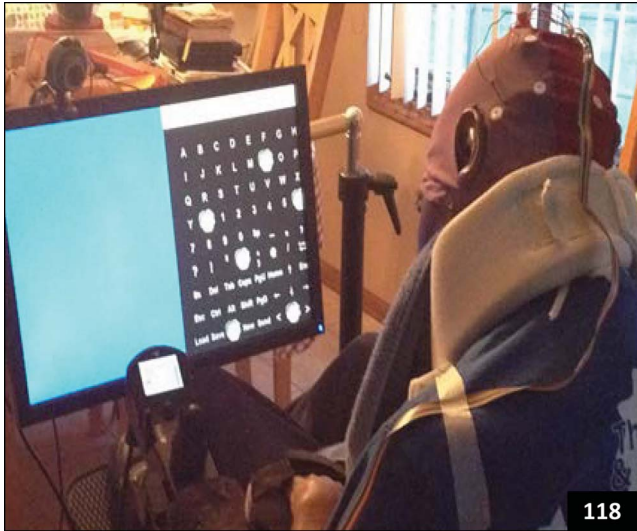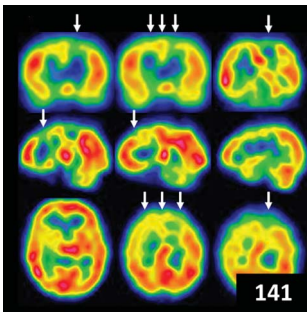


118

141

119

Select figures listed on the Table of Contents only appear within the full-length articles online.

In Focus

- 105 **Spotlight on the July 17 issue**
- 106 **This Week's *Neurology*® Podcast**

Editorials

- 107 **Don't ask, don't tell: Impulse control disorders in PD**
L.S. Boylan and V.S. Kostić
- 109 **A useful communication in brain-computer interfaces**
N. Birbaumer and L.R. Hochberg

Articles: Short Format

 Full articles at Neurology.org/N

- 111 **Longitudinal analysis of impulse control disorders in Parkinson disease**
J.-C. Corvol, F. Artaud, F. Cormier-Dequaire, O. Rascol, F. Durif, P. Derkinderen, A.-R. Marques, F. Bourdain, J.-P. Brandel, F. Pico, L. Lacomblez, C. Bonnet, C. Brefel-Courbon, F. Ory-Magne, D. Grabli, S. Klebe, G. Mangone, H. You, V. Mesnage, P.-C. Lee, A. Brice, M. Vidailhet, and A. Elbaz, For the DIGPD Study Group
 Editorial, p. 107 Podcast
- 112 **Evaluating depression and suicidality in tetrabenazine users with Huntington disease**
J.L. Schultz, A. Killoran, P.C. Nopoulos, C.C. Chabal, D.J. Moser, and J.A. Kamholz
 CME Course
- 113 **Outcome after seizure recurrence on antiepileptic drug withdrawal following temporal lobectomy**
C. Rathore, M.K. Jeyaraj, G.K. Dash, P. Wattamwar, N. Baheti, S.P. Sarma, and K. Radhakrishnan
- 114 **Increased CAIDE dementia risk, cognition, CSF biomarkers, and vascular burden in healthy adults**
M. Ecaz-Torres, A. Estanga, M. Tainta, A. Izagirre, M. Garcia-Sebastian, J. Villanua, M. Clerigue, A. Iriondo, I. Urreta, A. Arrospide, C. Díaz-Mardomingo, M. Kivipelto, and P. Martinez-Lage
- 115 **Alcohol intake and the risk of intracerebral hemorrhage in the elderly: The MUCH-Italy**
P. Costa, M. Grassi, L. Iacoviello, M. Zedde, S. Marcheselli, G. Silvestrelli, M.L. DeLodovici, M. Sessa, A. Zini, M. Paciaroni, C. Azzini, M. Gamba, M. Del Sette, A. Toriello, C. Gandolfo, D.M. Bonifati, R. Tassi, A. Cavallini, A. Chiti, R.S. Calabrò, F. Grillo, P. Bovi, G. Tomelleri, A. Di Castelnuovo, M. Ritelli, G. Agnelli, A. De Vito, N. Pugliese, G. Martini, C. Lodigiani, A. Morotti, L. Poli, V. De Giulii, F. Caria, C. Cornali, G. de Gaetano, M. Colombi, A. Padovani, and A. Pezzini, On behalf of the Multicenter Study on Cerebral Haemorrhage in Italy (MUCH-Italy) Investigators
- 116 **Effects of centralizing acute stroke services: A prospective cohort study**
S. Hastrup, S.P. Johnsen, T. Terkelsen, H.H. Hundborg, P. von Weitzel-Mudersbach, C.Z. Simonsen, N. Hjort, A.T. Møller, T. Harbo, M.S. Poulsen, N. Ruiz de Morales Ayudarte, D. Damgaard, and G. Andersen
 Open Access Article
- 117 **Three-Tesla MRI does not improve the diagnosis of multiple sclerosis: A multicenter study**
M.H.J. Hagens, J. Burggraaff, I.D. Kilsdonk, M.L. de Vos, N. Cawley, E. Sbardella, M. Andelova, M. Amann, J.M. Lieb, P. Pantano, B.I. Lissenberg-Witte, J. Killestein, C. Oreja-Guevara, O. Ciccarelli, C. Gasperini, C. Lukas, M.P. Wattjes, and F. Barkhof, For the MAGNIMS Study Group
 CME Course Open Access Article

Ahead of Print Articles and Editorials

NPub.org/aheadofprint
Continued

118 **Independent home use of a brain-computer interface by people with amyotrophic lateral sclerosis**

J.R. Wolpaw, R.S. Bedlack, D.J. Reda, R.J. Ringer, P.G. Banks, T.M. Vaughan, S.M. Heckman, L.M. McCane, C.S. Carmack, S. Winden, D.J. McFarland, E.W. Sellers, H. Shi, T. Paine, D.S. Higgins, A.C. Lo, H.S. Patwa, K.J. Hill, G.D. Huang, and R.L. Ruff

🔗 Editorial, p. 109

119 **Diffuse Lewy body disease manifesting as corticobasal syndrome: A rare form of Lewy body disease**

K. Kasanuki, K.A. Josephs, and T.J. Ferman

120 **Gray matter volume modifications in migraine: A cross-sectional and longitudinal study**

R. Messina, M.A. Rocca, B. Colombo, E. Pagani, A. Falini, P.J. Goadsby, and M. Filippi

What's Happening

121 **What's happening in *Neurology*[®]**

122 **What's happening in *Neurology*[®] *Clinical Practice***

123 **What's happening in *Neurology*[®] *Genetics***

124 **What's happening in *Neurology*[®] *Neuroimmunology & Neuroinflammation***

Clinical Implications of Neuroscience Research

125 **Glutamatergic synaptic plasticity and dysfunction in Alzheimer disease: Emerging mechanisms**

E.E. Benarroch

Views & Reviews

133 **Critical appraisal of the recent US FDA approval for earlier DBS intervention**

L.Y. Cabrera, J. Goudreau, and C. Sidiropoulos

Clinical/Scientific Notes

137 **Ocular phenotype and electroretinogram abnormalities in Lafora disease: A “window to the brain”**

A. Vincent, A. Macri, A. Tumber, N. Koukas, S. Ahonen, P. Striano, and B. Minassian

Reflections: Neurology and the Humanities

140 **Percussion**

C.M. LaVigne

🔊 Audio

Video NeuroImages

141 **Gelastic attack in a child with moyamoya disease**

H. Suzuki, T. Mikami, R. Enatsu, A. Kanno, Y. Takahashi, and N. Mikuni

📺 Video

Resident & Fellow Section

143 **Child Neurology: Siblings with infantile epilepsy and developmental delay: A circuitous path to genomic diagnosis**

Y. Liu, D. Michelson, R. Clark, and J.-A. Gold

e293 **Teaching NeuroImages: Isolated pontine involvement in subacute sclerosing panencephalitis**

N. Kumar, A. Ranjan, A. Kumar, and B. Kumar

e295 **Teaching NeuroImages: Spinal cord syrinx secondary to a spinal dural arteriovenous fistula**

I. Zaed, M.V. Pinto, M.L. Mauermann, and G. Lanzino

e297 **Teaching Video NeuroImages: Propriospinal myoclonus as a sequela of Guillain-Barré syndrome**

J.R. Bedarf, M. Nelles, J. Reimann, S. Paus, and J. Zimmermann

📺 Video

Disputes & Debates: Editors' Choice

148 **Editors' note: Blood pressure from mid- to late life and risk of incident dementia**

C. Karam and S. Galetta

148 **Reader response: Blood pressure from mid- to late life and risk of incident dementia**

S. Lattanzi and M. Silvestrini

149 **Reader response: Blood pressure from mid- to late life and risk of incident dementia**

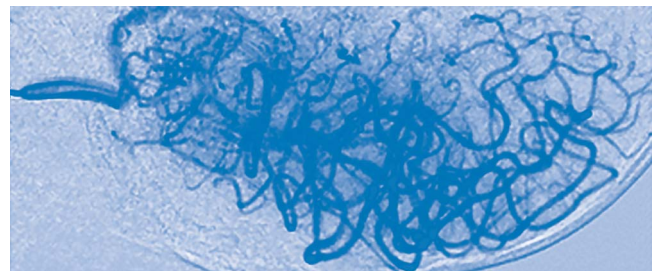
A. Ganesh

149 **Author response: Blood pressure from mid- to late life and risk of incident dementia**

E.R. McGrath and S. Seshadri

Department

In the Next Issue of *Neurology*[®]



📺 **Cover image**

Preoperative MR image shows steno-occlusive changes at the terminal portion of the bilateral internal carotid artery and moyamoya vessels in a child. Colorized by Cindy Abair, *Neurology* Senior Graphics Editor.

See page 141

Neurology[®]

91 (3)

Neurology 2018;91:e295-149

This information is current as of January 1, 2018

Updated Information & Services

including high resolution figures, can be found at:
<http://n.neurology.org/content/91/3.full>

Permissions & Licensing

Information about reproducing this article in parts (figures, tables) or in its entirety can be found online at:
http://www.neurology.org/about/about_the_journal#permissions

Reprints

Information about ordering reprints can be found online:
<http://n.neurology.org/subscribers/advertise>

Neurology® is the official journal of the American Academy of Neurology. Published continuously since 1951, it is now a weekly with 48 issues per year. Copyright . All rights reserved. Print ISSN: 0028-3878. Online ISSN: 1526-632X.

