

Robert A. Gross, MD, PhD, FAAN, Editor-in-Chief, *Neurology*[®]



Notable in *Neurology* this week

This issue features an article that investigates the relationship between middle cerebral artery geometric features and plaque distribution on ischemic stroke occurrence; another characterizes newer disease-modifying therapies for use in pediatric multiple sclerosis. A featured Views & Reviews article assesses the relevance of quantitative EEG as an outcome measure in Parkinson disease.

Articles

Atrial fibrillation, antithrombotic treatment, and cognitive aging: A population-based study

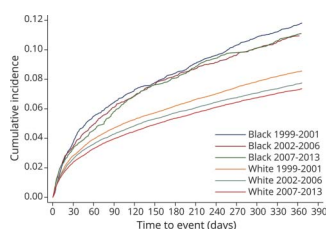
In this population-based cohort study of people aged ≥ 60 years, atrial fibrillation (AF) was associated with faster cognitive decline and a higher risk of dementia. Among participants with AF, use of anticoagulants was associated with a lower risk of dementia, suggesting potential cognitive benefits of anticoagulant therapy in patients with AF.

Page 859

From editorialists Sposato & Chen: "This study both confirms previous findings suggesting an additive effect of AF-related cerebrovascular disease and degenerative changes, and highlights the essential role of underlying degenerative pathology."

Page 857

Racial differences in recurrent ischemic stroke risk and recurrent stroke case fatality



Among older Americans who experienced ischemic stroke, older black patients have a lower risk of death, but a higher risk of recurrent stroke. In this study, the incidence of recurrent stroke declined from 1999 to 2013, but black patients remained at greater risk. Further efforts are needed to eliminate racial disparity and improve outcomes.

Page 860

Risk factors of hippocampal sclerosis in the oldest old: The 90+ Study

Hippocampal sclerosis of aging (HS) is a common but underrecognized cause of dementia in the oldest old. In this study, patients with dementia and a pathologic diagnosis of HS were more likely to have had thyroid disease and rheumatoid arthritis. HS-caused dementia in the oldest old may have modifiable risk factors.

Page 865

MORE ONLINE

🎧 Editor's Summary

Audio summary of highlighted articles.

NPub.org/edsum

Continued

Regional amyloid accumulation and cognitive decline in initially amyloid-negative adults

Subtle amyloid-related cognitive decline may start far in advance of clinical symptoms, when PET scans are amyloid-negative. In initially amyloid-negative adults, regional increases in posterior cortical amyloid over 4 years were associated with concurrent memory decline. A focus on the posterior neocortex can aid in the early detection of amyloid-related decline.

Page 867

NB: "Neuronal intranuclear inclusion disease showing intranuclear inclusions in renal biopsy 12 years earlier," p. 884. To check out other Clinical/Scientific Notes, point your browser to Neurology.org/N. At the end of the issue, check out the Resident & Fellow Clinical Reasoning article exploring the diagnosis of a patient presenting with headache and right leg jerks. This week also includes a NeuroImage titled "Intrasellar herniation: A newly described variant of downward central herniation."

NEW EPISODE



November 6, 2018

CME Opportunity:

Listen to this week's *Neurology* Podcast and earn 0.5 AMA PRA Category 1 CME Credits™ by answering the multiple-choice questions in the online Podcast quiz.

Use of newer disease-modifying therapies in pediatric multiple sclerosis in the US (see p. 864)

1. Featured Article: Use of newer disease-modifying therapies in pediatric multiple sclerosis in the US
2. What's Trending: Acute flaccid myelitis

In the first segment, Dr. Nick Brenton talks with Dr. Kristen Krysko about her paper on therapies for pediatric multiple sclerosis. In the second part of the podcast, Dr. Stacey Clardy focuses her interview with Dr. Kenneth Tyler on acute flaccid myelitis.

Disclosures can be found at Neurology.org.

Neurology®

Spotlight on the November 6 issue

Robert A. Gross

Neurology 2018;91;853-854

DOI 10.1212/WNL.0000000000006481

This information is current as of November 5, 2018

Updated Information & Services

including high resolution figures, can be found at:
<http://n.neurology.org/content/91/19/853.full>

Permissions & Licensing

Information about reproducing this article in parts (figures, tables) or in its entirety can be found online at:
http://www.neurology.org/about/about_the_journal#permissions

Reprints

Information about ordering reprints can be found online:
<http://n.neurology.org/subscribers/advertise>

Neurology® is the official journal of the American Academy of Neurology. Published continuously since 1951, it is now a weekly with 48 issues per year. Copyright © 2018 American Academy of Neurology. All rights reserved. Print ISSN: 0028-3878. Online ISSN: 1526-632X.

