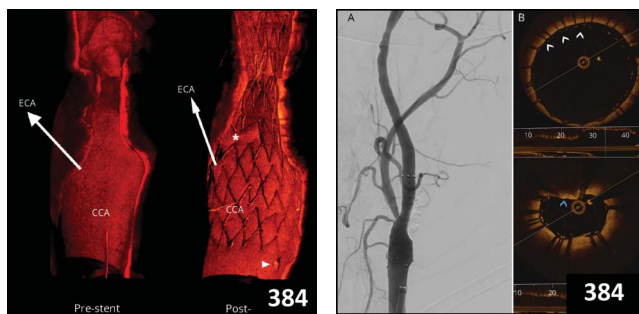
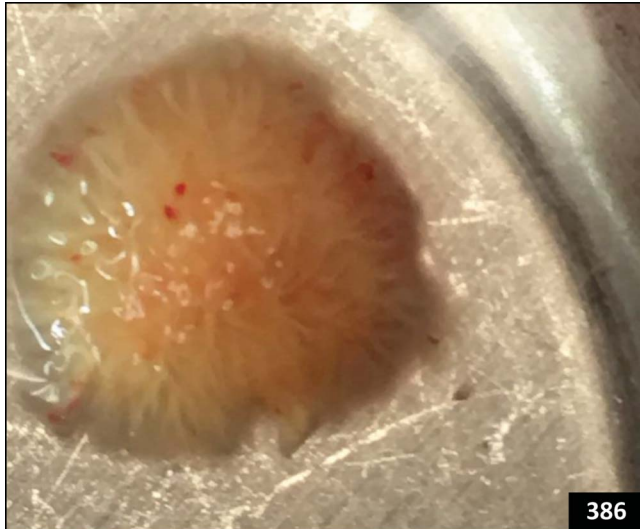
Articles: Short Format

 Full articles at Neurology.org/N

353 Spatial variation in high-frequency oscillation rates and amplitudes in intracranial EEG

H. Guragain, J. Cimbalknik, M. Stead, D.M. Groppe, B.M. Berry, V. Kremen, D. Kenney-Jung, J. Britton, G.A. Worrell, and B.H. Brinkmann

[Editorial, p. 347](#)

354 Electrophysiologic testing aids diagnosis and subtyping of myoclonus

R. Zutt, J.W. Elting, J.C. van Zijl, J.H. der Hoeven, C.M. Roosendaal, J.M. Gelauff, K.J. Peall, and M.A.J. Tijssen

[Open Access Article](#)

355 Teenage-onset progressive myoclonic epilepsy due to a familial *C9orf72* repeat expansion

J. van den Ameele, I. Jedlickova, A. Pristoupilova, A. Sieben, S. Van Mossevelde, C.C. Groote, H. Hůlková, R. Matej, A. Meurs, C. Van Broeckhoven, S.F. Berkovic, P. Santens, S. Kmoch, and B. Dermaut

[CME Course](#)

356 Adjunct zonisamide to levodopa for DLB parkinsonism: A randomized double-blind phase 2 study

M. Murata, T. Odawara, K. Hasegawa, S. Iiyama, M. Nakamura, M. Tagawa, and K. Kosaka

[CME Course](#) [Editorial, p. 349](#) [Open Access Article](#)
[Class of Evidence](#)

357 The effect of white matter hyperintensities on verbal memory: Meditation by temporal lobe atrophy

W. Swardfager, H. Cogo-Moreira, M. Masellis, J. Ramirez, N. Herrmann, J.D. Edwards, M. Saleem, P. Chan, D. Yu, S.M. Nestor, C.J.M. Scott, M.F. Holmes, D.J. Sahlas, A. Kiss, P.I. Oh, S.C. Strother, F. Gao, B. Stefanovic, J. Keith, S. Symons, R.H. Swartz, K.L. Lancôt, D.T. Stuss, and S.E. Black

358 Early time course of major bleeding on antiplatelet therapy after TIA or ischemic stroke

N.A. Hilken, A. Algra, L.J. Kappelle, P.M. Bath, L. Csiba, P.M. Rothwell, and J.P. Greving, On behalf of the CAT Collaboration

[Open Access Article](#)

359 Intravenous thrombolysis and platelet count

H. Gensicke, A.S. Al Sultan, D. Strbian, C. Hametner, S.M. Zinkstok, S. Moulin, O. Bill, A. Zini, V. Padjen, G. Kägi, A. Pezzini, D.J. Seiffge, C. Traenka, S. Rätty, H. Amiri, T.P. Zonneveld, R. Lachenmeier, A. Polymeris, Y.B. Roos, C. Gumbinger, D.R. Jovanovic, S. Curtze, G. Sibolt, L. Vandelli, P.A. Ringleb, D. Leys, C. Cordonnier, P. Michel, P.A. Lyrer, N. Peters, T. Tatlisumak, P.J. Nederkoorn, and S.T. Engelter, for the Thrombolysis in Stroke Patients (TRISP) collaborators

[Podcast](#)

In Focus

 345 **Spotlight on the February 20 issue**

 346 **This Week's *Neurology*® Podcast**

Editorials

 347 **Searching for the good and bad high-frequency oscillations**

F. Cendes and K.J. Meador

 349 **Zonisamide for DLB parkinsonism: An old drug used in a new context**

L.A. Hershey and D.J. Irwin

 351 **Posthemorrhagic perils of prematurity**

G.J. Myers and F.M. Cowan

[Ahead of Print Articles and Editorials](#)

NPub.org/aheadofprint
Continued

360 **Posthemorrhagic ventricular dilatation in preterm infants: When best to intervene?**

L.M. Leijser, S.P. Miller, G. van Wezel-Meijler, A.J. Brouwer, J. Traubici, I.C. van Haastert, H.E. Whyte, F. Groenendaal, A.V. Kulkarni, K.S. Han, P.A. Woerdeman, P.T. Church, E.N. Kelly, H.L.M. van Straaten, L.G. Ly, and L.S. de Vries

↻ Editorial, p. 351 ↻ Class of Evidence

361 **Unraveling ALS due to *SOD1* mutation through the combination of brain and cervical cord MRI**

F. Agosta, E.G. Spinelli, I.V. Marjanovic, Z. Stevic, E. Pagani, P. Valsasina, B. Salak-Djokic, M. Jankovic, D. Lavrnic, V.S. Kostic, and M. Filippi

362 **Neurofilament light protein in blood predicts regional atrophy in Huntington disease**

E.B. Johnson, L.M. Byrne, S. Gregory, F.B. Rodrigues, K. Blennow, A. Durr, B.R. Leavitt, R.A. Roos, H. Zetterberg, S.J. Tabrizi, R.I. Scahill, and E.J. Wild, for the TRACK-HD Study Group

Open Access Article

What's Happening

363 **What's happening in *Neurology*[®]**

364 **What's happening in *Neurology*[®] Clinical Practice**

365 **What's happening in *Neurology*[®] Genetics**

366 **What's happening in *Neurology*[®] Neuroimmunology & Neuroinflammation**

Clinical Implications of Neuroscience Research

367 **DNA damage response: Selected review and neurologic implications**

E.A. Coon and E.E. Benarroch

Clinical/Scientific Notes

377 **A genotype–phenotype correlation for quantitative autistic trait burden in neurofibromatosis 1**

S.M. Morris and D.H. Gutmann

380 **Comment: Genotype–phenotype correlations in NF1: A case for routine genetic testing**

C.J. Campen and R.S. Greenwood

Reflections: Neurology and the Humanities

381 **Morning rounds; Drilling for blood; Falx; Sciatica**

T. Mampalam

↻ Audio

NeuroImages

384 **Carotid artery stenting with optical coherence tomography**

N.M. Alotaibi, F. Sarzetto, J. Ramjist, and V.X.D. Yang

Resident & Fellow Section

386 **Clinical Reasoning: An unusual cause of adult cryptogenic ischemic stroke**

M.L. Leekoff, J.E. Masur, A.P. Burke, J.S. Pollock, M.N. Peters, S.M. Pham, T.R. Miller, and J.W. Cole

e724 **Journal Club: MRI reveals acute inflammation in cortical lesions during early MS**

E.M. Bateman, W.E. Schleicher, E.J. Smith, D.R. Sweet, and A.D. Gaudet

e727 **Pearls & Oysters: Delayed progression of isolated cortical vein thrombosis despite therapeutic INR**

P. Gadiant, D. Archer, and N. Asdaghi

e731 **Teaching Video NeuroImages: Heimann-Bielschowsky phenomenon: A harmless monocular nystagmus**

A. Nguyen and F.-X. Borruat

↻ Video

Disputes & Debates: Editors' Choice

392 **Editors' note: Upgoing thumb sign: A sensitive indicator of brain involvement?**

M. Alcauskas and S. Galetta

392 **Reader response: Upgoing thumb sign: A sensitive indicator of brain involvement?**

G. Rosenberg

393 **Reader response: Upgoing thumb sign: A sensitive indicator of brain involvement?**

J.-C. Baron

393 **Reader response: Upgoing thumb sign: A sensitive indicator of brain involvement?**

J.F. Meilof

394 **Author response: Upgoing thumb sign: A sensitive indicator of brain involvement?**

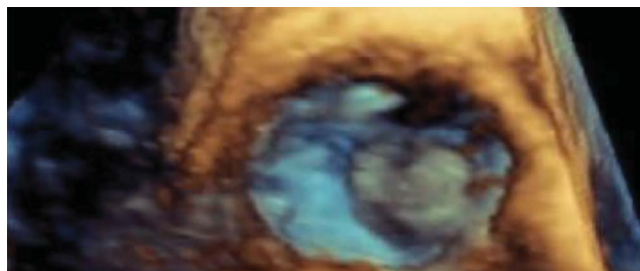
V. Hachinski, R. Alsubaie, and M.R. Azarpazhooh

Correction

396 **Upgoing thumb sign: A sensitive indicator of brain involvement**

Department

In the Next Issue of *Neurology*[®]



↻ Cover image

3D transesophageal echocardiography depicting an unusual cause of adult cryptogenic ischemic stroke.

See page 386

Neurology®

90 (8)

Neurology 2018;90:e731-396

This information is current as of January 1, 2018

Updated Information & Services

including high resolution figures, can be found at:
<http://n.neurology.org/content/90/8.full>

Permissions & Licensing

Information about reproducing this article in parts (figures, tables) or in its entirety can be found online at:
http://www.neurology.org/about/about_the_journal#permissions

Reprints

Information about ordering reprints can be found online:
<http://n.neurology.org/subscribers/advertise>

Neurology® is the official journal of the American Academy of Neurology. Published continuously since 1951, it is now a weekly with 48 issues per year. Copyright . All rights reserved. Print ISSN: 0028-3878. Online ISSN: 1526-632X.

