

Pearls & Oysters: Positional vertigo and vertical nystagmus in medulloblastoma

A picture is worth a thousand words

Martin Kronenbuerger, MD, Alessandro Olivi, MD, and David S. Zee, MD

Neurology® 2018;90:e352-e354. doi:10.1212/WNL.0000000000004866

Correspondence

Dr. Kronenbuerger
martin_kronenbuerger@
hotmail.com

Pearls

- Eye movement abnormalities can be helpful with topical localization.
- Vertical nystagmus (downbeat and upbeat nystagmus) is typically caused by posterior fossa lesions. Other causes include medication side effects, vitamin deficiencies, inflammatory and autoimmune/paraneoplastic conditions, and hereditary and degenerative cerebellar ataxias.
- Lesions in the posterior fossa such as medulloblastoma may also present with positional vertigo, with similar characteristics to benign paroxysmal positional vertigo.
- MRI of the brain with contrast is the imaging of choice in the workup of ataxia and vertical nystagmus.

Oysters

- Warning signs for more ominous causes of positional vertigo are presentation at a young age, sustained nystagmus, lack of remission or lack of response to therapeutic positioning maneuvers, and presence of other neurologic deficits.
- Using a clear understanding of the topical localization of the particular patterns of abnormalities of eye movements, a focused assessment of brain imaging often reveals pathology.
- Always assess the actual images, not just the reports.

Case presentation

At age 23, a woman began to fall unexpectedly. She also had episodes of diffuse pressure headache, dizziness, and double and blurred vision. When she was lying down flat, she consistently had a spinning sensation lasting 15–30 seconds. She sensed her eyes were jittering. She also felt off-balance.

A neurologic examination was normal except for a sudden onset, intense, but fatigable torsional nystagmus for 20 seconds when the patient was moved into a left Dix-Hallpike position. MRI without contrast of brain at age 24 was reported to be normal. Benign paroxysmal positional vertigo (BPPV) was suspected, but rehabilitation with repositioning maneuvers did not help.

At age 25, the patient noticed that she had difficulty walking straight. On clinical neurologic examination, she showed an intermittent downbeat nystagmus with lateral gaze, impaired smooth pursuit in the horizontal plane, saccades overshoot the target, and truncal ataxia. When her head hung down to the right, she had transient downbeat nystagmus along with subjective dizziness. Another MRI without contrast of her brain was reported as normal. Entities such as structural lesions of the midline cerebellum and Chiari malformation were considered but excluded on the assumption that the MRIs of her brain were normal. At that time, an inherited ataxia syndrome affecting her midline cerebellum and corticospinal tracts was considered as the most likely diagnosis. There were no family members with a similar condition or impaired eye movements. The patient's past workup was within normal limits, including general laboratory

MORE ONLINE

Video

links.lww.com/WNL/A77

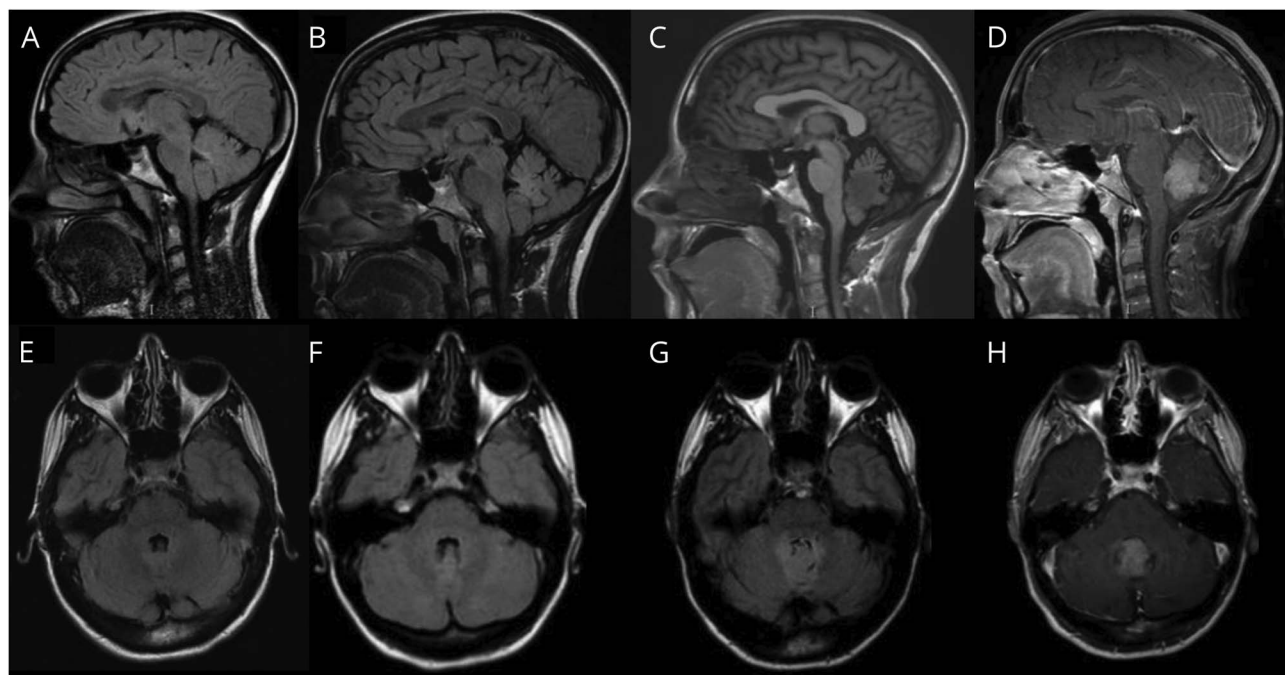
links.lww.com/WNL/A78

links.lww.com/WNL/A79

From the Department of Neurology (M.K., D.S.Z.) and School of Medicine, Department of Neurosurgery (A.O.), The Johns Hopkins University, Baltimore, MD; Department of Neurology (M.K.), University Medicine Greifswald, Germany; and Department of Neurosurgery (A.O.), Policlinico Universitario A. Gemelli, Rome, Italy.

Go to Neurology.org/N for full disclosures. Funding information and disclosures deemed relevant by the authors, if any, are provided at the end of the article.

Figure 1 MRI of the brain



(A, E) MRIs at age 24, (B, F) MRIs at age 25, (C, G) MRIs at age 29 without contrast, (D, H) MRIs at age 29 with contrast. Upper row (A–D) shows sagittal and lower row (E–H) shows axial slices of the MRIs.

tests (complete blood count, thyroid-stimulating hormone, liver and kidney function tests, iron metabolites), cardiovascular assessment (Holter ECG, tilt table, carotid Doppler ultrasound), ear, nose, and throat and gynecologic consultations, audiogram, and vestibular function with caloric and rotational testing.

We first evaluated the patient at age 29. On clinical examination, she had sustained horizontal nystagmus on lateral gaze and impaired smooth pursuit in all directions with catch-up saccades. There were small, hypometric corrective saccades in the horizontal plane with the head impulse test. Suppression of the vestibulo-ocular reflex was severely impaired in both horizontal directions. With her head tilted back, she immediately developed a nonfatiguing downbeat nystagmus. She also had dysarthria, moderate dysmetria of her arm movements, a small-amplitude kinetic and goal-directed tremor of her arms, dysmetria on heel-shin testing of both legs, and an ataxic gait. She had severe difficulty with tandem walk with many missteps and there was increased sway of her upper body. The muscle tone was slightly increased in the arms and moderately increased in the legs. Deep tendon reflexes were brisk at the legs. Two weeks after the initial presentation, an upbeat nystagmus was noted on straight-ahead gaze. See videos 1–3 ([lww.com/WNL/A77](http://www.com/WNL/A77), [lww.com/WNL/A78](http://www.com/WNL/A78), links.lww.com/WNL/A79) of the patient's eye movements.

An MRI with contrast of the patient's brain now showed a contrast-enhancing mass in the posterior fourth ventricle near the cerebellar nodulus and uvula (figure 1, A–H). The

lesion was resected followed by radiation and chemotherapy. Histopathology revealed a medulloblastoma. In the follow-up period, her symptoms slightly improved but she also developed palatal tremor. The prominent findings on her eye movement examination after surgery were saccade hypermetria and a skew deviation.

Discussion

As in this case, vertical nystagmus usually points to a lesion in structures near the inferior portion of the fourth ventricle including the inferior cerebellum (flocculus, paraflocculus [tonsil], nodulus, and uvula) and medulla.¹ Other causes include side effects of medications, vitamin deficiencies, inflammatory and autoimmune/paraneoplastic conditions, and hereditary and degenerative cerebellar ataxias.^{2–4} Other eye movement abnormalities that have localizing value with respect to the cerebellum are depicted in figure 2.

Our patient initially presented with symptoms that can be seen in BPPV, including being off-balance.¹ In the follow-up period, however, she developed warning signs of positional vertigo and nystagmus of a more sinister origin including presentation at a young age, no response to treatment with repositioning maneuvers, sustained positional vertical nystagmus, and other ocular motor abnormalities.¹ In these patients, an MRI of the brain with contrast is essential.

Medulloblastoma is one of the most common brain neoplasms in children, accounting for up to 30% of brain tumors

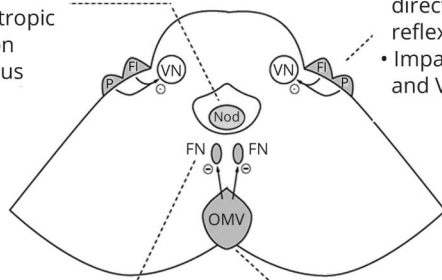
Figure 2 Eye movement abnormalities that have localizing value with respect to the cerebellum

Nodulus/uvula (NOD)

- Periodic alternating nystagmus
- Positional downbeat or positional apogeotropic horizontal direction changing nystagmus

Flocculus/paraflocculus (tonsil)

- Downbeat, gaze evoked and rebound nystagmus
- Abnormal amplitude and direction of vestibulo-ocular-reflex (VOR)
- Impairment of smooth pursuit and VOR cancellation



Fastigial nucleus (FN)

- Hypermetric saccades with fastigial nucleus lesions

Oculomotor vermis (OMV)

- Hypometric saccades with oculomotor vermis lesions

Schematic axial slice through the cerebellum and the brainstem at the level of the pons (figure modified from Leigh et al.¹ by permission of Oxford University Press © 2015). Note that unilateral fastigial nucleus structural lesions do not occur naturally because the projection fibers from one fastigial nucleus pass through the other before passing to the brainstem. Fl = flocculus; P = paraflocculus; VN = vestibular nucleus.

in pediatric studies, though it is uncommon in adults.^{5,6} Patients typically present with symptoms of hydrocephalus, including ataxia.⁶ However, in a series of 10 children who underwent surgical resection and radiotherapy for the treatment of medulloblastoma, the most common feature was gaze-evoked nystagmus in 5 children and 4 had upbeat nystagmus.⁷ Patients with medulloblastoma located in the cerebellar midline may also have vestibular abnormalities including failure of tilt suppression of postrotatory nystagmus.⁸ Another case report described an adult with a medulloblastoma, who presented with headache, positional nystagmus, and vertigo, very similar to BPPV.⁹ The presentation of our patient fits well with these cases.

As with medulloblastoma, patients with the recently described CLIPPERS (chronic lymphocytic inflammation with pontine perivascular enhancement responsive to steroids) syndrome may present with signs of posterior fossa involvement and a normal noncontrast brain MRI.¹⁰ Thus, MRI of the brain with contrast is the imaging of choice in the workup of patients with the clinical presentation of posterior fossa lesion such as ataxia and vertical nystagmus.

Our patient first presented to our clinic with positional downbeat nystagmus. Two weeks later, an upbeat nystagmus was found on straight-ahead gaze. Directional changes of vertical nystagmus have been described before and may be due to the close proximity of these areas in the medulla and their projections, which can cause either upbeat or downbeat nystagmus.^{1,3}

Although our patient had MRIs of the brain, the images may not have been assessed in the context of the clinical presentation of our patient. Alternatively, clinical reasoning was based on written reports of the images rather than analyzing the actual MRI. Looking carefully at the patient's old MRIs, in

retrospect, a lesion in the region of the posterior portion of the fourth ventricle was visible on the first MRI even without contrast. It is thus critical to assess the actual images, not just the reports.

Author contributions

Martin Kronenbueger: design and conceptualization of the study, analysis and interpretation of the data, drafting and revising of the manuscript. Alessandro Olivi: revising of the manuscript. David Zee: design and conceptualization of the study, analysis and interpretation of the data, drafting and revising of the manuscript.

Study funding

No targeted funding reported.

Disclosure

The authors report no disclosures relevant to the manuscript. Go to Neurology.org/N for full disclosures.

References

1. Leigh RJ, Zee DS. *The Neurology of Eye Movements*. 5th ed. Oxford: Oxford University Press; 2015.
2. Kattah JC, Kolsky MP, Guy J, O'Doherty D. Primary position vertical nystagmus and cerebellar ataxia. *Arch Neurol* 1983;40:310–314.
3. Kim JS, Yoon B, Choi KD, Oh SY, Park SH, Kim BK. Upbeat nystagmus: clinicoanatomical correlations in 15 patients. *J Clin Neurol* 2006;2:58–65.
4. Anderson T, Luxon L, Quinn N, Daniel S, Marsden CD, Bronstein A. Oculomotor function in multiple system atrophy: clinical and laboratory features in 30 patients. *Mov Disord* 2008;23:977–984.
5. Takeshi N, Kazuhiko S, Koji I, Toshikazu H, Kaoru K. A case of adult onset medulloblastoma during maintenance chemotherapy for anaplastic astrocytoma one year after radiotherapy. *Turk Neurosurg* 2013;23:521–526.
6. Martin AM, Raabe E, Eberhart C, Cohen KJ. Management of pediatric and adult patients with medulloblastoma. *Curr Treat Options Oncol* 2014;15:581–594.
7. Elliott AJ, Simpson EM, Oakhill A, Decock R. Nystagmus after medulloblastoma. *Dev Med Child Neurol* 1989;31:43–46.
8. Hain TC, Zee DS, Maria BL. Tilt suppression of vestibulo-ocular reflex in patients with cerebellar lesions. *Acta Otolaryngol* 1988;105:13–20.
9. Watson CP, Terbrugge K. Positional nystagmus of the benign paroxysmal type with posterior fossa medulloblastoma. *Arch Neurol* 1982;39:601–602.
10. Zalewski NL, Tobin WO. CLIPPERS. *Curr Neurol Neurosci Rep* 2017;17:65–82.

Neurology®

Pearls & Oysters: Positional vertigo and vertical nystagmus in medulloblastoma: A picture is worth a thousand words

Martin Kronenbuerger, Alessandro Olivi and David S. Zee

Neurology 2018;90:e352-e354

DOI 10.1212/WNL.0000000000004866

This information is current as of January 22, 2018

Updated Information & Services	including high resolution figures, can be found at: http://n.neurology.org/content/90/4/e352.full
References	This article cites 9 articles, 0 of which you can access for free at: http://n.neurology.org/content/90/4/e352.full#ref-list-1
Subspecialty Collections	This article, along with others on similar topics, appears in the following collection(s): Gait disorders/ataxia http://n.neurology.org/cgi/collection/gait_disorders_ataxia MRI http://n.neurology.org/cgi/collection/mri Vertigo http://n.neurology.org/cgi/collection/vertigo
Permissions & Licensing	Information about reproducing this article in parts (figures, tables) or in its entirety can be found online at: http://www.neurology.org/about/about_the_journal#permissions
Reprints	Information about ordering reprints can be found online: http://n.neurology.org/subscribers/advertise

Neurology® is the official journal of the American Academy of Neurology. Published continuously since 1951, it is now a weekly with 48 issues per year. Copyright Copyright © 2018 American Academy of Neurology. All rights reserved. Print ISSN: 0028-3878. Online ISSN: 1526-632X.

