

Teaching Video NeuroImages: Posterior territory stroke with parahippocampal involvement

A neglected cause of neglect

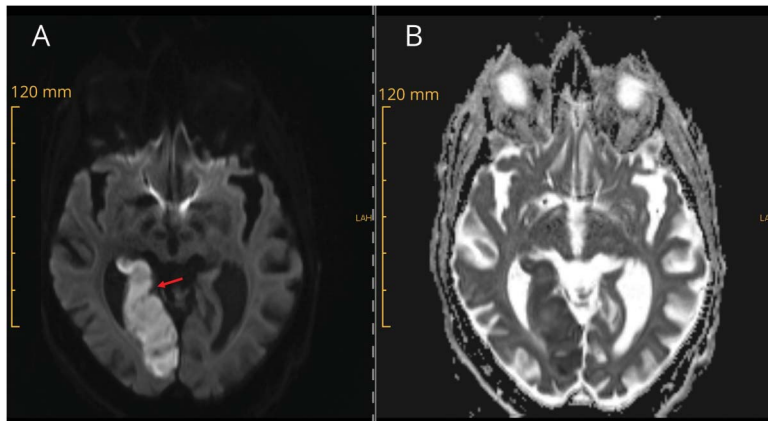
Noortje A.M.M. Maaijwee, MD, PhD, Patricia Dreier, MD, Stephan Bohlhalter, MD, and Thomas Nyffeler, MD

Neurology® 2018;90:e2181. doi:10.1212/WNL.0000000000005687

Correspondence

Dr. Maaijwee
noortje.maaijwee@luks.ch

Figure Brain MRI



(A) Diffusion-weighted imaging sequence and (B) apparent diffusion coefficient sequence show a stroke in the right posterior cerebral artery territory involving the parahippocampal gyrus (see arrow).

An 87-year-old patient presented with a stroke in the right posterior territory (figure), with visual neglect, which was initially thought to be left homonymous hemianopia. The tip of the occipital lobe was spared, however, and therefore complete hemianopia was not to be expected. With a posterior stroke, neglect can easily be overlooked, although it is common in posterior strokes, when the parahippocampal gyrus is involved.¹ The 2 deficits can be tested for separately by turning the body of the patient to the left and the head to the right, because the neglect is body-centered.² (video).

MORE ONLINE

→ Video

→ Teaching slides

links.lww.com/WNL/AS58

Author contributions

Dr. Dreier: acquisition of data, interpretation of symptoms, critical revision of manuscript. Dr. Maaijwee: acquisition of data, interpretation of symptoms, preparation of manuscript. Prof. Nyffeler: interpretation of symptoms, critical revision of manuscript, patient supervision. Prof. Bohlhalter: interpretation of symptoms, critical revision of manuscript, preparation of video, patient supervision.

Study funding

No targeted funding reported.

Disclosure

The authors report no disclosures relevant to the manuscript. Go to Neurology.org/N for full disclosures.

References

1. Mort DJ, Malhotra P, Mannan SK, et al. The anatomy of visual neglect. *Brain* 2003;126:1986–1997.
2. Nyffeler T, Paladini RE, Hopfner S, et al. Contralateral trunk rotation dissociates real vs. pseudo-visual field defects due to visual neglect in stroke patients. *Front Neurol* 2017;8:411.

From Neurocenter (N.A.M.M.M., P.D., S.B., T.N.), Lucerne State Hospital; and Perception and Eye Movement Laboratory (T.N.), Departments of Neurology and Clinical Research, Inselspital, Bern University Hospital and University of Bern, Switzerland.

Go to Neurology.org/N for full disclosures. Funding information and disclosures deemed relevant by the authors, if any, are provided at the end of the article.

Neurology®

Teaching Video NeuroImages: Posterior territory stroke with parahippocampal involvement: A neglected cause of neglect

Noortje A.M.M. Maaijwee, Patricia Dreier, Stephan Bohlhalter, et al.

Neurology 2018;90:e2181

DOI 10.1212/WNL.0000000000005687

This information is current as of June 11, 2018

| | |
|---|---|
| Updated Information & Services | including high resolution figures, can be found at: http://n.neurology.org/content/90/24/e2181.full |
| References | This article cites 2 articles, 0 of which you can access for free at: http://n.neurology.org/content/90/24/e2181.full#ref-list-1 |
| Subspecialty Collections | This article, along with others on similar topics, appears in the following collection(s): All Cerebrovascular disease/Stroke http://n.neurology.org/cgi/collection/all_cerebrovascular_disease_stroke Clinical neurology examination http://n.neurology.org/cgi/collection/clinical_neurology_examination Neglect http://n.neurology.org/cgi/collection/neglect |
| Permissions & Licensing | Information about reproducing this article in parts (figures, tables) or in its entirety can be found online at: http://www.neurology.org/about/about_the_journal#permissions |
| Reprints | Information about ordering reprints can be found online: http://n.neurology.org/subscribers/advertise |

Neurology® is the official journal of the American Academy of Neurology. Published continuously since 1951, it is now a weekly with 48 issues per year. Copyright © 2018 American Academy of Neurology. All rights reserved. Print ISSN: 0028-3878. Online ISSN: 1526-632X.

