

Teaching NeuroImages: Spontaneous regression of AVM feeding pedicle pseudoaneurysms

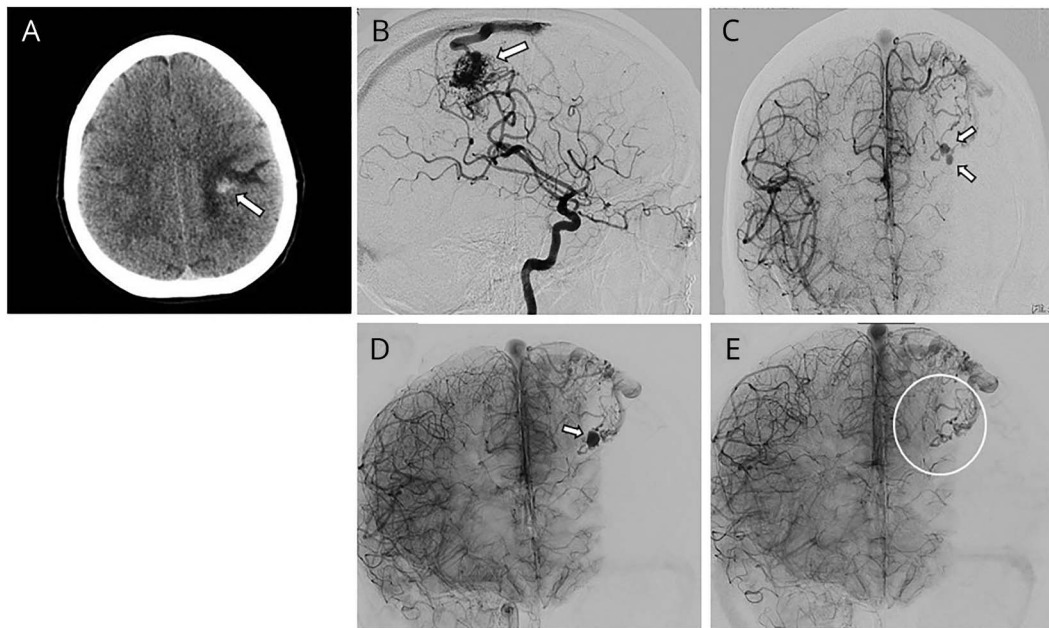
Enrico Giordan, MD,* Lorenzo Rinaldo, MD, PhD,* and Giuseppe Lanzino, MD*

Neurology® 2018;90:e1935-e1936. doi:10.1212/WNL.0000000000005565

Correspondence

Dr. Lanzino
Lanzino.giuseppe@
mayo.edu

Figure Spontaneous resolution of distal feeder pseudoaneurysms



(A) Noncontrast CT shows frontal hemorrhage (arrow). (B) Angiography: left rolandic arteriovenous malformation. (C) Right-sided internal carotid injection: 2 feeding pedicle pseudoaneurysms (arrows). (D) Repeat angiography 2 months later revealed spontaneous obliteration of 1 of the 2 pseudoaneurysms but increase of the other (arrow). (E) One month later, angiography shows spontaneous resolution of the pseudoaneurysm (circle).

A 34-year-old woman had sudden left-sided weakness shortly after delivery. Head CT showed a small hemorrhage (figure, A) secondary to an arteriovenous malformation (figure, B) with 2 small pseudoaneurysms (figure, C). Angiography 2 months later documented obliteration of one of the 2 pseudoaneurysms but growth of the other (figure, D). Embolization of the pedicle bearing the pseudoaneurysm was planned but delayed by 1 month because of patient hesitation to undergo the procedure. Repeat angiogram showed spontaneous resolution (figure, E). Feeding pedicle pseudoaneurysms are dynamic lesions probably secondary to dissection. As remodeling occurs, interval growth, spontaneous regression, or both can be observed.¹

Author contributions

Enrico Giordan: manuscript preparation, drafting manuscript, collection of data and figures, approval of final version. Rinaldo Lorenzo: manuscript preparation, drafting

MORE ONLINE

→ **Teaching slides:**
links.lww.com/WNL/A478

*These authors contributed equally to this work.

From the Department of Neurosurgery, Mayo Clinic, Rochester, MN.

Go to Neurology.org/N for full disclosures. Funding information and disclosures deemed relevant by the authors, if any, are provided at the end of the article.

manuscript, collection of data and figures, approval of final version. Giuseppe Lanzino: manuscript preparation, drafting manuscript, collection of data and figures, approval of final version.

Study funding

No targeted funding reported.

Disclosure

The authors report no disclosures relevant to the manuscript. Go to Neurology.org/N for full disclosures.

Reference

1. Rammos SK, Gardenghi B, Bortolotti C, Cloft HJ, Lanzino G. Aneurysms associated with brain arteriovenous malformations. *AJNR Am J Neuroradiol* Epub 2016 Jun 23.

Neurology®

Teaching NeuroImages: Spontaneous regression of AVM feeding pedicle pseudoaneurysms

Enrico Giordan, Lorenzo Rinaldo and Giuseppe Lanzino

Neurology 2018;90:e1935-e1936

DOI 10.1212/WNL.0000000000005565

This information is current as of May 21, 2018

Updated Information & Services	including high resolution figures, can be found at: http://n.neurology.org/content/90/21/e1935.full
Subspecialty Collections	This article, along with others on similar topics, appears in the following collection(s): All Cerebrovascular disease/Stroke http://n.neurology.org/cgi/collection/all_cerebrovascular_disease_stroke Arteriovenous malformation http://n.neurology.org/cgi/collection/arteriovenous_malformation Intracerebral hemorrhage http://n.neurology.org/cgi/collection/intracerebral_hemorrhage Other cerebrovascular disease/ Stroke http://n.neurology.org/cgi/collection/other_cerebrovascular_disease_stroke
Permissions & Licensing	Information about reproducing this article in parts (figures, tables) or in its entirety can be found online at: http://www.neurology.org/about/about_the_journal#permissions
Reprints	Information about ordering reprints can be found online: http://n.neurology.org/subscribers/advertise

Neurology® is the official journal of the American Academy of Neurology. Published continuously since 1951, it is now a weekly with 48 issues per year. Copyright © 2018 American Academy of Neurology. All rights reserved. Print ISSN: 0028-3878. Online ISSN: 1526-632X.

