

A note of despair

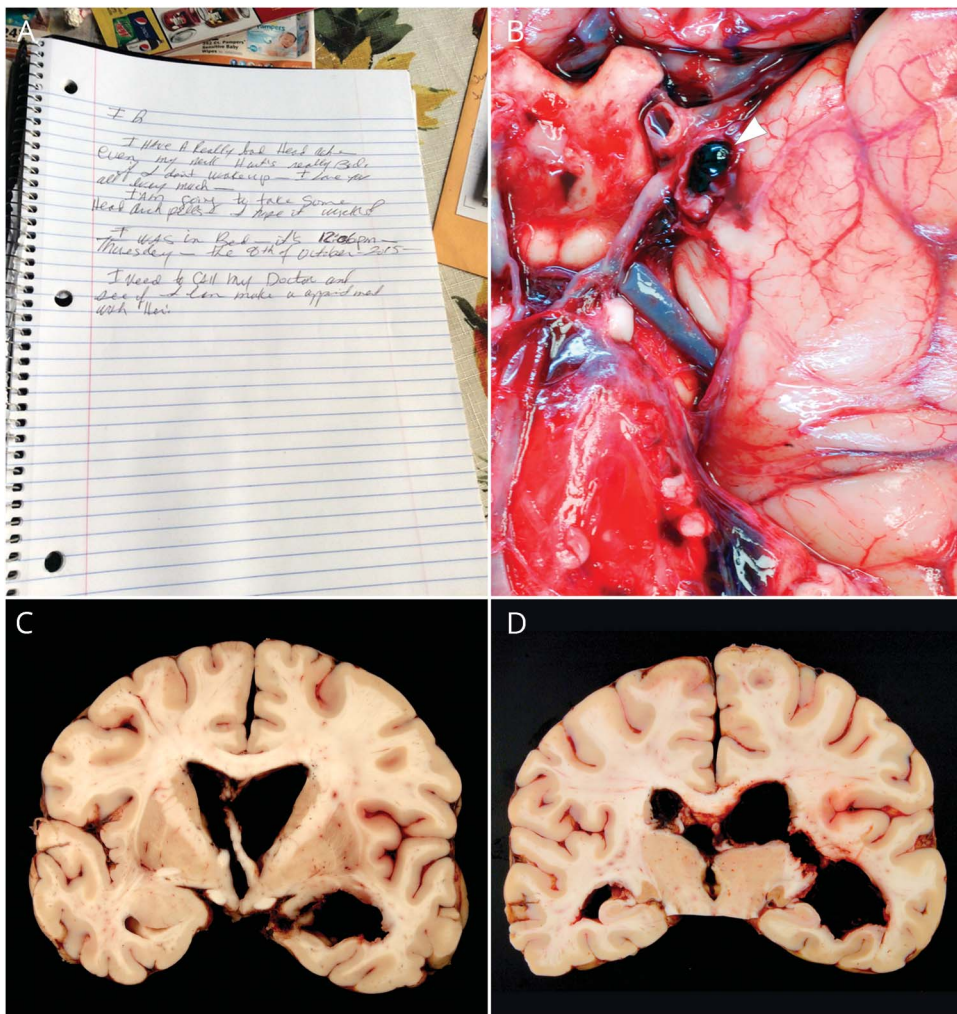
Eelco F.M. Wijdicks, MD, PhD, and Joseph E. Parisi, MD

Neurology® 2018;90:520-521. doi:10.1212/WNL.0000000000005115

Correspondence

Dr. Wijdicks
wijd@mayo.edu

Figure Notebook and autopsy findings



(A) Note found at home: “I have a really bad headache even my neck hurt’s [sic] really bad. If I don’t wake up—I love you all very much—I am going to take some headache pills—I hope it works! I was in bed—it’s 12:06 PM—Thursday October 8, 2015—I need to call my doctor and see if I can make a [sic] appointment with her!” (B) Brain specimen of 65-year-old woman shows a ruptured, 0.9-cm intracranial aneurysm (arrowhead), arising at the junction of the left internal carotid and posterior communicating arteries. (C, D) The aneurysm, which ruptured through the left medial temporal lobe into the temporal horn of the lateral ventricle, was associated with extensive intraventricular and subarachnoid hemorrhage.

The excruciating headache arrived suddenly during the night. Struggling with her health for years, including a history of cardiopulmonary disease, this 65-year-old woman resolved to see a doctor the next day because she had an eerie foreboding it might be serious. She repaired to bed after taking pills and writing a note to her children.

Her son found her dead the next morning. The notebook was on the table. The autopsy showed a ruptured internal carotid artery aneurysm with extensive intraventricular hemorrhage (figure).

The note briefly described her pain, noted the time and date of its onset, her hope that the analgesic she took would help, and her intent to seek medical help in the morning. Poignantly, preparing for the worst scenario (i.e., not waking up at all), she assured her children that she

MORE ONLINE

Audio

Listen to Dr. Wijdicks read this story.

[NPub.org/3qpeep](https://www.ncbi.nlm.nih.gov/pmc/articles/PMC6333333/)

loved them. Her lugubrious note lingered in our minds. Why did she write it? Should others see this memento of life's finitude? Does fear often cause patient delay? Maybe she did not want to go to the emergency room at a peak volume time. Maybe she did not want anyone to worry about her. Did her illness prevent her from being more assertive? It raises many questions, but the answers are elusive.

We do know that fatal subarachnoid aneurysmal hemorrhage has an antecedent or warning in some cases. Although widely cited as occurring in up to 30% of patients, the evidence, requiring after-the-fact interpretation, is inherently insufficient. Recall bias—a prior headache is more easily remembered during a particularly severe recurrence—is a possible explanation.¹ Serial neuroimaging studies have taught us that a rebleed may either be difficult to interpret or plainly ambiguous on CT scans while newly available MRI techniques may be more diagnostic in selected cases. Surprisingly, MRI did demonstrate 3 times more prior bleeds in patients with a subarachnoid hemorrhage than when based on recollection alone (33% vs 10%).²

Textbooks stipulate a new, split-second-onset, unexpected, insufferable headache as a distinctive precursor, and either the patient or the physician must make the call. For the patient: does this different headache warrant seeing a physician? The primary care provider or emergency physician, who sees many headaches during the course of a week, must identify why this headache is unique and merits special attention.

Her note has more than just forensic interest. In our prior epidemiologic study in Olmsted County, Minnesota, 12% of

patients with aneurysmal subarachnoid hemorrhage died before reaching medical attention, but it was not known how many had prior headaches. Most died at home, one at work, and one in a car. Frank intraventricular hemorrhage occurred in over 90% of the patients, and posterior circulation aneurysms and associated pulmonary edema were common.³

These findings would support a mechanism consisting of a major, sudden fourth-ventricle blood rush with neurogenic pulmonary edema and apnea as a coexisting sympathetic response.

This note offers a rare insight into a patient's emotional state shortly before the fatal rerupture of a cerebral aneurysm. The significance is definitive in that it underscores the knowledge of our helplessness in confronting life-threatening illness. And that is probably our human nature.

Acknowledgment

The authors thank the patient's daughter (name withheld) for providing insights and permission to publish. We thank the medical examiner Robert Reichard, MD, and pathologist Aditya Raghunathan, MD, for the dissection.

References

1. Linn FH, Rinkel GJ, Algra A, van Gijn J. The notion of "warning leaks" in subarachnoid hemorrhage: are such patients in fact admitted with a rebleed? *J Neurol Neurosurg Psychiatry* 2000;68:332–336.
2. Oda S, Shimoda M, Hirayama A, et al. Neuroradiologic diagnosis of minor leak prior to major SAH: diagnosis by T1-FLAIR mismatch. *AJNR Am J Neuroradiol* 2015;36:1616–1622.
3. Schievink WI, Wijdicks EF, Parisi JE, Piepgras DG, Whisnant JP. Sudden death from aneurysmal subarachnoid hemorrhage. *Neurology* 1995;45:871–874.

Neurology®

A note of despair

Eelco F.M. Wijdicks and Joseph E. Parisi

Neurology 2018;90;520-521

DOI 10.1212/WNL.0000000000005115

This information is current as of March 12, 2018

Updated Information & Services	including high resolution figures, can be found at: http://n.neurology.org/content/90/11/520.full
References	This article cites 3 articles, 3 of which you can access for free at: http://n.neurology.org/content/90/11/520.full#ref-list-1
Subspecialty Collections	This article, along with others on similar topics, appears in the following collection(s): All Headache http://n.neurology.org/cgi/collection/all_headache Subarachnoid hemorrhage http://n.neurology.org/cgi/collection/subarachnoid_hemorrhage
Permissions & Licensing	Information about reproducing this article in parts (figures, tables) or in its entirety can be found online at: http://www.neurology.org/about/about_the_journal#permissions
Reprints	Information about ordering reprints can be found online: http://n.neurology.org/subscribers/advertise

Neurology® is the official journal of the American Academy of Neurology. Published continuously since 1951, it is now a weekly with 48 issues per year. Copyright © 2018 American Academy of Neurology. All rights reserved. Print ISSN: 0028-3878. Online ISSN: 1526-632X.

