

Neurology[®]

Table of Contents

Volume 88, Number 6, February 7, 2017
Neurology.org

THE MOST WIDELY READ AND HIGHLY CITED PEER-REVIEWED
NEUROLOGY JOURNAL





IN FOCUS





- 507 Spotlight on the February 7 issue
- 550 This Week's *Neurology*[®] Podcast

EDITORIALS

- 508 Do we need to measure specific antibodies in patients with limbic encephalitis?
J. Dalmau and A. Vincent
- 510 Left ventricular wall motion abnormalities: What can they tell us about stroke recurrence?
R. Brouns
- 512 Blood-based biomarkers for evaluating sport-related concussion: Back in the game
B.B. Bendlin and M. Makdissi

ARTICLES

- 514 Characteristics in limbic encephalitis with anti-adenylate kinase 5 autoantibodies
L.-D. Do, E. Chanson, V. Desestret, B. Joubert, F. Ducray, S. Brugière, Y. Couté, M. Formaglio, V. Rogemond, C. Thomas-Antérion, L. Borrega, B. Laurens, F. Tison, J. Curot, T. De Brouker, C. Lebrun-Frenay, J.-Y. Delattre, J.-C. Antoine, and J. Honnorat
 Editorial, p. 508
- 525 Disease-modifying therapies modulate retinal atrophy in multiple sclerosis: A retrospective study
J. Button, O. Al-Louzi, A. Lang, P. Bhargava, S.D. Newsome, T. Frohman, L.J. Balcer, E.M. Frohman, J. Prince, P.A. Calabresi, and S. Saidha
- 533 Sphingosine 1-phosphate lyase deficiency causes Charcot-Marie-Tooth neuropathy
D. Atkinson, J. Nikodinovic Glumac, B. Asselbergh, B. Ermanoska, D. Blocquel, R. Steiner, A. Estrada-Cuzcano, K. Peeters, T. Ooms, E. De Vriendt, X.-L. Yang, T. Hornemann, V. Milic Rasic, and A. Jordanova
- 543 Dystonia treatment: Patterns of medication use in an international cohort
S. Pirio Richardson, A.R. Wegele, B. Skipper, A. Deligtisch, and H.A. Jinnah, for the Dystonia Coalition Investigators


- 551 Neuropathology of SUDEP: Role of inflammation, blood-brain barrier impairment, and hypoxia
Z. Michalak, D. Obari, M. Ellis, M. Thom, and S.M. Sisodiya

- 562 Improving uniformity in brain death determination policies over time
H.H. Wang, P.N. Varelas, G.V. Henderson, E.F.M. Wijdicks, and D.M. Greer

- 569 Multimodal characterization of older APOE2 carriers reveals selective reduction of amyloid load
M.J. Grothe, S. Villeneuve, M. Dyrba, D. Bartrés-Faz, and M. Wirth, for the Alzheimer's Disease Neuroimaging Initiative
- 577 Vascular risk factors in INPH: A prospective case-control study (the INPH-CRasH study)
H. Israelsson, B. Carlberg, C. Wikkelsö, K. Laurell, B. Kahlon, G. Leijon, A. Eklund, and J. Malm
- 586 Left ventricular wall motion abnormalities are associated with stroke recurrence
J.-Y. Choi, J. Cha, J.-M. Jung, W.-K. Seo, K. Oh, K.-H. Cho, and S. Yu
 Editorial, p. 510
- 595 Acute plasma tau relates to prolonged return to play after concussion
J. Gill, K. Merchant-Borna, A. Jeromin, W. Livingston, and J. Bazarian
 Editorial, p. 512

CLINICAL/SCIENTIFIC NOTES

- 603 MTHFR C677T polymorphism is associated with methotrexate-induced myelopathy risk
K. Juster-Switlyk, A.G. Smith, T. Kovacsovics, D. Stephens, M. Glenn, C.A. Palmer, E.P. Quigley III, and N. Kolb

NEUROIMAGES

- 605 CNS chagoma: Reactivation in an immunosuppressed patient
S. Camargos, M. da Consolação Vieira Moreira, D.M. Meneses Cury Portela, J.P. Imperes Lira, F.V. Santos Modesto, G. Marques Miranda Menezes, and D. Ribeiro Moreira

CONTINUED

Neurology[®]

Table of Contents

continued



RESIDENT & FELLOW SECTION

- e44 Clinical Reasoning: A 74-year-old woman with bilateral foot pain and a palmar rash
D.R.P. Wynn, J.M. Donigan, and A. Tkach
- e51 Teaching *NeuroImages*: Rheumatoid pannus of the cervical spine: An unusual cause of multiple cranial nerve palsies
D. Weerasinghe, D. Cordato, J. Kuan, and A. Sturgess

WRITECLICK[®] EDITOR'S CHOICE

- 607 Editors' Note
M. Alcauskas and R.C. Griggs

- 607 Letter re: Neuroimaging overuse is more common in Medicare compared with the VA
J.C. Johnston and T.P. Sartwelle
- 607 Author response: Neuroimaging overuse is more common in Medicare compared with the VA
J.F. Burke and B.C. Callaghan
- 608 Letter re: Neuroimaging overuse is more common in Medicare compared with the VA
J.C. Johnston and T.P. Sartwelle
- 608 Author response: Neuroimaging overuse is more common in Medicare compared with the VA
J.F. Burke and B.C. Callaghan

DEPARTMENT

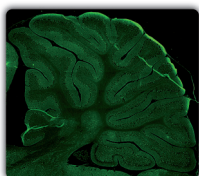
In the Next Issue of *Neurology*[®]

Podcast at Neurology.org CME Video Patient Page LOE classification LOE recommendation



Find us on Facebook

tinyurl.com/neurologyfan twitter.com/GreenJournal



Cover image: Strong reactivity in adult rat brain to CSF of patient with autoimmune encephalitis. See page 514.

Look for **Publish Ahead of Print** articles and editorials under the Ahead of Print tab at Neurology.org



Neurology[®] Online CME Program

Earn CME while reading *Neurology*. This program is available only to online *Neurology* subscribers. Simply read the articles marked CME, go to Neurology.org, and click on CME. This will provide all of the information necessary to get started. The American Academy of Neurology (AAN) is accredited by the Accreditation Council for Continuing Medical Education (ACCME) to sponsor continuing medical education for physicians. *Neurology* is planned and produced in accordance with the ACCME Essentials. For more information, contact AAN Member Services at 800-879-1960.

Neurology[®]

88 (6)

Neurology 2017;88:e44-608

This information is current as of January 1, 2017

Updated Information & Services

including high resolution figures, can be found at:
<http://n.neurology.org/content/88/6.full>

Permissions & Licensing

Information about reproducing this article in parts (figures, tables) or in its entirety can be found online at:
http://www.neurology.org/about/about_the_journal#permissions

Reprints

Information about ordering reprints can be found online:
<http://n.neurology.org/subscribers/advertise>

Neurology® is the official journal of the American Academy of Neurology. Published continuously since 1951, it is now a weekly with 48 issues per year. Copyright . All rights reserved. Print ISSN: 0028-3878. Online ISSN: 1526-632X.

