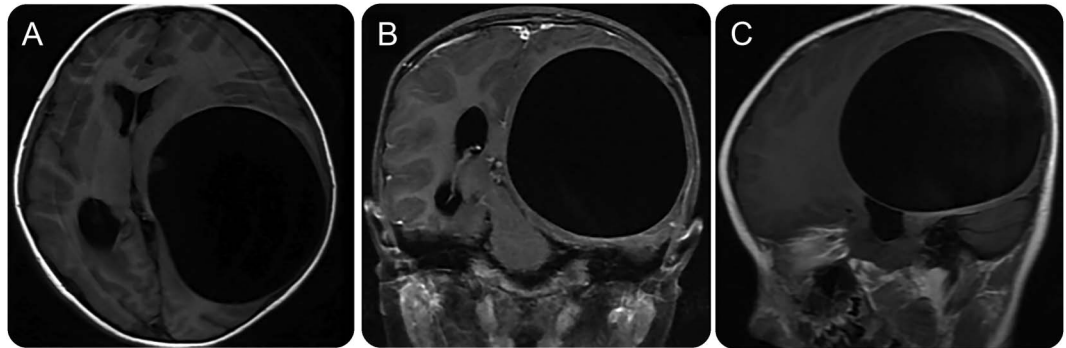


Teaching NeuroImages: Giant cystic echinococcosis with unusual imaging manifestations

Dekang Nie, MD*
Liang Xia, MD*
Jian Chen, MD
Wei Shi, MD
Guan Sun, MD
Jun Guo, MD

Correspondence to
Dr. Guo:
ycyyguojun@163.com
or Dr. Sun:
sunguan2008@sina.com

Figure 1 Echinococcosis images

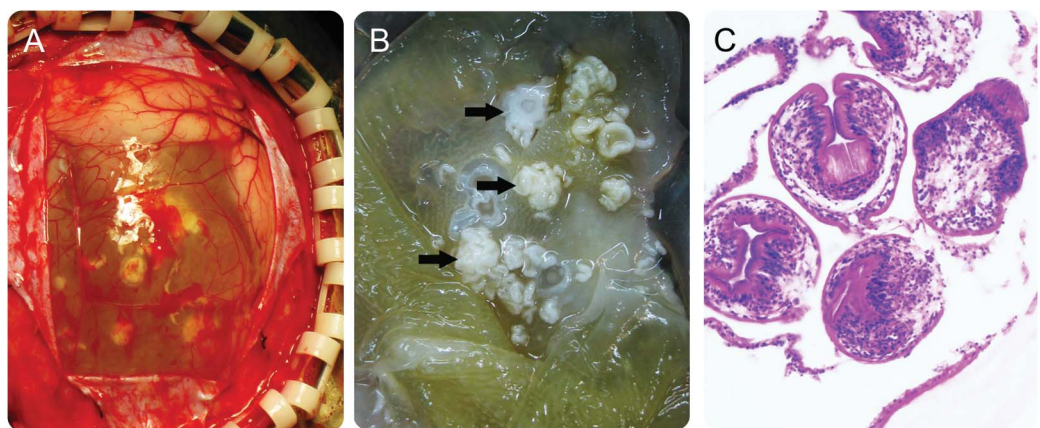


T1-weighted MRI of the spine (A–C) and enhanced MRI (B) demonstrate a single hypointense lesion in the left cerebral hemisphere with no perilesional edema and contrast enhancement.

A 6-year-old girl presented with a 3-month history of progressive left-eye strabismus and vision loss. MRI scan of the brain showed a single hypointense lesion in the left cerebral hemisphere with no perilesional edema or contrast enhancement (figure 1, A–C). At surgery, the lesion was shown to be a single large

parasitic cyst measuring approximately $7.0 \times 6.5 \times 6.0$ cm (figure 2, A–C). The patient underwent a complete resection and then was given antihelminthic therapy. This resulted in an uneventful recovery. Pathology confirmed a diagnosis of brain cyst with scolex. This imaging feature of giant cystic

Figure 2 Imaging of surgical specimens and histopathology



Surgical area (A) and resection specimens (B) show a white floc floating in the cystic fluid (black arrows); thick cyst wall exhibits milkiness. Pathology confirmed a diagnosis of cerebral cyst with scolex (C).

Supplemental data
at Neurology.org

Download teaching slides:
Neurology.org

*These authors contributed equally to this work.

This article is republished with corrections from the original version (Neurology 2016;87:e260–e261).

From the Department of Neurosurgery (D.N., G.S., J.G.), Fourth Affiliated Hospital of Nantong University, Yancheng; Department of Neurosurgery (L.X.), Zhejiang Cancer Hospital, Hangzhou; and Department of Neurosurgery (J.C., W.S.), Affiliated Hospital of Nantong University, Nantong, China.

Go to Neurology.org for full disclosures. Funding information and disclosures deemed relevant by the authors, if any, are provided at the end of the article.

echinococcosis is very unusual.¹ In the event of neurologic dysfunction or elevated intracranial pressure, emergent operative intervention should precede the administration of antihelminthic medications as the latter may weaken the cyst membrane and complicate resection. Gross total resection has advantages compared with nonsurgical treatment with antihelminthics.²

AUTHOR CONTRIBUTIONS

Dekang Nie: drafting/revising the manuscript, study concept or design. Jun Guo: study concept or design and study supervision. Liang Xia: analysis or acquisition of data. Jian Chen: revising the manuscript. Wei Shi: analysis or interpretation of the data. Guan Sun: analysis and interpretation of data.

ACKNOWLEDGMENT

The authors thank staff of the Department of Neurosurgery of the Affiliated Hospital of Nantong University for technical assistance and equipment support.

STUDY FUNDING

No targeted funding reported.

DISCLOSURE

The authors report no disclosures relevant to the manuscript. Go to Neurology.org for full disclosures.

REFERENCES

1. Stojkovic M, Junghans T. Cystic and alveolar echinococcosis. *Handb Clin Neurol* 2013;114:327–334.
2. Hajhouji F, Aniba K, Laghmari M, Lmejjati M, Ghannane H, Benali SA. Epilepsy: unusual presentation of cerebral hydatid disease in children. *Pan Afr Med J* 2016;25:58.

Neurology®

Teaching NeuroImages: Giant cystic echinococcosis with unusual imaging manifestations

Dekang Nie, Liang Xia, Jian Chen, et al.

Neurology 2017;88:e234-e235

DOI 10.1212/WNL.0000000000004055

This information is current as of June 5, 2017

Neurology® is the official journal of the American Academy of Neurology. Published continuously since 1951, it is now a weekly with 48 issues per year. Copyright © 2017 American Academy of Neurology. All rights reserved. Print ISSN: 0028-3878. Online ISSN: 1526-632X.



Updated Information & Services	including high resolution figures, can be found at: http://n.neurology.org/content/88/23/e234.full
Supplementary Material	Supplementary material can be found at: http://n.neurology.org/content/suppl/2017/06/05/WNL.0000000000004055.DC2 http://n.neurology.org/content/suppl/2017/06/05/WNL.0000000000004055.DC1
References	This article cites 2 articles, 0 of which you can access for free at: http://n.neurology.org/content/88/23/e234.full#ref-list-1
Citations	This article has been cited by 1 HighWire-hosted articles: http://n.neurology.org/content/88/23/e234.full##otherarticles
Subspecialty Collections	This article, along with others on similar topics, appears in the following collection(s): Central pain http://n.neurology.org/cgi/collection/central_pain Medical care http://n.neurology.org/cgi/collection/medical_care MRI http://n.neurology.org/cgi/collection/mri Parasitic infections http://n.neurology.org/cgi/collection/parasitic_infections Post-infectious http://n.neurology.org/cgi/collection/postinfectious_
Permissions & Licensing	Information about reproducing this article in parts (figures, tables) or in its entirety can be found online at: http://www.neurology.org/about/about_the_journal#permissions
Reprints	Information about ordering reprints can be found online: http://n.neurology.org/subscribers/advertise

Neurology® is the official journal of the American Academy of Neurology. Published continuously since 1951, it is now a weekly with 48 issues per year. Copyright © 2017 American Academy of Neurology. All rights reserved. Print ISSN: 0028-3878. Online ISSN: 1526-632X.

