

Neurology[®]

Table of Contents

Volume 88, Number 23, June 6, 2017

Neurology.org

THE MOST WIDELY READ AND HIGHLY CITED PEER-REVIEWED
NEUROLOGY JOURNAL



IN FOCUS

- 2157 Spotlight on the June 6 issue
- 2175 This Week's *Neurology*[®] Podcast

EDITORIALS



- 2158 Lacunes: Black holes in our understanding of cerebral amyloid angiopathy
E.E. Smith and J.-M. Lee
- 2160 Restless legs syndrome: Losing sleep over the placebo response
A. Feigin

ARTICLES

- 2162 Distribution of lacunes in cerebral amyloid angiopathy and hypertensive small vessel disease
M. Pasi, G. Boulouis, P. Fotiadis, E. Auriel, A. Charidimou, K. Haley, A. Ayres, K.M. Schwab, J.N. Goldstein, J. Rosand, A. Viswanathan, L. Pantoni, S.M. Greenberg, and M.E. Gural
Editorial, p. 2158
- 2169 Poststroke epilepsy in long-term survivors of primary intracerebral hemorrhage
A.-M. Lahti, P. Saloheimo, J. Huhtakangas, H. Salminen, S. Juvela, M.K. Bode, M. Hillbom, and S. Tetri

- 2176 Prospective association between β_2 -microglobulin levels and ischemic stroke risk among women
P.M. Rist, M.C. Jiménez, and K.M. Rexrode

- 2183 HLA-A*24:02 as a common risk factor for antiepileptic drug-induced cutaneous adverse reactions
Y.-W. Shi, F.-L. Min, D. Zhou, B. Qin, J. Wang, F.-Y. Hu, Y.-K. Cheung, J.-H. Zhou, X.-S. Hu, J.-Q. Zhou, L.-M. Zhou, Z.-z. Zheng, J. Pan, N. He, Z.-S. Liu, Y.-Q. Hou, K.-S. Lim, Y.-m. Ou, A. Hui-Ping Khor, C.-C. Ng, B.-J. Mao, X.-R. Liu, B.-M. Li, Y.-Y. Kuan, Y.-H. Yi, X.-l. He, X.-Y. Deng, T. Su, P. Kwan, and W.-P. Liao
OPEN

- 2192 Early skin denervation in hereditary and iatrogenic transthyretin amyloid neuropathy
T. Masuda, M. Ueda, G. Suenaga, Y. Misumi, M. Tasaki, A. Izaki, Y. Yanagisawa, Y. Inoue, H. Motokawa, S. Matsumoto, M. Mizukami, A. Arimura, T. Deguchi, Y. Nishio, T. Yamashita, Y. Inomata, K. Obayashi, and Y. Ando

- 2198 Randomized trial of preladenant, given as monotherapy, in patients with early Parkinson disease
F. Stocchi, O. Rascol, R.A. Hauser, S. Huyck, A. Tzontcheva, R. Capece, T.W. Ho, P. Sklar, C. Lines, D. Michelson, and D.J. Hewitt, on behalf of the Preladenant Early Parkinson Disease Study Group

- 2207 Role of habenula and amygdala dysfunction in Parkinson disease patients with punding
V. Markovic, F. Agosta, E. Canu, A. Inuggi, I. Petrovic, I. Stankovic, F. Imperiale, T. Stojkovic, V.S. Kostic, and M. Filippi
- 2216 Placebo and nocebo responses in restless legs syndrome: A systematic review and meta-analysis
M.A. Silva, G.S. Duarte, R. Camara, F.B. Rodrigues, R.M. Fernandes, D. Abreu, T. Mestre, J. Costa, C. Trenkwalder, and J.J. Ferreira
Editorial, p. 2160
- 2225 Effects of MCI subtype and reversion on progression to dementia in a community sample
L. Aerts, M. Heffernan, N.A. Kochan, J.D. Crawford, B. Draper, J.N. Trollor, P.S. Sachdev, and H. Brodaty

CLINICAL/SCIENTIFIC NOTES

- 2233 Pathologic confirmation of retinal ganglion cell loss in multiple system atrophy
C.E. Mendoza-Santiesteban, J.-A. Palma, I. Ortuño-Lizarán, N. Cuenca, and H. Kaufmann

NEUROIMAGES

- 2236 Correlating microscopic findings with B-mode ultrasound in cervical artery dissection
R. Dittich

CONTINUED

Neurology[®]

Table of Contents

continued



RESIDENT & FELLOW SECTION

- e221 Clinical Reasoning: A 10-year-old boy with bilateral vision loss
Z. Bulwa, J. Nichols, and N. Gupta
- e225 Clinical Reasoning: A 16-year-old girl with subacute weakness and sensory loss
C. Quintanilla-Bordás, B. Nourbakhsh, J. Strober, C. Raffel, and E. Waubant
- e230 Pearls & Oysters: Symptomatic cerebral vasospasm on conventional angiography following temporal lobe epilepsy surgery
S. Rao, S. Narayanan, R. Nanjireddy, S. Mittal, and M. Basha
- e233 Teaching NeuroImages: Fahr syndrome caused by hypoparathyroidism
E. Dade, V. Saint-Joy, N.A. Haynes, and A.L. Berkowitz
- e234 Teaching NeuroImages: Giant cystic echinococcosis with unusual imaging manifestations
D. Nie, L. Xia, J. Chen, W. Shi, G. Sun, and J. Guo

WRITECLICK[®] EDITOR'S CHOICE

- 2238 Editors' Note
C. Karam and R.C. Griggs

- 2238 Letter re: Teaching NeuroImages: Giant neurocysticercosis with unusual imaging manifestations
O.H. Del Brutto
- 2238 Author response: Teaching NeuroImages: Giant neurocysticercosis with unusual imaging manifestations
J. Guo
- 2238 Letter re: Teaching NeuroImages: Idiopathic hypertrophic pachymeningitis
A. Budhram
- 2239 Author response: Teaching NeuroImages: Idiopathic hypertrophic pachymeningitis
A. Wasilewski and L. Samkoff

RETRACTION

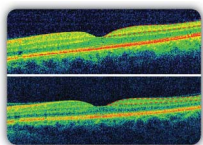
- 2239 Teaching NeuroImages: Giant neurocysticercosis with unusual imaging manifestations

DEPARTMENT

In the Next Issue of *Neurology*[®]

Podcast at Neurology.org CME Video Patient Page LOE classification LOE recommendation

Find us on Facebook tinyurl.com/neurologyfan twitter twitter.com/GreenJournal



Cover image: Optical coherence tomography macular sections showing reduced retinal ganglion cell complex in a patient with multiple system atrophy (lower figure) compared with a healthy control (upper figure). See page 2233.

Look for **Publish Ahead of Print** articles and editorials under the Ahead of Print tab at Neurology.org

Neurology®

88 (23)

Neurology 2017;88:e230-2239

This information is current as of January 1, 2017

Updated Information & Services

including high resolution figures, can be found at:
<http://n.neurology.org/content/88/23.full>

Permissions & Licensing

Information about reproducing this article in parts (figures, tables) or in its entirety can be found online at:
http://www.neurology.org/about/about_the_journal#permissions

Reprints

Information about ordering reprints can be found online:
<http://n.neurology.org/subscribers/advertise>

Neurology® is the official journal of the American Academy of Neurology. Published continuously since 1951, it is now a weekly with 48 issues per year. Copyright . All rights reserved. Print ISSN: 0028-3878. Online ISSN: 1526-632X.

