

Neurology[®]

Table of Contents

Volume 88, Number 1, January 3, 2017

Neurology.org

THE MOST WIDELY READ AND HIGHLY CITED PEER-REVIEWED
NEUROLOGY JOURNAL



IN FOCUS

- 1 Spotlight on the January 3 Issue
- 24 This Week's *Neurology*[®] Podcast



ACKNOWLEDGMENT TO REVIEWERS




- 2 Message from the Editors to our Reviewers
R.A. Gross, B.B. Worrall, A.A. Amato, G.D. Cascino, O. Ciccarelli, J.R. Corboy, J.O. Dalmau, R.F. Gottesman, M. Grossman, J.J. Millichap, J.W. Mink, S.M. Pulst, and R.J. Uitti

EDITORIALS

- 11 Orthostatic hypotension, cognition, and Parkinson disease: Dumbing down by standing up
L.S. Boylan and L. Messinis
- 13 A gestational dose of vitamin D per day keeps the MS doctor away
R.A. Marrie and M. Daumer
- 15 AEDs after ICH: Preventing the prophylaxis
S. Koch and G. Sung

ARTICLES

- 17 Effects of orthostatic hypotension on cognition in Parkinson disease
J. Centi, R. Freeman, C.H. Gibbons, S. Neargarder, A.O. Canova, and A. Cronin-Golomb
 Editorial, p. 11
- 25 Subthalamic nucleus deep brain stimulation in isolated dystonia: A 3-year follow-up study
J.L. Ostrem, M. San Luciano, K.A. Dодenhoff, N. Ziman, L.C. Markun, C.A. Racine, C. de Hemptinne, M.M. Volz, S.L. Heath, and P.A. Starr

- 36 Normative reference values for strength and flexibility of 1,000 children and adults
M.J. McKay, J.N. Baldwin, P. Ferreira, M. Simic, N. Vanicek, and J. Burns, for the 1000 Norms Project Consortium
- 44 Neonatal vitamin D status and risk of multiple sclerosis: A population-based case-control study
N.M. Nielsen, K.L. Munger, N. Koch-Henriksen, D.M. Hougaard, M. Magyari, K.T. Jørgensen, M. Lundqvist, J. Simonsen, T. Jess, A. Cohen, E. Stenager, and A. Ascherio
Editorial, p. 13

- 52 Evolving use of seizure medications after intracerebral hemorrhage: A multicenter study
A.M. Naidech, J. Beaumont, B. Jahromi, S. Prabhakaran, A. Kho, and J.L. Holl
 Editorial, p. 15
- 57 Risk of fractures after stroke: Results from the Ontario Stroke Registry
M.K. Kapral, J. Fang, S.M.H. Alibhai, P. Cram, A.M. Cheung, L.K. Casaubon, M. Prager, M. Stampelcoski, B. Rashkovan, and P.C. Austin
- 65 Carotid artery web and ischemic stroke: A case-control study
J.M. Coutinho, S. Derkatch, A.R.J. Potvin, G. Tomlinson, L.K. Casaubon, F.L. Silver, and D.M. Mandell
- 70 Sleep-related hypermotor epilepsy: Long-term outcome in a large cohort
L. Licchetta, F. Bisulli, L. Vignatelli, C. Zenesini, L. Di Vito, B. Mostacci, C. Rinaldi, I. Trippi, I. Naldi, G. Plazzi, F. Provini, and P. Tinuper
 
- 78 Risk and association of HLA with oxcarbazepine-induced cutaneous adverse reactions in Asians
C.-B. Chen, Y.-H. Hsiao, T. Wu, M.-S. Hsieh, W. Tassaneeyakul, T.P. Jorns, C. Sukasem, C.-N. Hsu, S.-C. Su, W.-C. Chang, R.C.-Y. Hui, C.-Y. Chu, Y.-J. Chen, C.-Y. Wu, C.-K. Hsu, T.-M. Chiu, P.-L. Sun, H.-E. Lee, C.-Y. Yang, P.-h. Kao, C.-H. Yang, H.-C. Ho, J.-Y. Lin, Y.-C. Chang, M.-J. Chen, C.-W. Lu, C.Y. Ng, K.-L. Kuo, C.-y. Lin, C.-S. Yang, D.-P. Chen, P.-Y. Chang, T.-L. Wu, Y.-J. Lin, Y.-C. Weng, T.-t. Kuo, S.-I. Hung, and W.-H. Chung, for the Taiwan Severe Cutaneous Adverse Reaction Consortium
- 87 Revisiting neurofibromatosis type 2 diagnostic criteria to exclude LZTR1-related schwannomatosis
M.J. Smith, N.L. Bowers, M. Bulman, C. Gokhale, A.J. Wallace, A.T. King, S.K.L. Lloyd, S.A. Rutherford, C.L. Hammerbeck-Ward, S.R. Freeman, and D.G. Evans
- 93 Comorbidity between central disorders of hypersomnolence and immune-based disorders
L. Barateau, R. Lopez, I. Arnulf, M. Lecendreux, P. Franco, X. Drouot, S. Leu-Semenescu, I. Jaussent, and Y. Dauvilliers

CONTINUED

Neurology[®]

Table of Contents

continued



CLINICAL/SCIENTIFIC NOTES

- 101 Ibrutinib monotherapy in relapsed/refractory CNS lymphoma: A retrospective case series
K. Chamoun, S. Choquet, E. Boyle, C. Houillier, D. Larrieu-Ciron, A. Al Jijakli, V. Delrieu, V. Delwail, F. Morschhauser, K. Hoang-Xuan, and C. Soussain
▲
- 103 Enlargement of deep medullary veins during the early clinical course of Sturge-Weber syndrome
V.K. Pilli, H.T. Chugani, and C. Juhász

NEUROIMAGES

- 106 Identification of aberrant white matter bundles entering the inferior cerebellar peduncle
K. Blackburn, J. LeMay, G. Dale, L. Calderón-Garcidueñas, and R. Kulesza, Jr.

VIDEO NEUROIMAGES

- 108 Lingual epilepsia partialis continua in neurocysticercosis
S. Sureshbabu, D. Nayak, G. Mittal, S. Peter, C. Sobhana, and V. Aggarwal
📺

RESIDENT & FELLOW SECTION

- e1 Child Neurology: Sjögren-Larsson syndrome
M. Nagappa, P.S. Bindu, S. Chiplunkar, N. Gupta, S. Sinha, P.S. Mathuranath, R.D. Bharath, and A.B. Taly
- e5 Journal Club: Pregnancy outcome following maternal exposure to pregabalin may call for concern
C.R. Jutzeler, J.J. Cragg, F.M. Warner, J. Archibald, C.P.M. Thomas, S. Elliott, and J.L.K. Kramer

- e8 Teaching Video NeuroImages: Minimal anomalies of dorsal midbrain syndrome (Parinaud syndrome)
P. Rojas, P. Maeder, and F.-X. Borruat
📺
- e9 Teaching Video NeuroImages: Purposeless groaning in progressive supranuclear palsy
S.C. Low, A.H. Tan, and S.-Y. Lim
📺

WRITECLICK[®] EDITOR'S CHOICE

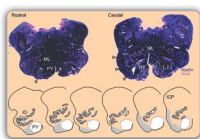
- 110 Editors' Note
C. Karam and R.C. Griggs
- 110 Letter re: Autism and epilepsy: A population-based nationwide cohort study
N.K. Sethi
- 110 Author response: Autism and epilepsy: A population-based nationwide cohort study
H.E.K. Sundelin and J.F. Ludvigsson
- 110 Letter re: CSF concentrations of 5-methyltetrahydrofolate in a cohort of young children with autism
G. Barrett
- 111 Author response: CSF concentrations of 5-methyltetrahydrofolate in a cohort of young children with autism
J. Shoffner

DEPARTMENT

In the Next Issue of *Neurology*[®]

📻 Podcast at Neurology.org 📖 CME 📺 Video 📄 Patient Page ▲ LOE classification 🏠 LOE recommendation

📄 Find us on Facebook [tinyurl.com/neurologyfan](https://www.facebook.com/Neurology) [twitter](https://twitter.com/Neurology) twitter.com/GreenJournal



Cover image: Histologic appearance of aberrant white matter bundles in the medulla, traced from myelin-stained sections. The aberrant axon bundles separate from the pyramidal tracts (PY), course external to the caudal IO, and enter the ICP. See page 106.

Look for **Publish Ahead of Print** articles and editorials under the Ahead of Print tab at Neurology.org

Neurology[®]

88 (1)
Neurology 2017;88:e8-111

This information is current as of January 1, 2017

Updated Information & Services

including high resolution figures, can be found at:
<http://n.neurology.org/content/88/1.full>

Permissions & Licensing

Information about reproducing this article in parts (figures, tables) or in its entirety can be found online at:
http://www.neurology.org/about/about_the_journal#permissions

Reprints

Information about ordering reprints can be found online:
<http://n.neurology.org/subscribers/advertise>

Neurology® is the official journal of the American Academy of Neurology. Published continuously since 1951, it is now a weekly with 48 issues per year. Copyright . All rights reserved. Print ISSN: 0028-3878. Online ISSN: 1526-632X.

