

Neuromyelitis optica spectrum disorders in children and adolescents

Silvia Tenenbaum, MD
Tanuja Chitnis, MD
Ichiro Nakashima, MD
Nicolas Collongues, MD,
PhD
Andrew McKeon, MD
Michael Levy, MD, PhD
Kevin Rostasy, MD

Correspondence to
Dr. Tenenbaum:
silviatenenbaum@gmail.com

ABSTRACT

Neuromyelitis optica (NMO) is a severe autoimmune disease of the CNS characterized by recurrent inflammatory events primarily involving the optic nerves and spinal cord. NMO is infrequent in children, but early recognition is important to start adequate treatment. In this article, we review the evolving diagnostic criteria of NMO and provide an update on the clinical and neuroimaging spectrum of the disorder in pediatric patients, including current knowledge on immunopathogenesis and treatment recommendations for children with NMO. *Neurology*® 2016;87 (Suppl 2):S59-S66

GLOSSARY

AQP4 = aquaporin-4; **AZA** = azathioprine; **CDC** = complement-mediated cytotoxicity; **IgG** = immunoglobulin G; **IPND** = International Panel for NMO Diagnosis; **IVIg** = IV immunoglobulin; **LETM** = longitudinally extensive transverse myelitis; **MMF** = mycophenolate mofetil; **MOG** = myelin oligodendrocyte glycoprotein; **MP** = methylprednisolone; **MS** = multiple sclerosis; **NMO** = neuromyelitis optica; **NMOSD** = neuromyelitis optica spectrum disorder; **ON** = optic neuritis; **PE** = plasma exchange; **RTX** = rituximab; **SLE** = systemic lupus erythematosus; **Th17** = T-helper 17.

Although neuromyelitis optica (NMO) was previously considered a subtype of multiple sclerosis (MS), the identification of autoimmune antibodies (NMO-immunoglobulin G [IgG]) targeted against the aquaporin-4 (AQP4) water channel in the majority of adult patients identified NMO as a different autoimmune disease entity.^{1,2}

The high specificity of AQP4-IgG for NMO has allowed the identification of seropositive patients with atypical presentations of the disease: NMO spectrum disorders (NMOSD).³

Although adults are predominantly affected, NMO/NMOSD has been increasingly recognized in children, who demonstrate a spectrum of disease attacks that often involve CNS areas beyond the optic nerves and spinal cord.⁴ A comprehensive update on NMO/NMOSD in the pediatric population is provided in this article.

DEMOGRAPHICS AND EPIDEMIOLOGY The mean age at NMO presentation ranges from 32 to 45 years in major case series. Population-based studies from Europe, Asia, and South America suggest that the incidence of NMO ranges from 0.05 to 4/100,000/y and the prevalence from 0.52 to 4.4/100,000.⁵ Nevertheless, most of these studies have not stratified data by pediatric or adult age at onset.⁵ Pediatric onset is relatively rare.

In a comprehensive prevalence study from Cuba, a country with a multiracial population, NMO onset prior to the age of 20 years constituted 3.4% of all NMO cases with an overall prevalence rate of 0.12/100,000 persons.⁶ In this study, diagnosis was based on the Wingerchuk et al.⁷ 1999 criteria, in which AQP4 antibody testing was not included.

In a large study of patient samples collected at the Mayo Clinic, 5% of AQP4 antibody-positive patients were children (<18 years), with a mean age at clinical onset of 12 years, a clear female preponderance (7:1), mixed ethnic background, and a poorer prognosis compared with childhood MS.⁴

In 3 prospective studies of children with a first demyelinating syndrome, 0.6% (2/302),⁸ 3.5% (3/86),⁹ and 3.7% (3/81)¹⁰ of patients were identified as having NMO over 3–6 years of follow-up. A similar study on 44 children with optic neuritis (ON) reported a final diagnosis of NMO in 7% of patients.¹¹

From the Department of Pediatric Neurology (S.T.), National Pediatric Hospital Dr. Juan P. Garrahan, Ciudad de Buenos Aires, Argentina; Partners Pediatric MS Center (T.C.), Massachusetts General Hospital, Harvard Medical School, Boston; Department of Neurology (I.N.), Tohoku University School of Medicine, Sendai, Japan; Department of Neurology (N.C.), University Hospitals Strasbourg, Center for Clinical Investigation, INSERM, Strasbourg, France; Departments of Laboratory Medicine and Pathology and Neurology (A.M.), Mayo Clinic, Rochester, MN; Department of Neurology (M.L.), Neuromyelitis Optica Clinic, Johns Hopkins University, Baltimore, MD; and Department of Pediatric Neurology (K.R.), Children's Hospital Datteln, University Witten/Herdecke, Germany.

Go to Neurology.org for full disclosures. Funding information and disclosures deemed relevant by the authors, if any, are provided at the end of the article.

Current data suggest that pediatric-onset NMO accounts for 3%–5% of all NMO cases, depending on the diagnostic criteria utilized and the inclusion of AQP4 antibody testing.

NEW DIAGNOSTIC CRITERIA The past decade has witnessed important advances in our knowledge of NMO, advances initiated by the discovery of the disease-specific autoantibody NMO-IgG.¹

The widely accepted diagnostic criteria were initially proposed by investigators at Mayo Clinic in 1999,⁷ followed by a revision in 2006,¹² both requiring ON and transverse myelitis for NMO diagnosis. The 1999 criteria were published before the biomarker was identified. The 2006 revision was modified accordingly to include the biomarker with at least 2 of the following additional requirements: longitudinally extensive transverse myelitis (LETM) involving 3 or more segments on MRI; initial brain MRI nondiagnostic for MS; or NMO-IgG seropositivity.¹²

The 2006 criteria have been the standard for clinical and research purposes. Nevertheless, the identification of AQP4 antibody in patients with clinical features beyond the 2006 criteria indicated that the phenotypic spectrum may be even broader. The term NMOSD included clinical and radiologic syndromes associated with AQP4 seropositivity, such as the following: (1) limited forms of NMO, including single or recurrent LETM and recurrent or simultaneous bilateral ON; (2) the Asian optic-spinal MS phenotype; (3) ON or myelitis associated with systemic autoimmune diseases; and (4) ON or myelitis associated with brain lesions typical of NMO.³

In 2011, an International Panel for NMO Diagnosis (IPND) integrated by NMO experts was convened to develop a new revision.¹³ According to the revised diagnostic criteria, a new unifying term NMOSD will be used, which is stratified further by serologic testing (NMOSD with or without AQP4-IgG).¹³ The diagnosis of NMOSD with positive AQP4-IgG requires one clinical event involving at least one of the typical anatomic regions (table).¹³ More stringent criteria with additional MRI features are required for the diagnosis of NMOSD without AQP4-IgG or when serologic testing is unavailable (table).¹³ The IPND achieved consensus on pediatric patients and considered that revised diagnostic criteria are appropriate, with minor modifications, in children.¹³ The major caveat is the lower specificity of LETM for NMOSD diagnosis in this age group. LETM may be observed in children with MS¹⁴ as well as in children with ADEM¹⁵ and AQP4-IgG is rarely detected in children with monophasic LETM.¹⁶ Thus, further validation of the IPND criteria in children is required.

CLINICAL PRESENTATION AND OUTCOME In major pediatric case series of NMO and NMOSD,

a first clinical event of ON occurred in 50%–75% of patients and transverse myelitis in 30%–50%, either alone or in combination.^{16–18} A more diffuse involvement of the CNS, including an ADEM-like phenotype, can be observed in approximately 10% of pediatric cases, resulting in a challenging diagnostic situation. Pediatric-onset NMO has been described following infections (influenza or herpes virus) and in some patients following bone marrow transplantation. NMOSD has also been observed in association with another autoimmune disease.

Symptoms of brainstem involvement such as prolonged vomiting unresponsive to antiemetics, with or without hiccups, and cranial nerve dysfunction, are frequently described.¹⁹ Diencephalic impairment is rare and includes endocrinopathies and disorders of water balance.⁴ Further relapses occur in more than 90% of patients with NMOSD and the reported monophasic course was often a consequence of limited longitudinal observation.^{16–18}

In a French study of patients with NMOSD with a long-term follow-up, pediatric onset was associated with more frequent and disabling ON, more diffuse brain lesions on MRI, and lower mortality than in patients with adult onset.¹⁸ Outcome was also marked by the occurrence of cerebral symptoms in 45%–55% of patients, including cognitive decline, seizures, aphasia, narcolepsy, and ataxia.⁴

NEUROIMAGING FINDINGS IN CHILDREN According to previous reports, brain lesions appear more often in pediatric-onset anti-AQP4 antibody-positive NMOSD compared to adult-onset cases.^{4,17–20} These brain lesions are usually large (>2 cm)¹⁸ and tend to localize to areas of high AQP4 expression such as periventricular regions of the III (diencephalic) and IV ventricles (brainstem), supratentorial and infratentorial white matter, midbrain, and cerebellum.⁴ Gadolinium enhancement can be seen in around one-third of patients with brain lesions,^{4,17} often with a cloud-like pattern of enhancement.

Diencephalic (figure 1A), hypothalamic, and area postrema (figure 1B) lesions may be unique to AQP4 antibody-positive cases, having an important role in differentiating NMOSD from other inflammatory disorders of the CNS particularly in children. Similar to ADEM, acute brain lesions tend to resolve on repeated MRIs after treatment.¹⁷

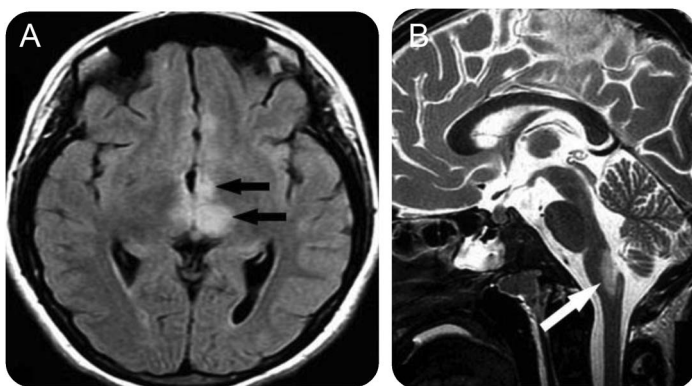
Involvement of optic nerves is usually identified as high-signal longitudinal lesions extending over >1/2 optic nerve length in T2-weighted or short-T1 inversion recovery images, frequently extending posteriorly into the optic chiasm (figure 2). Acute ON is usually identified by gadolinium enhancement, while optic nerve atrophy can be seen in a chronic phase of severely damaged optic nerves. Gadolinium enhancement involving intraorbital fat

Table	Revised NMOSD diagnostic criteria ^a
A. NMOSD with AQP4-IgG	1. ≥ 1 Core clinical characteristic
	2. Positive AQP4-IgG testing using best available method
	3. Exclusion of alternative diagnoses
B. NMOSD without AQP4-IgG or with unknown AQP4-IgG status	1. ≥ 2 Core clinical characteristics occurring as a result of ≥ 1 clinical attacks and meeting all of the following: <ul style="list-style-type: none"> a. At least 1 clinical characteristic: Must be optic neuritis, LETM, or area postrema syndrome b. Dissemination in space (≥ 2 different core clinical characteristics) c. Fulfillment of additional MRI requirements
	2. Negative tests for AQP4-IgG using best available or testing unavailable
	3. Exclusion of alternative diagnoses
	3. Core clinical characteristics <ul style="list-style-type: none"> 1. Optic neuritis 2. Acute myelitis 3. Area postrema syndrome 4. Acute brain stem syndrome 5. Symptomatic narcolepsy or acute diencephalic syndrome with typical diencephalic MRI lesions 6. Symptomatic cerebral syndrome with typical brain lesions
D. Additional MRI requirements <ul style="list-style-type: none"> 1. Acute optic neuritis <ul style="list-style-type: none"> a. Brain MRI normal or showing nonspecific white matter lesions and b. Optic nerve MRI with T2-hyperintense or T1-weighted gadolinium-enhancing lesion extending over $>1/2$ optic nerve length or involving optic chiasm 2. Acute myelitis <ul style="list-style-type: none"> Requires intramedullary MRI lesion extending over ≥ 3 contiguous segments (LETM) or ≥ 3 contiguous segments of spinal cord atrophy in patients with history compatible with acute myelitis 3. Area postrema syndrome <ul style="list-style-type: none"> Requires associated dorsal medulla/area postrema lesions 4. Acute brainstem syndrome <ul style="list-style-type: none"> Requires associated periependymal brainstem lesions 	

Abbreviations: AQP4 = aquaporin-4; IgG = immunoglobulin G; LETM = longitudinally extensive transverse myelitis; NMOSD = neuromyelitis optica spectrum disorder.

^aModified from Wingerchuk et al.¹³

Figure 1 Diencephalic and area postrema lesions in pediatric neuromyelitis optica spectrum disorder



Twelve-year-old girl presenting with intractable vomiting, further developing optic neuritis and longitudinally extensive transverse myelitis (positive aquaporin-4 immunoglobulin G). (A) Axial fluid-attenuated inversion recovery imaging shows typical diencephalic signal changes (black arrows). (B) Sagittal T2-weighted brain MRI with hyperintense lesion in brainstem involving dorsal medulla (area postrema) (white arrow).

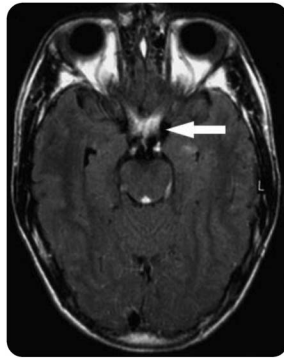
tissue can be observed in children with ON related to NMOSD (figure 3).

Although acute transverse myelitis is not observed as frequently as ON at presentation, it occurs in most children at relapses.⁴ Spinal cord lesions on MRI are usually characterized by extensive centrally located high-signal lesion on T2-weighted images spanning at least 3 segments (figure 4). The spinal cord appears swollen and may show an irregular patchy gadolinium enhancement. Cervical longitudinal myelitis may spread upward into the brainstem. An atypical spinal MRI pattern with a multicystic cord lesion recently has been reported in a young girl with seropositive NMOSD.²¹

CURRENT IMMUNOPATHOGENESIS KNOWLEDGE

This is an active area of research that involves nearly every component of the human immune system. Based on in vitro tissue and cell culture systems, animal models, and human trials, the emerging hypothetical understanding of the mechanisms that trigger an inflammatory

Figure 2 Optic chiasm MRI pattern in pediatric neuromyelitis optica spectrum disorder (NMOSD)

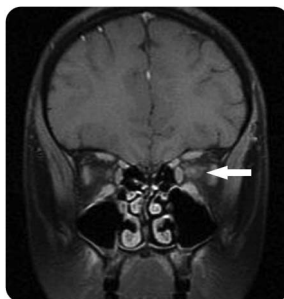


Thirteen-year-old girl presenting with bilateral visual loss due to optic neuritis. Axial fluid-attenuated inversion recovery brain imaging showed optic chiasm involvement (white arrow). Aquaporin-4 immunoglobulin G seropositivity confirmed NMOSD diagnosis.

attack against the optic nerves and spinal cord in NMO is that it begins in the peripheral immune system.

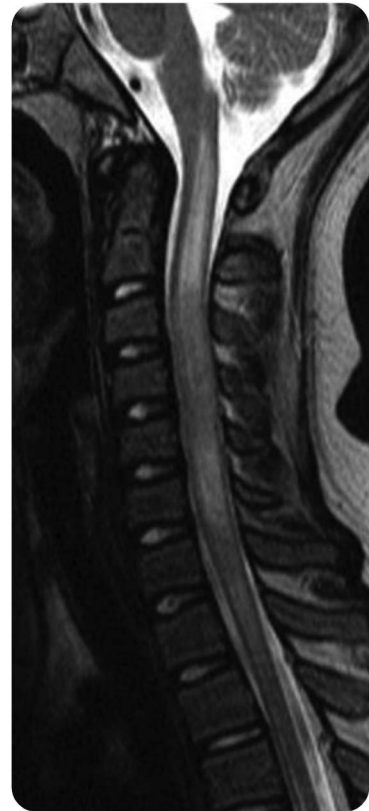The earliest steps in the pathogenesis of NMO may involve molecular mimicry between human AQP4 and nonhuman sequences that resemble AQP4. The important role of T cells in this early process is highlighted by a recent animal model that suggests T cells primed specifically against a region within the second extracellular loop of AQP4 are enough to cause an NMO-like disease in mice. Although AQP4 is expressed on many solid organs in the body, AQP4-reactive T cells in mice polarized to a T-helper 17 (Th17) phenotype specifically attack only the CNS, sparing other AQP4-expressing organs.²² In humans, this adaptive immune process may depend on the antigen presentation capacity of B cells; depletion of B cells from the blood with anti-CD20 monoclonal antibody therapies is remarkably effective at preventing relapses in NMO.²³

Figure 3 Optic neuritis MRI pattern in pediatric neuromyelitis optica spectrum disorder



Aquaporin-4 antibody-positive 15-year-old girl with left optic neuritis. Coronal T1-weighted brain MRI depicts gadolinium enhancement in the intraorbital fat tissue surrounding the optic nerve (white arrow).

Figure 4 Spinal cord MRI pattern in pediatric neuromyelitis optica spectrum disorder



Aquaporin-4 antibody-positive 13-year-old girl with an acute severe myelopathy. Sagittal T2-weighted spinal cord MRI shows a longitudinally extensive lesion extending over more than 3 vertebral segments involving the central spinal cord.

Once the T and B cells conspire to strike the optic nerves or spinal cord, the rest of the immune system is recruited to help carry out the attack. Astrocyte damage occurs early in the process due to antibody binding to AQP4 channels on astrocytic end-feet surrounding blood vessels. Antibody binding triggers damage through both complement and cell-mediated mechanisms beginning with complement C1q binding and activation of the classical complement cascade. Upstream complement components C3a and C5a are potent stimuli for recruitment of granulocytes including neutrophils and eosinophils that attack the astrocyte by AQP4-specific antibody-dependent cell-mediated cytotoxicity. Downstream complement components form the membrane attack complex and exacerbate the damage to astrocytes through complement-mediated cytotoxicity (CDC). Demyelination, oligodendrocyte cell death, microglial activation, and axonal injury are thought to be secondary consequences of the primary attack against astrocytes. Whether and how the purported disease pathogenesis described above differs in children with NMO compared to adults remains to be elucidated.

AQUAPORIN-4-IGG SEROLOGY In 2004, Lennon et al.¹ described a specific pattern of patient IgG antibody reactivity in a tissue-based indirect immunofluorescence assay with high specificity (but limited sensitivity, 48%) for the relapsing form of NMO, known as NMO-IgG (AQP4-IgG).²

Subsequent generations of antigen-specific AQP4-IgG assay development have yielded progressive performance improvement. The isoform of AQP4 used as antigen (either the full-length M1 or shorter M23 isoform) may affect assay performance characteristics.²⁴ ELISA using M1-AQP4 as antigen demonstrated a sensitivity of approximately 60%.^{24,25} Although a specificity of 99%–100% has been reported for that assay, suspected false-positive results have been encountered in clinical laboratory practice.²⁴ Several groups have reported improved sensitivity (75%–83%) and specificity (approaching 100%) utilizing cell-based AQP4-IgG assays.²⁵ In particular, flow cytometry has demonstrated promise as a high-throughput method suitable for use in large-scale clinical laboratories.

Different studies in children with NMOSD have reported a wide range of AQP4-IgG seropositivity from 17% to 80%.^{16–18,26} Similar to adults, NMO-IgG seropositivity in children is usually associated with a relapsing course.¹⁶ Nevertheless, 10%–40% of patients diagnosed with NMOSD remain seronegative for AQP4 antibodies. Some or all of these AQP4-seronegative patients may be affected by an alternative autoimmune or inflammatory disease mechanism.

MYELIN OLIGODENDROCYTE GLYCOPROTEIN (MOG) ANTIBODIES IN CHILDREN MOG antibodies have been described in a variety of pediatric demyelinating disease phenotypes including recurrent ON, pediatric MS, ADEM, and monophasic or recurrent ON following an ADEM onset (ADEM-ON).^{27,28} MOG antibodies, which are predominantly from the IgG1 subtype and directed against the MOG protein expressed at the outmost surface of the myelin sheath, have been demonstrated to be capable of inducing CDC in vitro.

Anti-MOG seropositivity has also been found in a subgroup of adults^{29,30} and children³¹ with AQP4 antibody seronegative NMOSD. The relationship appears to be reciprocal, with no patients reported to have both MOG and AQP4 antibodies. In cohorts of adult patients with NMOSD, reported frequencies of MOG antibodies range from 7% to 20%. In adults and children, the female to male ratio is nearly equal, and adults with MOG antibodies are younger than those without. Clinical evaluation suggests that patients with NMOSD with positive anti-MOG response and negative anti-AQP4 serotype tend to have fewer severe attacks, bilateral ON, and more

caudal myelitis, and recover better than patients with AQP4 antibodies and those who were seronegative for both antibodies.^{29,30}

Disseminated brain lesions resembling those described in ADEM and NMOSD may be identified in children with MOG antibodies, although these lesions rarely involve periependymal areas and are preferentially seen involving basal ganglia. These brain MRI lesions demonstrate resolution in follow-up imaging, without new T2, fluid-attenuated inversion recovery, or gadolinium-enhancing lesions.

Overall, it appears that MOG antibodies are present in a variety of pediatric inflammatory disorders, some of them with a phenotype consistent with NMOSD. It may be important to recognize this particular subset of patients with NMOSD who may have a distinct underlying disease mechanism.

COEXISTING AUTOIMMUNE DISEASES AND AUTOANTIBODIES

The coexistence of other autoimmune diseases and autoantibody accompaniments further distinguish pediatric NMOSD from MS. Commonly encountered autoimmune diseases include organ-specific disorders (e.g., thyroid disease, type 1 diabetes, celiac disease) and non-organ-specific disorders (systemic lupus erythematosus [SLE], Sjögren syndrome).⁴ Autoantibody biomarkers of these disorders are also frequently detected in patients with NMOSD, sometimes without the associated clinical disorder. Antinuclear antibodies are the most frequently found non-organ-specific autoantibodies (64%).⁴ Of note, AQP4-IgG is not detected in patients with Sjögren syndrome or SLE without CNS involvement. Organ-specific autoantibodies routinely detected in patients with NMOSD include thyroid peroxidase and thyroglobulin antibodies (13%), while phospholipid antibodies and celiac disease–related antibodies have also been described.

Coexisting neural autoantibodies are commonly detected in AQP4-IgG seropositive patients with NMOSD and rarely in patients with MS. A report including children with NMOSD described that muscle acetylcholine receptor antibody was the most common coexisting neural antibody detected (11%), though just 2% had coexisting myasthenia gravis.³² Other neural autoantibodies detectable in pediatric NMOSD include those targeting voltage-gated calcium channel and potassium channel complexes, the 65 kDa isoform of glutamic acid decarboxylase,⁴ as well as the NMDA receptor antibody.

TREATMENT STRATEGIES: ACUTE EVENTS AND RELAPSE PREVENTION

Treatment of NMOSD includes the management of acute attacks, prevention of clinical exacerbations, monitoring of treatment-

associated adverse events, and decisions regarding switching therapy due to lack of tolerability or treatment failure.^{23,33} Currently, there are no controlled clinical trials performed in patients with NMOSD, and treatment decisions are largely guided by case series and expert opinions.^{23,33} A consensus article on the treatment of NMOSD²³ and a treatment update focused on pediatric patients³⁴ have been published recently.

Treatment of acute events. In an acute event, whether the initial or an exacerbation of NMOSD, management is focused on minimizing irreversible damage to the CNS and restoring neurologic function.

IV methylprednisolone (MP). The recommended daily dose of IV MP is 30 mg/kg/d to a maximum of 1,000 mg daily, for 5 consecutive days.

Plasma exchange (PE). Retrospective studies and case series including children with NMOSD have reported marked improvement in visual and motor function following PE (5–7 cycles).^{23,33}

IV immunoglobulin (IVIg) therapy. A small study has reported successful relapse improvement in half of patients with NMOSD using IVIg after lack of response to steroids.³³ Interestingly, the effect of human IgG in reducing lesion severity in a rat model has been reported recently, providing mechanistic data to encourage further clinical assessment.³⁵

Preventive therapy. Azathioprine (AZA). Two retrospective studies including children with NMOSD^{36,37} reported marked reductions in relapse rates (89%), with 60% of patients remaining relapse-free at 18 months, using 2–3 mg/kg/d of AZA. Nevertheless, high rates of discontinuation (46%) over time were also reported.³⁷

Rituximab (RTX). The recommended dose in children is 375 mg/m² weekly for 4 weeks, with additional IV infusions depending on the CD19+ B-cell count to maintain immunosuppression.^{23,34} Efficacy in reducing relapse frequency has been reported in children and adults with NMOSD treated with RTX, with stabilization or improvement of disability.^{23,38}

Mycophenolate mofetil (MMF). The use of MMF was well-tolerated and induced reduction of relapse frequency with improvement of disability in 2 retrospective studies including children (median dose 2,000 mg/d).³⁹

Methotrexate. A sustained remission (36 months) was reported in a single child treated with methotrexate.⁴

Cyclophosphamide. Most of the few children treated with monthly IV cyclophosphamide pulse (1,000 mg/m²) for 6 months needed to be switched to other therapies due to lack of efficacy.^{4,16,18}

Mitoxantrone hydrochloride. The use of mitoxantrone in pediatric NMOSD is limited to a single patient¹⁸

who was finally switched to other treatments (AZA and MMF).

Combination therapies. Oral steroids combined with AZA is the most frequently used combination therapy.³⁶ Cyclosporine A with low-dose oral steroids also has been reported as effective in adult patients with NMOSD.⁴⁰

Treatments not recommended for patients with NMOSD. Interferon- β , natalizumab, and fingolimod can precipitate dramatic flare-up of NMOSD.^{23,33} Alemtuzumab has been reported as ineffective in adult patients with NMOSD. The use of mitoxantrone and cyclophosphamide also should be avoided in children considering their potential severe side effects.

New therapeutic agents. Considering that current NMOSD treatment is only partially effective, new agents are being evaluated in trials, including the following:

1. Eculizumab (anti-C5 monoclonal antibody)
2. Tocilizumab (anti-IL-6R monoclonal antibody targeting T- and B-cell activation, Th17 differentiation, and plasmablast survival)
3. Aquaporin-4 (AQP4)-specific antibody (competitive, nonpathogenic anti-AQP4-specific antibody)
4. Neutrophil elastase inhibitors
5. Antihistamines with eosinophil-stabilizing actions
6. Enzymatic AQP4-IgG deglycosylation or cleavage

Treatment recommendations. Considering the current evidence, the following treatment recommendations for pediatric NMOSD may be suggested^{23,34}:

1. Initial therapies: AZA (with oral steroid), RTX, or MMF
2. Patient monitoring with blood and liver function tests
3. In case of adverse events or poor response: Treatment may be switched from AZA to RTX or MMF
4. In case of continuing poor response: A combination of immunosuppression and chronic intermittent PE may be considered
5. IVIg may be used as initial therapy when immunosuppression is contraindicated
6. In case of continuing disease progression: Newer agents may be considered

FUTURE DIRECTIONS Progress in terms of improved diagnostic and treatment approach seen in adults and a better understanding of NMOSD pathophysiology may be extrapolated to children. Treatment options for children with NMOSD are available, and will continue to expand. Nevertheless, more studies in the pediatric population with NMOSD are necessary,

including alternative pathways for AQP4-seronegative children, and more data on long-term safety and treatment response of the old and newer therapeutic agents.

AUTHOR CONTRIBUTIONS

Dr. Silvia Tenenbaum conceived and designed the work, analyzed the literature, wrote the abstract, introduction, new diagnostic criteria, treatment strategies, future directions, and table, and selected the pictures. Dr. Tanuja Chitnis analyzed the literature, and wrote demographics and epidemiology, MOG antibodies, and NMOSD. Dr. Ichiro Nakashima analyzed the literature, wrote neuroimaging findings in children, and selected the pictures. Dr. Nicolas Collongues analyzed the literature and wrote clinical presentation and outcome. Dr. Andrew McKeon analyzed the literature and wrote AQP4-IgG serology and coexisting auto-antibodies. Dr. Michael Levy analyzed the literature and wrote current immunopathogenesis knowledge. Dr. Kevin Rostasy analyzed the literature and wrote MOG antibodies and NMOSD. All authors contributed extensively to the editing and consensus-finding process of all sections of the manuscript, critically reviewed and revised the manuscript, and approved the final manuscript.

STUDY FUNDING

This supplement is made possible by funding from the MS Cure Fund, Danish MS Society, German MS Society, Italian MS Association, MS International Federation, MS Research Foundation (Netherlands), National MS Society (USA) and Swiss MS Society.

DISCLOSURE

S. Tenenbaum served as an advisory board member or speaker for Merck Serono. Professional travel/accommodations expenses have been awarded to Dr. Tenenbaum by Merck-Serono. She serves on a clinical trial advisory board for Genzyme-Sanofi. T. Chitnis has received personal compensation for advisory board/consulting for Biogen-Idec, Merck-Serono, and Novartis, and has received research support from Merck-Serono and Novartis Pharmaceuticals. She serves on clinical trial advisory boards for Genzyme-Sanofi and Novartis. I. Nakashima received funding for a trip and speaks for Biogen Idec Japan (2012–2014), Tanabe Mitsubishi (2012–2015), and Novartis Pharma (2012–2014), serves as an editorial board member of *Multiple Sclerosis International* (2010–present), and received grant support from LSI Medience Corporation (2012–2014). N. Collongues serves on scientific advisory boards for and has received honoraria from Biogen Idec, Merck Serono, Novartis, Teva, Sanofi-Genzyme, Bayer Schering Pharma, and Alexion Pharmaceutical. A. McKeon reports no disclosures relevant to the manuscript. M. Levy receives research support from NIH, Guthy Jackson Charitable Foundation, Viropharma, Acorda, Sanofi, Neural Stem, and Genentech, and serves as a consultant for Chugai Pharmaceuticals, GlaxoSmithKline, and Medimmune. K. Rostasy reports no disclosures relevant to the manuscript. Go to Neurology.org for full disclosures.

Received August 19, 2015. Accepted in final form January 4, 2016.

REFERENCES

1. Lennon VA, Wingerchuk DM, Kryzer TJ, et al. A serum autoantibody marker of neuromyelitis optica: distinction from multiple sclerosis. *Lancet* 2004;364:2106–2112.
2. Lennon VA, Kryzer TJ, Pittock SJ, Verkman AS, Hinson SR. IgG marker of optic-spinal multiple sclerosis binds to the aquaporin-4 water channel. *J Exp Med* 2005; 202:473–477.
3. Wingerchuk DM, Lennon VA, Lucchinetti CF, et al. The spectrum of neuromyelitis optica. *Lancet Neurol* 2007;6: 805–815.
4. McKeon A, Lennon VA, Lotze T, et al. CNS aquaporin-4 autoimmunity in children. *Neurology* 2008;71:93–100.

5. Pandit L, Asgari N, Apiwattanakul M, et al. Demographic and clinical features of neuromyelitis optica: a review. *Mult Scler* 2015;21:845–853.
6. Cabrera-Gomez JA, Kurtzke JF, González-Quevedo A, Lara-Rodríguez R. An epidemiological study of neuromyelitis optica in Cuba. *J Neurol* 2009;256:35–44.
7. Wingerchuk DM, Hogancamp WF, O'Brien PC, Weinshenker BG. The clinical course of neuromyelitis optica (Devic's syndrome). *Neurology* 1999;53:1107–1114.
8. Banwell B, Bar-Or A, Arnold DL, et al. Clinical, environmental, and genetic determinants of multiple sclerosis in children with acute demyelination: a prospective national cohort study. *Lancet Neurol* 2011;10:436–445.
9. Ketelslegers IA, Catsman-Berrevvoets CE, Neuteboom RF, et al. Incidence of acquired demyelinating syndromes of the CNS in Dutch children: a nationwide study. *J Neurol* 2012;259:1929–1935.
10. Langer-Gould A, Zhang JL, Chung J, et al. Incidence of acquired CNS demyelinating syndromes in a multiethnic cohort of children. *Neurology* 2011;77:1143–1148.
11. Absoud M, Cummins C, Desai N, et al. Childhood optic neuritis clinical features and outcome. *Arch Dis Child* 2011;96:860–862.
12. Wingerchuk DM, Lennon VA, Pittock SJ, et al. Revised diagnostic criteria for neuromyelitis optica. *Neurology* 2006;66:1485–1489.
13. Wingerchuk D, Banwell B, Bennett JL, et al. International consensus diagnostic criteria for neuromyelitis optica spectrum disorders. *Neurology* 2015;85:177–189.
14. Verhey LH, Branson HM, Makhija M, et al. Magnetic resonance imaging features of the spinal cord in pediatric multiple sclerosis: a preliminary study. *Neuroradiology* 2010;52:1153–1162.
15. Tenenbaum S, Chitnis T, Ness J, et al. Acute disseminated encephalomyelitis. *Neurology* 2007;68:S23–S36.
16. Banwell B, Tenenbaum S, Lennon VA, et al. Neuromyelitis optica-IgG in childhood inflammatory demyelinating CNS disorders. *Neurology* 2008;70:344–352.
17. Absoud M, Lim MJ, Appleton R, et al. Paediatric neuromyelitis optica: clinical, MRI of the brain and prognostic features. *J Neurol Neurosurg Psychiatry* 2015;86:470–472.
18. Collongues N, Marignier R, Zephir H, et al. Long-term follow-up of neuromyelitis optica with a pediatric onset. *Neurology* 2010;75:1084–1088.
19. Kremer L, Mealy M, Jacob A, et al. Brainstem manifestations in neuromyelitis optica: a multicenter study of 258 patients. *Mult Scler* 2014;20:843–847.
20. Pena JA, Ravelo ME, Mora-La Cruz E, Montiel-Nava C. NMO in pediatric patients: brain involvement and clinical expression. *Arq Neuropsiquiatr* 2011;69:34–38.
21. Longoni G, Bigi S, Branson HM, et al. Multicystic demyelinating myelopathy: widening spectrum of pediatric aquaporin-4 autoimmunity. *Neurology* 2014;82: 902–903.
22. Bukhari W, Barnett MH, Prain K, Broadley SA. Molecular pathogenesis of neuromyelitis optica. *Int J Mol Sci* 2012;13:12970–12993.
23. Kimbrough DJ, Fujihara K, Jacob A, et al. Treatment of neuromyelitis optica: review and recommendations. *Mult Scler Relat Disord* 2012;1:180–187.
24. Fryer JP, Lennon VA, Pittock SJ, et al. AQP4 autoantibody assay performance in clinical laboratory service. *Neurol Neuroimmunol Neuroinflamm* 2014;1:e11.

25. Waters PJ, McKeon A, Leite MI, et al. Serologic diagnosis of NMO: a multicenter comparison of aquaporin-4-IgG assays. *Neurology* 2012;78:665–671.
26. Fragoso YD, Ferreira ML, Oliveira EML, et al. Neuromyelitis optica with onset in childhood and adolescence. *Ped Neurol* 2014;50:66–68.
27. Rostasy K, Mader S, Schanda K, et al. Anti-myelin oligodendrocyte glycoprotein antibodies in pediatric patients with optic neuritis. *Arch Neurol* 2012;69:752–756.
28. Rostasy K, Reindl M. Role of autoantibodies in acquired inflammatory demyelinating diseases of the central nervous system in children. *Neuropediatrics* 2013;44:297–301.
29. Sato DK, Callegaro D, Lana-Peixoto MA, et al. Distinction between MOG antibody-positive and AQP4 antibody-positive NMO spectrum disorders. *Neurology* 2014;82:474–481.
30. Kitley J, Waters P, Woodhall M, et al. Neuromyelitis optica spectrum disorders with aquaporin-4 and myelin-oligodendrocyte glycoprotein antibodies: a comparative study. *JAMA Neurol* 2014;71:276–283.
31. Rostasy K, Mader S, Hennes EM. Persisting myelin oligodendrocyte glycoprotein antibodies in aquaporin-4 antibody negative pediatric neuromyelitis optica. *Mult Scler* 2013;19:1052–1059.
32. McKeon A, Lennon VA, Jacob A, et al. Coexistence of myasthenia gravis and serological markers of neurological autoimmunity in neuromyelitis optica. *Muscle Nerve* 2009;39:87–90.
33. Trebst C, Jarius S, Berthele A, et al. Update on the diagnosis and treatment of neuromyelitis optica: recommendations of the neuromyelitis optica study group (NEMOS). *J Neurol* 2014;261:1–16.
34. Tenenbaum S. Treatment of multiple sclerosis and neuromyelitis optica in children and adolescents. *Clin Neurol Neurosurg* 2013;115(suppl 1):S21–S29.
35. Ratelade J, Smith AJ, Verkman AS. Human immunoglobulin G reduces the pathogenicity of aquaporin-4 autoantibodies in neuromyelitis optica. *Exp Neurol* 2014;255:145–153.
36. Costanzi C, Matiello M, Lucchinetti CF, et al. Azathioprine: tolerability, efficacy, and predictors of benefit in neuromyelitis optica. *Neurology* 2011;77:659–666.
37. Elson L, Kitley J, Luppe S, et al. Long-term efficacy, tolerability, and retention rate of azathioprine in 103 aquaporin-4 antibody-positive neuromyelitis optica spectrum disorder patients: a multicentre retrospective observational study from the UK. *Mult Scler* 2014;20:1533–1540.
38. Mahmood NA, Silver K, Onel K. Efficacy and safety of rituximab in pediatric neuromyelitis optica. *J Child Neurol* 2011;26:244–247.
39. Jacob A, Matiello M, Weinschenker BG, et al. Treatment of neuromyelitis optica with mycophenolate mofetil: retrospective analysis of 24 patients. *Arch Neurol* 2009;66:1128–1133.
40. Kageyama T, Komori M, Miyamoto K, et al. Combination of cyclosporine A with corticosteroids is effective for the treatment of neuromyelitis optica. *J Neurol* 2013;260:627–634.

Neurology®

Neuromyelitis optica spectrum disorders in children and adolescents

Silvia Tenembaum, Tanuja Chitnis, Ichiro Nakashima, et al.

Neurology 2016;87;S59-S66

DOI 10.1212/WNL.0000000000002824

This information is current as of August 29, 2016

Updated Information & Services	including high resolution figures, can be found at: http://n.neurology.org/content/87/9_Supplement_2/S59.full
References	This article cites 40 articles, 3 of which you can access for free at: http://n.neurology.org/content/87/9_Supplement_2/S59.full#ref-list-1
Citations	This article has been cited by 3 HighWire-hosted articles: http://n.neurology.org/content/87/9_Supplement_2/S59.full##otherarticles
Subspecialty Collections	This article, along with others on similar topics, appears in the following collection(s): All Pediatric http://n.neurology.org/cgi/collection/all_pediatric MRI http://n.neurology.org/cgi/collection/mri
Permissions & Licensing	Information about reproducing this article in parts (figures, tables) or in its entirety can be found online at: http://www.neurology.org/about/about_the_journal#permissions
Reprints	Information about ordering reprints can be found online: http://n.neurology.org/subscribers/advertise

Neurology® is the official journal of the American Academy of Neurology. Published continuously since 1951, it is now a weekly with 48 issues per year. Copyright © 2016 American Academy of Neurology. All rights reserved. Print ISSN: 0028-3878. Online ISSN: 1526-632X.

