

# Teaching NeuroImages: Recurrent oculomotor palsies caused by neurosarcoidosis

Veronika Kana, MD,  
PhD  
Jens A. Petersen, MD  
Kristian Ikenberg, MD  
Ariane Chappaz, MD  
Christina Gerth-Kahlert,  
MD  
Philippe Appenzeller, MD  
Michael Linnebank, MD

Correspondence to  
Dr. Kana:  
veronika.kana@mssm.edu

Download teaching slides:  
[Neurology.org](http://Neurology.org)

A 53-year-old man presented with a recurrent left fourth nerve and acute left third nerve palsy (figure 1). Brain MRI showed leptomeningeal and oculomotor nerve contrast enhancement (figure 2). CSF examination indicated chronic lymphocytic meningitis with massively increased soluble interleukin (IL)-2 receptor and IL-6.<sup>1</sup> Extensive infectious disease workup remained unremarkable. [<sup>18</sup>F]-Fluorodeoxyglucose (FDG)-PET/CT revealed active deep cervical lymph nodes containing noncaseating granulomas (figure 2). No pulmonary or other systemic manifestation was found, consistent with clinically isolated neurosarcoidosis.<sup>2</sup> Upon immunosuppressive treatment,<sup>1,2</sup> the oculomotor palsies rapidly remitted. Neurosarcoidosis is a rare condition lacking specific biomarkers.<sup>2</sup> When suspected, FDG-PET/CT can guide diagnosis and prevent CNS biopsy.<sup>1</sup>

### AUTHOR CONTRIBUTIONS

V.K., J.A.P., K.I., A.C., C.G.-K., P.A., and M.L. were involved in the clinical management of the patient. V.K. wrote the manuscript. J.A.P., K.I., A.C., C.G.-K., P.A., and M.L. commented on the manuscript.

### ACKNOWLEDGMENT

The authors thank the patient for consenting to the publication, the colleagues who were involved in treatment of the patient, and the photographers P. Bär and P. Breitschmid.

### STUDY FUNDING

No targeted funding reported.

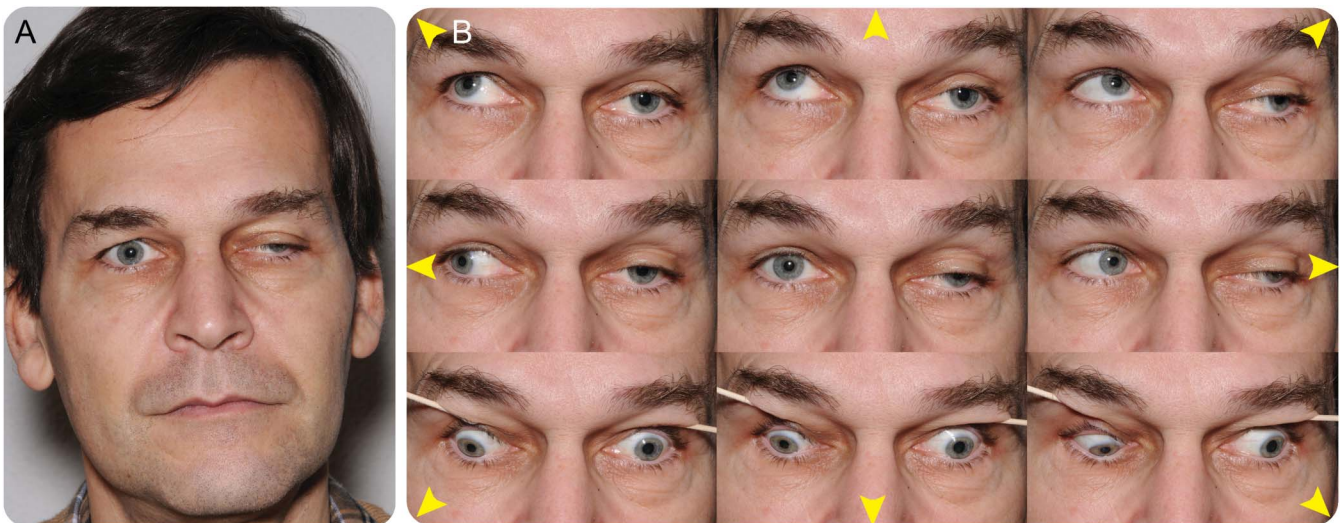
### DISCLOSURE

V. Kana, J. Petersen, K. Ikenberg, A. Chappaz, C. Gerth-Kahlert, and P. Appenzeller report no disclosures relevant to the manuscript. M. Linnebank reports grants, personal fees, and nonfinancial support from Almirall, Bayer, Biogen, Genzyme, Merck, Novartis, and Teva outside the submitted work. Go to [Neurology.org](http://Neurology.org) for full disclosures.

### REFERENCES

1. Segal BM. Neurosarcoidosis: diagnostic approaches and therapeutic strategies. *Curr Opin Neurol* 2013;26:307–313.
2. Tana C, Wegener S, Borys E, et al. Challenges in the diagnosis and treatment of neurosarcoidosis. *Ann Med* 2015;47:576–591.

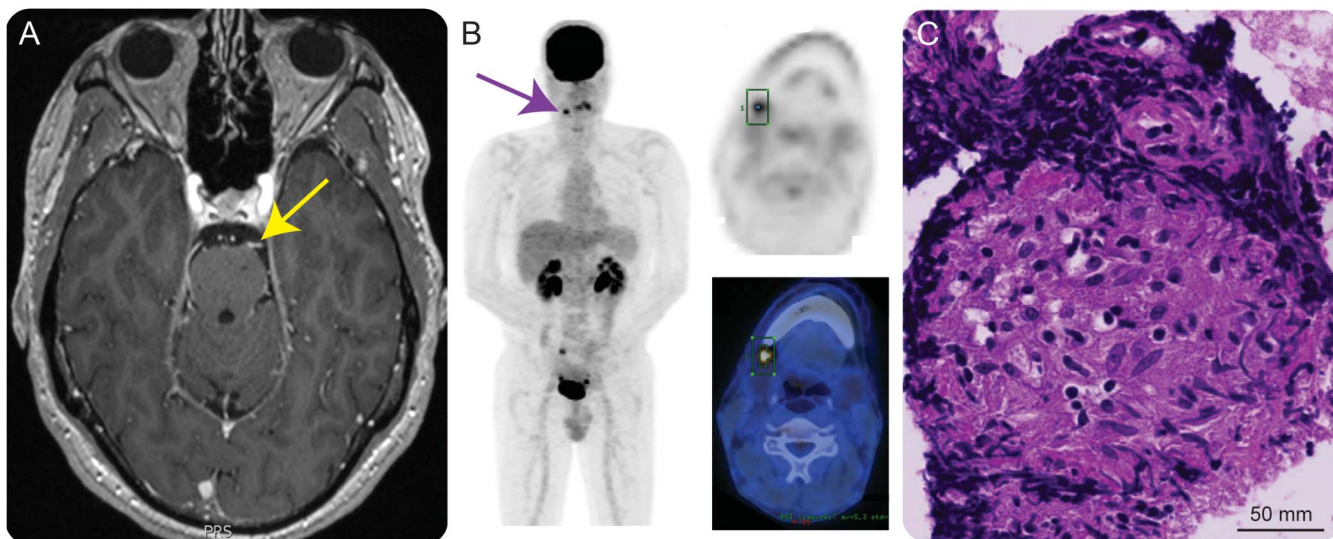
Figure 1 Oculomotor palsies



(A) Complete left third nerve palsy with (B) limited adduction, elevation, and depression of the left eye, ptosis, and mydriasis.

From the Departments of Neurology (V.K., J.A.P., M.L.), Ophthalmology (A.C., C.G.-K.), and Nuclear Medicine (P.A.), and Institute of Clinical Pathology (K.I.), University Hospital Zurich, Switzerland; Department of Oncological Sciences (V.K.), Tisch Cancer Institute and Immunology Institute, Icahn School of Medicine at Mount Sinai, New York, NY; and HELIOS Klinik Hagen-Ambrock (M.L.), Hagen, Germany.

**Figure 2** Imaging and pathology



(A) Axial T1-weighted MRI shows basal leptomeningeal contrast enhancement along the left third nerve (arrow). (B) Active lymph node (arrow) in coronal (left) and axial (right) [ $^{18}\text{F}$ ]-fluorodeoxyglucose-PET/CT containing (C) lymphadenitis with noncaseating granuloma (hematoxylin & eosin).

# Neurology®

## Teaching *NeuroImages*: Recurrent oculomotor palsies caused by neurosarcoidosis

Veronika Kana, Jens A. Petersen, Kristian Ikenberg, et al.

*Neurology* 2016;87:e31-e32

DOI 10.1212/WNL.0000000000002865

**This information is current as of July 18, 2016**

<b>Updated Information &amp; Services</b>	including high resolution figures, can be found at: <a href="http://n.neurology.org/content/87/3/e31.full">http://n.neurology.org/content/87/3/e31.full</a>
<b>Supplementary Material</b>	Supplementary material can be found at: <a href="http://n.neurology.org/content/suppl/2016/07/16/WNL.0000000000002865.DC1">http://n.neurology.org/content/suppl/2016/07/16/WNL.0000000000002865.DC1</a>
<b>References</b>	This article cites 2 articles, 0 of which you can access for free at: <a href="http://n.neurology.org/content/87/3/e31.full#ref-list-1">http://n.neurology.org/content/87/3/e31.full#ref-list-1</a>
<b>Subspecialty Collections</b>	This article, along with others on similar topics, appears in the following collection(s): <b>Autoimmune diseases</b> <a href="http://n.neurology.org/cgi/collection/autoimmune_diseases">http://n.neurology.org/cgi/collection/autoimmune_diseases</a> <b>Ocular motility</b> <a href="http://n.neurology.org/cgi/collection/ocular_motility">http://n.neurology.org/cgi/collection/ocular_motility</a>
<b>Permissions &amp; Licensing</b>	Information about reproducing this article in parts (figures, tables) or in its entirety can be found online at: <a href="http://www.neurology.org/about/about_the_journal#permissions">http://www.neurology.org/about/about_the_journal#permissions</a>
<b>Reprints</b>	Information about ordering reprints can be found online: <a href="http://n.neurology.org/subscribers/advertise">http://n.neurology.org/subscribers/advertise</a>

*Neurology*® is the official journal of the American Academy of Neurology. Published continuously since 1951, it is now a weekly with 48 issues per year. Copyright © 2016 American Academy of Neurology. All rights reserved. Print ISSN: 0028-3878. Online ISSN: 1526-632X.

