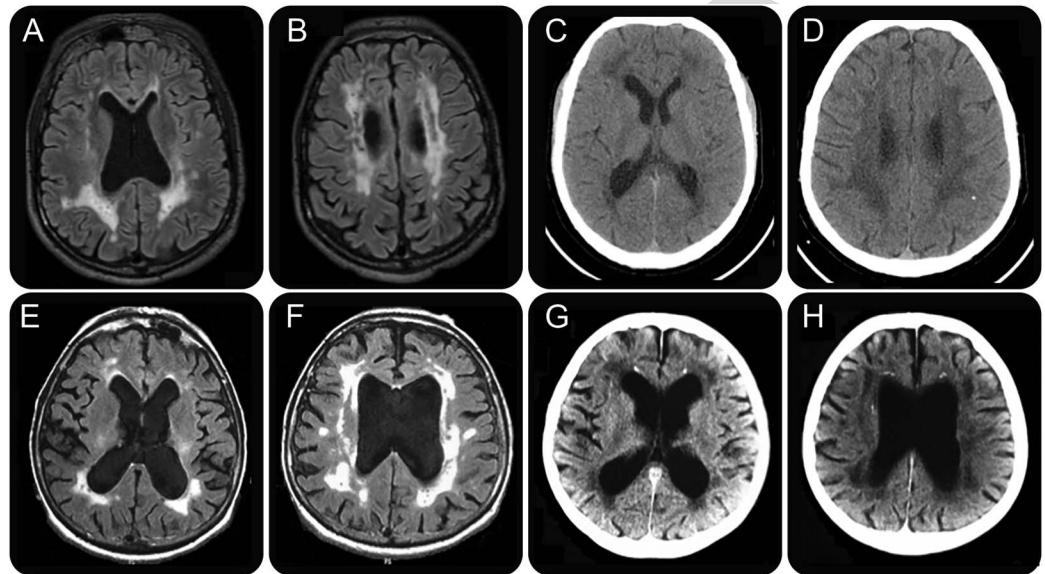


# Mystery Case: *CSF-1R* mutation is a cause of intracranial cerebral calcifications, cysts, and leukoencephalopathy

Xavier Ayrygnac, MD  
Kevin Mouzat, PhD  
Eloi Magnin, MD  
Eric Berger, MD  
Clarisse Carra-Dallière,  
MD  
Serge Lumbroso, MD,  
PhD  
Pierre Labauge, MD, PhD

Correspondence to  
Dr. Ayrygnac:  
xavier.ayrygnac@yahoo.fr

**Figure** Cerebral imaging of index patient and his mother shows multiple cystic lesions with punctate microcalcifications



Brain imaging of the index patient (A–D) and his mother (E–H): axial fluid-attenuated inversion recovery imaging (A, B and E, F) discloses periventricular white matter hyperintensities associated with multiple cystic, hypointense lesions. CT scan (C, D and G, H) shows punctate microcalcifications with periventricular (mainly frontal) and subcortical distribution.

A 37-year-old man was referred for a 1-year history of word naming difficulties and progressive executive dysfunction along with anxiety. Clinical examination showed generalized hyperreflexia and bilateral Babinski sign but was otherwise normal. His brain MRI (figure, A and B) showed extensive leukoencephalopathy with multiple small cysts within the white matter changes and no gadolinium enhancement. CT identified punctate calcifications with deep frontal and juxtacortical distribution (figure, C and D). His mother died at 63 years after a 10-year history of progressive cognitive impairment of frontal type, walking difficulties, and urinary incontinence. Her brain imaging was strikingly similar to her son's (figure, E–H).

A novel heterozygous mutation in the *CSF-1R* gene, p.Leu845Pro, was identified in the index case. Mutations in the *CSF-1R* gene have been identified

recently in the dominantly inherited hereditary diffuse leukoencephalopathy with spheroids.<sup>1</sup> The phenotypic spectrum of the disease is expanding rapidly and it has been suggested that *CSF-1R* mutations may account for up to 11% of patients with adult-onset leukodystrophy.<sup>2</sup> In line with a recent description,<sup>3</sup> our report confirms that the *CSF-1R* gene should be screened in patients with intracerebral calcifications, cysts, and leukoencephalopathy.

#### AUTHOR CONTRIBUTIONS

Dr. Ayrygnac: Study concept and design, drafting of the manuscript. Dr. Mouzat: Analysis and interpretation of the data. Dr. Magnin: Acquisition of data. Dr. Berger: Acquisition of data. Dr. Carra-Dallière: Critical revision of the manuscript for important intellectual content. Dr. Lumbroso: Analysis and interpretation of the data. Dr. Labauge: Study concept and design.

#### STUDY FUNDING

No targeted funding reported.

From the Department of Neurology (X.A., C.C.-D., P.L.), CHU Montpellier; Department of Biochemistry (K.M., S.L.), CHU Nîmes; and Department of Neurology (E.M., E.B.), CHU Besançon, France.

Go to [Neurology.org](http://Neurology.org) for full disclosures. Funding information and disclosures deemed relevant by the authors, if any, are provided at the end of the article.

## DISCLOSURE

The authors report no disclosures relevant to the manuscript. Go to [Neurology.org](http://Neurology.org) for full disclosures.

## REFERENCES

1. Rademakers R, Baker M, Nicholson AM, et al. Mutations in the colony stimulating factor 1 receptor (*CSF1R*) gene cause hereditary diffuse leukoencephalopathy with spheroids. *Nat Genet* 2011;44:200–205.
2. Guerreiro R, Kara E, Le Ber I, et al. Genetic analysis of inherited leukodystrophies: genotype-phenotype correlations in the *CSF1R* gene. *JAMA Neurol* 2013;70:875–882.
3. Karle KN, Biskup S, Schüle R, et al. De novo mutations in hereditary diffuse leukoencephalopathy with axonal spheroids (HDLS). *Neurology* 2013;81:2039–2044.

## MYSTERY CASE RESPONSES

The Mystery Case series was initiated by the *Neurology*<sup>®</sup> Resident & Fellow Section to develop the clinical reasoning skills of trainees. Residency programs, medical student preceptors, and individuals were invited to use this Mystery Case as an educational tool. Responses were solicited through a group e-mail sent to the American Academy of Neurology Consortium of Neurology Residents and Fellows and through social media. We piloted a new multiple-choice style for gathering responses, and are pleased to report that we received 725 responses, our highest to date. The vast majority of respondents (66%) had just been in practice for 1–4 years; 48% were residents/fellows, while 37% were faculty/board-certified physicians. Seventy percent resided outside the United States. A wide range of practice settings was represented.

A total of 91% of respondents correctly identified the finding of white matter hyperintensities on the patient's and mother's brain MRIs, but only 7.3% identified the more subtle but diagnostically relevant finding of multiple cystic hypointense lesions. On the patient's and mother's CT imaging, 75% identified the white matter hypodensities corresponding to the MRI hyperintensities, whereas 27% correctly identified the critical finding of cerebral calcifications.

The differential diagnosis for this type of presentation includes Labrune syndrome (leukoencephalopathy with cerebral calcifications and cysts; the final diagnosis in the actual case), Coats-plus syndrome (which has additional systemic manifestations, including retinal microangiopathy), parasitic infection, and Fahr disease (idiopathic basal ganglia calcification). Only 3% of respondents considered a diagnosis of Labrune syndrome or Coats-plus syndrome, whereas 2% considered parasitic infection and 9% considered Fahr disease. The most popular choices were cerebral autosomal dominant arteriopathy with subcortical infarcts and leukoencephalopathy (CADASIL) (72%) followed by metachromatic leukodystrophy (42%), X-linked adrenoleukodystrophy (34%), and vascular dementia (35%); whereas these are helpful to consider in the context of progressive white matter disease with a familial component, the additional findings of cerebral calcifications and cysts would not be expected with these diseases. Finally, on being asked what one laboratory test they would consider to establish their diagnosis, most respondents (53%) selected Notch3 testing, in keeping with the preferred diagnostic choice of CADASIL. However, in this case, the most appropriate choice is *CSF1R*; this was correctly identified by 10 respondents (2%). Mutations in this gene have been recently identified in presentations of Labrune syndrome, and may account for 11% of patients with adult-onset leukodystrophy.<sup>1</sup>

Aravind Ganesh, MD

*Department of Clinical Neurosciences, University of Calgary, Canada; and Centre for Prevention of Stroke & Dementia, Nuffield Department of Clinical Neurosciences, University of Oxford, UK*

## REFERENCE

1. Guerreiro R, Kara E, Le Ber I, et al. Genetic analysis of inherited leukodystrophies: genotype-phenotype correlations in the *CSF1R* gene. *JAMA Neurol* 2013;70:875–882.

# Neurology®

**Mystery Case: *CSF-1R* mutation is a cause of intracranial cerebral calcifications, cysts, and leukoencephalopathy: [RETRACTED]**

Xavier Ayrignac, Kevin Mouzat, Eloi Magnin, et al.

*Neurology* 2016;87:e262-e263

DOI 10.1212/WNL.0000000000003370

**This information is current as of November 28, 2016**

|   |   |
|---|---|
| <b>Updated Information &amp; Services</b> | including high resolution figures, can be found at:<br><a href="http://n.neurology.org/content/87/22/e262.full">http://n.neurology.org/content/87/22/e262.full</a>  |
| <b>References</b>                         | This article cites 4 articles, 1 of which you can access for free at:<br><a href="http://n.neurology.org/content/87/22/e262.full#ref-list-1">http://n.neurology.org/content/87/22/e262.full#ref-list-1</a>  |
| <b>Citations</b>                          | This article has been cited by 5 HighWire-hosted articles:<br><a href="http://n.neurology.org/content/87/22/e262.full##otherarticles">http://n.neurology.org/content/87/22/e262.full##otherarticles</a>   |
| <b>Subspecialty Collections</b>           | This article, along with others on similar topics, appears in the following collection(s):<br><b>MRI</b><br><a href="http://n.neurology.org/cgi/collection/mri">http://n.neurology.org/cgi/collection/mri</a>   |
| <b>Errata</b>                             | An erratum has been published regarding this article. Please see <a href="#">next page</a> or:<br><a href="/content/88/20/1979.full.pdf">/content/88/20/1979.full.pdf</a><br><a href="/content/89/12/1311.full.pdf">/content/89/12/1311.full.pdf</a>        |
| <b>Permissions &amp; Licensing</b>        | Information about reproducing this article in parts (figures, tables) or in its entirety can be found online at:<br><a href="http://www.neurology.org/about/about_the_journal#permissions">http://www.neurology.org/about/about_the_journal#permissions</a> |
| <b>Reprints</b>                           | Information about ordering reprints can be found online:<br><a href="http://n.neurology.org/subscribers/advertise">http://n.neurology.org/subscribers/advertise</a>   |

*Neurology*® is the official journal of the American Academy of Neurology. Published continuously since 1951, it is now a weekly with 48 issues per year. Copyright © 2016 American Academy of Neurology. All rights reserved. Print ISSN: 0028-3878. Online ISSN: 1526-632X.



**Editors' Note:** In WriteClick this week, Drs. Lynch and Houlden point out an error in the Mystery Case Responses section of "Mystery Case: *CSF-1R* mutation is a cause of intracranial cerebral calcifications, cysts, and leukoencephalopathy," in which *CSF-1R*-related leukoencephalopathy is mistaken to be the same as Labrune syndrome. Drs. Lynch and Houlden and author Ayrignac discuss the differences between the 2 disorders. A correction appears on page 1979.

—Megan Alcauskas, MD, and Robert C. Griggs, MD

#### LETTER RE: MYSTERY CASE: *CSF-1R* MUTATION IS A CAUSE OF INTRACRANIAL CEREBRAL CALCIFICATIONS, CYSTS, AND LEUKOENCEPHALOPATHY

**David S. Lynch, Henry Houlden, London:** Ayrignac et al.<sup>1</sup> presented an interesting case that highlighted the importance of *CSF-1R* in adult-onset leukoencephalopathies. However, we are concerned that the discussion by Dr. Ganesh in the Mystery Case Responses section confused 2 different diseases as the same.<sup>1</sup> This case clearly described a typical presentation of *CSF-1R*-related disease with apparent autosomal dominant inheritance. However, Dr. Ganesh described this as a case of Labrune syndrome (leukoencephalopathy with calcifications and cysts), an autosomal recessive disorder caused by mutations in *SNORD118*.<sup>2</sup> While calcifications occur in both syndromes, they are far more widespread and severe in Labrune syndrome and the imaging appearance of both conditions is distinctive. Dr. Ganesh incorrectly attributed 11% of adult-onset leukoencephalopathy to Labrune syndrome by referencing Guerreiro et al.,<sup>3</sup> who clearly referred to *CSF-1R*-related disease.

In our experience of adult-onset leukoencephalopathy, the most common causes are classic leukodystrophies, *CSF-1R*, *CADASIL*, and *AARS2* mutations. Therefore, it is not surprising that so few residents chose Labrune syndrome or Coats-plus syndrome as likely diagnoses.

1. Ayrignac X, Mouzat K, Magnin E, et al. Mystery Case: *CSF-1R* mutation is a cause of intracranial cerebral calcifications, cysts, and leukoencephalopathy. *Neurology* 2016; 87:e262–e263.

2. Jenkinson EM, Rodero MP, Kasher PR, et al. Mutations in *SNORD118* cause the cerebral microangiopathy leukoencephalopathy with calcifications and cysts. *Nat Genet* 2016; 48:1185–1192.
3. Guerreiro R, Kara E, Le Ber I, et al. Genetic analysis of inherited leukodystrophies: genotype-phenotype correlations in the *CSF1R* gene. *JAMA Neurol* 2013;70:875–882.

© 2017 American Academy of Neurology

#### AUTHOR RESPONSE: MYSTERY CASE: *CSF-1R* MUTATION IS A CAUSE OF INTRACRANIAL CEREBRAL CALCIFICATIONS, CYSTS, AND LEUKOENCEPHALOPATHY

**Xavier Ayrignac, Montpellier, France:** I thank Dr. Lynch and Prof. Houlden for the important comment on our Mystery Case.<sup>1</sup> Indeed, calcifications and cysts found in patients with *SNORD118* mutations, formerly described in Labrune syndrome, are larger than those seen in patients harboring *CSF-1R* mutations. Nevertheless, the importance of calcifications in this disorder was recently emphasized.<sup>2</sup> Notably, calcifications are small and may have a particular stepping-stone appearance in the frontal pericallosal regions.<sup>2</sup>

I agree that Labrune syndrome is rare. In our series of 154 patients with adult-onset leukoencephalopathies, only one patient had a radiologic phenotype consistent with Labrune syndrome.<sup>3</sup> The one other patient identified with leukoencephalopathy with calcifications and cysts was ultimately found to have a mutation in the *CSF-1R* gene.

1. Ayrignac X, Mouzat K, Magnin E, et al. Mystery Case: *CSF-1R* mutation is a cause of intracranial cerebral calcifications, cysts, and leukoencephalopathy. *Neurology* 2016;87:e262–e263.
2. Konno T, Broderick DF, Mezaki N, et al. Diagnostic value of brain calcifications in adult-onset leukoencephalopathy with axonal spheroids and pigmented glia. *AJNR Am J Neuroradiol* 2017;38:77–83.
3. Ayrignac X, Carra-Dalliere C, Menjot de Champfleury N, et al. Adult-onset genetic leukoencephalopathies: a MRI pattern-based approach in a comprehensive study of 154 patients. *Brain* 2015;138:284–292.

© 2017 American Academy of Neurology

#### SUMMARY AUTHOR RESPONSE: MYSTERY CASE: *CSF-1R* MUTATION IS A CAUSE OF INTRACRANIAL CEREBRAL CALCIFICATIONS, CYSTS, AND LEUKOENCEPHALOPATHY

**Aravind Ganesh, Oxford, UK:** I thank Dr. Lynch and Prof. Houlden for the response to my editorial

summary accompaniment to the Mystery Case,<sup>1</sup> and for highlighting the distinction between CSF-1R-related disease and Labrune syndrome for both myself and our readers. This is a helpful learning point I hope to carry forward.

1. Ayrignac X, Mouzat K, Magnin E, et al. Mystery Case: *CSF-1R* mutation is a cause of intracranial cerebral calcifications, cysts, and leukoencephalopathy. *Neurology* 2016; 87:e262–e263.

© 2017 American Academy of Neurology

### CORRECTION

#### **Mystery Case: *CSF-1R* mutation is a cause of intracranial cerebral calcifications, cysts, and leukoencephalopathy**

In the Mystery Case “*CSF-1R* mutation is a cause of intracranial cerebral calcifications, cysts, and leukoencephalopathy” by X. Ayrignac et al.,<sup>1</sup> there are errors related to the description of diseases within the “Mystery Case Responses.” The case described a typical presentation of *CSF-1R*-related disease rather than a case of Labrune syndrome and should have been written as such. In addition, 11% of adult-onset leukoencephalopathy should have been attributed to *CSF-1R*-related disease rather than Labrune syndrome.<sup>2</sup> The “Mystery Case Responses” author regrets the errors.

### REFERENCES

1. Ayrignac X, Mouzat K, Magnin E, et al. Mystery Case: *CSF-1R* mutation is a cause of intracranial cerebral calcifications, cysts, and leukoencephalopathy. *Neurology* 2016;87:e262–e263.
2. Guerreiro R, Kara E, Le Ber I, et al. Genetic analysis of inherited leukodystrophies: genotype-phenotype correlations in the CSF1R gene. *JAMA Neurol* 2013;70:875–882.

---

Author disclosures are available upon request ([journal@neurology.org](mailto:journal@neurology.org)).

**Editors' Note:** In “Long-term cerebral white and gray matter changes after preeclampsia,” the authors found that preeclampsia was associated with chronic temporal lobe white matter changes and reduced cortical volume in young women; the changes were consistent with persistent inflammation. Dr. Culebras proposes that sleep apnea may be a contributing factor as pregnancy increases the risk of sleep apnea, which leads to inflammation and vascular morbidities, all of which may persist after pregnancy. Authors Siepman et al. note that recent research shows an increased risk of stroke in patients with obstructive sleep apnea, possibly facilitated by intermittent hypoxia and vascular dysregulation. These mechanisms may relate to the authors' findings given the autonomic neurovascular dysfunction caused by preeclampsia. In “The autism ‘epidemic’: Ethical, legal, and social issues in a developmental spectrum disorder,” the authors emphasized the importance of early screening and diagnosis of autism spectrum disorder (ASD). Machado et al. recommend assessing anatomic brain connectivity using the diffusion-weighted MRI technique and functional brain connectivity using EEG coherence calculations as part of the ASD diagnostic workup. Authors Graf et al. caution against this practice, citing that many studies fail to consistently implicate a specific neural network responsible for autism. The authors conclude that techniques such as those described by Machado et al. have a role in ASD research, but not yet in its routine clinical diagnosis.

—Megan Alcauskas, MD, and Steven Galetta, MD

#### LETTER RE: LONG-TERM CEREBRAL WHITE AND GRAY MATTER CHANGES AFTER PREECLAMPSIA

**Antonio Culebras, Fayetteville, NY:** The article by Siepman et al.<sup>1</sup> identified long-term cerebral white matter changes and reduced cortical volume, presumably of vascular origin, in young women after pregnancy complicated by preeclampsia. The authors invoked persistent inflammation as the putative agent. Sleep apnea may be a link among pregnancy, preeclampsia, and cerebrovascular disease.

During the third trimester of pregnancy, the growth of the fetus restricts sleep respiratory function,

particularly in obese women.<sup>2</sup> Ten percent of pregnant women have sleep apnea,<sup>2</sup> a condition that raises blood pressure, increases the level of inflammation, and leads to preeclampsia.<sup>3</sup> Sleep apnea may persist after pregnancy, sustaining the post-preeclampsia vascular risk.

In a study conducted in China, 29,961 women with sleep apnea had a 19% higher risk of stroke and those in gestational age had the highest risk.<sup>4</sup> In an editorial,<sup>5</sup> I pointed out that pregnant women with sleep apnea develop a perfect storm of comorbid vascular events, featuring repeated hypoxia damaging the endothelium, release of placental proinflammatory factors, gestational hypertension, and preeclampsia. Sleep apnea remains underdiagnosed and obesity is expanding. A heightened level of awareness of sleep apnea is needed to take proactive preventive measures because sleep apnea is modifiable.

1. Siepman T, Boardman H, Bilderbeck A, et al. Long-term cerebral white and gray matter changes after preeclampsia. *Neurology* 2017;88:1256–1264.
2. Pien GW, Fife D, Pack AI, Nkwuo JE, Schwab RJ. Changes in symptoms of sleep-disordered breathing during pregnancy. *Sleep* 2005;28:1299–1305.
3. Bourjeily G, Ankner G, Mohsenin V. Sleep-disordered breathing in pregnancy. *Clin Chest Med* 2011;32:175–189.
4. Chang CC, Chuang HC, Lin CL, et al. High incidence of stroke in young women with sleep apnea syndrome. *Sleep Med* 2014;15:410–414.
5. Culebras A. Sleep apnea and stroke in young women: the many faces of the disorder. *Sleep Med* 2014;15:377–378.

© 2017 American Academy of Neurology

#### AUTHOR RESPONSE: LONG-TERM CEREBRAL WHITE AND GRAY MATTER CHANGES AFTER PREECLAMPSIA

**Timo Siepman, Henry Boardman, Amy Bilderbeck, Ludovica Griffanti, Yvonne Kenworthy, Oxford, United Kingdom; Charlotte Zwager, Groningen, Netherlands; David McKean, Jane Francis, Stefan Neubauer, Grace Z. Yu, Adam J. Lewandowski, Yrsa Bergmann Sverrisdottir, Paul Leeson, Oxford, United Kingdom:** We thank Dr. Culebras for the comment on our article.<sup>1</sup> Sleep apnea might be among the pathophysiologic pathways linking preeclampsia with increased risk of cerebrovascular disease in previously preeclamptic women. In fact, research recently

focused on the role of sleep apnea in the etiopathogenesis of cerebrovascular and cardiovascular disease and demonstrated an increased stroke risk in patients with obstructive sleep apnea (OSA).<sup>2,3</sup> Intermittent hypoxia with consecutive vascular dysregulation has been identified as a possible mechanism whereby OSA increases risk of stroke. This might be relevant to previously preeclamptic mothers in whom autonomic neurovascular dysfunction, inter alia mediated by functional changes to the sympathetic nervous system, was also demonstrated.<sup>4</sup> It remains to be answered whether this similarity among pathologies indeed points to a causative link between preeclampsia and cerebrovascular disease.

1. Siepmann T, Boardman H, Bilderbeck A, et al. Long-term cerebral white and gray matter changes after preeclampsia. *Neurology* 2017;88:1256–1264.
2. Beaudin AE, Waltz X, Hanly PJ, Poulin MJ. Impact of obstructive sleep apnoea and intermittent hypoxia on cardiovascular and cerebrovascular regulation. *Exp Physiol* 2017;102:743–763.
3. Cho ER, Kim H, Seo HS, et al. Obstructive sleep apnea as a risk factor for silent cerebral infarction. *J Sleep Res* 2013;22:452–458.
4. Stennett AK, Khalil RA. Neurovascular mechanisms of hypertension in pregnancy. *Curr Neurovasc Res* 2006;3:131–148.

© 2017 American Academy of Neurology

#### LETTER RE: THE AUTISM “EPIDEMIC”: ETHICAL, LEGAL, AND SOCIAL ISSUES IN A DEVELOPMENTAL SPECTRUM DISORDER

**Calixto Machado, Mario Estevez, Rafael Rodriguez, Havana, Cuba; Gerry Leisman, Zichron Ya’acov, Haifa, Israel:** Graf et al.<sup>1</sup> wrote an interesting review on autism spectrum disorder (ASD), emphasizing the term “autism epidemic,” supported by an editorial.<sup>2</sup> Among other factors, increasing ASD diagnoses can be attributed to broader diagnostic criteria and the recognition of ASD existence differentiated from other neurodevelopmental diseases.<sup>2–4</sup> One important issue, defended by the authors, is early screening and diagnosis with emphasis on the evolving practice of genetic testing for ASD.<sup>1</sup>

Brain connectivity assessment, both anatomic and functional, is fundamental to diagnose and follow-up with intervention in ASD.<sup>3–5</sup> Many studies assess either anatomic or functional measures, but literature regarding the correlation between both types of connectivity in autism is lacking. We studied children with autism, determining the relationship between anatomic and functional connectivity, with consideration of short-range and long-range brain networks.<sup>4</sup> Anatomic measures

were assessed by the diffusion-weighted MRI technique and functional measures by EEG coherence calculation. We found correlations among anatomic and functional connectivity, and concluded that an impaired audiovisual interaction in the right brain hemisphere might be the cause.<sup>4</sup> The study of brain connectivity should be a tool to assess ASD in present and future research.<sup>3,4</sup>

1. Graf WD, Miller G, Epstein LG, Rapin I. The autism “epidemic”: ethical, legal, and social issues in a developmental spectrum disorder. *Neurology* 2017;88:1371–1380.
2. Jeste SS, Schor NF. Autism today: have we put the cart before the horse? *Neurology* 2017;88:1303–1304.
3. Machado C, Estevez M, Leisman G, et al. QEEG spectral and coherence assessment of autistic children in three different experimental conditions. *J Autism Dev Disord* 2015;45:406–424.
4. Machado C, Rodriguez R, Estevez M, et al. Anatomic and functional connectivity relationship in autistic children during three different experimental conditions. *Brain Connect* 2015;5:487–496.
5. Chen S, Xing Y, Kang J. Latent and abnormal functional connectivity circuits in autism spectrum disorder *Front Neurosci* 2017;11:125.

© 2017 American Academy of Neurology

#### AUTHOR RESPONSE: THE AUTISM “EPIDEMIC”: ETHICAL, LEGAL, AND SOCIAL ISSUES IN A DEVELOPMENTAL SPECTRUM DISORDER

**William D. Graf, Farmington; Geoffrey Miller, New Haven, CT; Leon G. Epstein, Chicago; Isabelle Rapin, New York:** We thank Machado et al. for the comments on our review,<sup>1</sup> and for the observations of abnormal anatomic and functional connectivity using diffusion-weighted MRI (DW-MRI). Innumerable studies have compared patients with autism spectrum disorders (ASD) and nonaffected controls at rest or while performing particular tasks, most often in small selected subject samples. For example, studies linked autism with the retino-collicular magnocellular visual pathways that project via the pulvinar to the amygdala, occipital V1, and multiple other areas, including the dorsal occipitoparietal/midtemporal streams, which participate with the frontal eye fields in processing spatial attention, moving targets, and dynamic facial expression (with inputs from the amygdala and other limbic pathways).<sup>2</sup> However, no results consistently demonstrated specific neural networks that are uniquely pathognomonic of autism in the brain despite the fact that broad networks were linked with deficient social cognition in autism.<sup>3</sup> Complex behaviors, like ASD, do not have a single endophenotype linked to one discrete neocortical location.<sup>4</sup> The critical need for more research in autism should be balanced by caution about generalizing interpretations of neuroimaging findings that suggest the dysregulation of specific neural pathways. At present, DW-MRI and similar techniques, such as diffusion compartment imaging, are

considered beneficial for research but not for routine clinical diagnostics.

1. Graf WD, Miller G, Epstein LG, Rapin I. The autism “epidemic”: ethical, legal, and social issues in a developmental spectrum disorder. *Neurology* 2017;88:1371–1380.
2. Bernstein M, Yovel G. Two neural pathways of face processing: a critical evaluation of current models. *Neurosci Biobehav Rev* 2015;55:536–546.
3. Patriquin MA, DeRamus T, Libero LE, Laird A, Kana RK. Neuroanatomical and neurofunctional markers of social cognition in autism spectrum disorder. *Hum Brain Mapp* 2016;37:3957–3978.
4. Karmiloff-Smith A. Development itself is the key to understanding developmental disorders. *Trends Cogn Sci* 1998;2:389–398.

© 2017 American Academy of Neurology

### RETRACTION

#### **Mystery Case: *CSF-IR* mutation is a cause of intracranial cerebral calcifications, cysts, and leukoencephalopathy**

The authors retract the article “Mystery Case: *CSF-IR* mutation is a cause of intracranial cerebral calcifications, cysts, and leukoencephalopathy” by X. Ayrignac et al., which appeared in the Resident & Fellow Section in volume 86, page e262, because 4 of the figures were previously published in another journal (*European Neurology* 2012;67:151–153).<sup>2</sup> The earlier article was not cited and there were 3 common authors (Magnin, Berger, and Labauge) on the papers. In addition to the duplicate publication, 1 image attributed to the index case in this article was attributed to his mother in the earlier article and 3 images attributed to his mother in this article were attributed to the index case in the earlier article.

When asked for an explanation, the corresponding author, X. Ayrignac, replied that he was unaware of the earlier paper, but agreed to represent all authors in retracting the paper. Coauthors Lumbroso, Mouzat, and Carra responded that they agreed with the retraction and were also unaware of the earlier publication and thus had no explanation for the mix-up of the figures or duplication publication. Coauthor Magnin, one of the overlapping authors, agreed with the retraction and stated that he did not know how the mix-up of the figures occurred and that he missed catching it at the manuscript review. Coauthor Labauge (an overlapping author) also agreed to the retraction and stated to the corresponding author that when he submitted the earlier paper, he did not realize the figures were incorrectly attributed and did not remember the first paper when he revised the Ayrignac et al. paper. Coauthor Berger (an overlapping author) was not available for a written reply, but the corresponding author stated that this author had verbally agreed to the retraction. None of the authors could explain the mix-up of the figures or the duplicate publication.

The corresponding author, Ayrignac, admits that this publication is a duplicate publication and thus should not have been published even with the identification of a mutation in the *CSFIR* gene. With regard to the mix-up of the figures, Ayrignac believes there was a mistake in the previous paper and that the images published in *Neurology* were correctly attributed to the index case and his mother.

### REFERENCES

1. Ayrignac X, Mouzat K, Magnin E, et al. Mystery Case: *CSF-IR* mutation is a cause of intracranial cerebral calcifications, cysts, and leukoencephalopathy. *Neurology* 2016;87:e262–e263.
2. Labauge P, Berger E, Magnin E, Rumbach L, Mine M, Renard D. A new form of leukoencephalopathy with calcifications and cysts with nonrecessive inheritance and absence of gadolinium enhancement. *Eur Neurol* 2012;67:151–153.

---

Author disclosures are available upon request ([journal@neurology.org](mailto:journal@neurology.org)).