

Teaching Video NeuroImages: Primary writing tremor

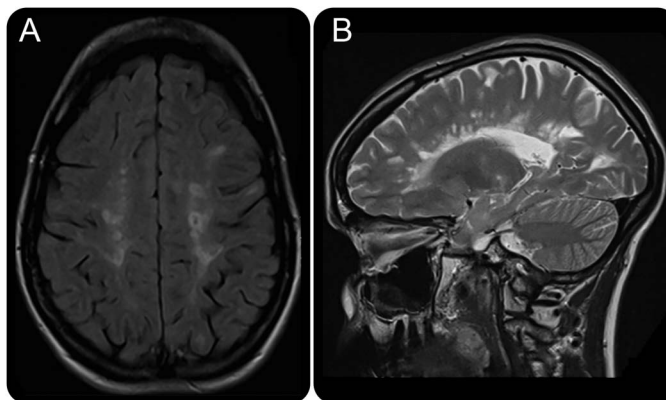
Lessons from a patient with multiple sclerosis



Dearbhla M. Kelly,
MBBCh BAO, MSc,
MRCPI
Eoin M. Kelleher,
MBBCh BAO
Aileen O'Shea, MBBCh
BAO
Brian Sweeney, MBBCh
BAO, FRCP

Correspondence to
D.M. Kelly:
dearbhlakelly2@gmail.com

Figure MRI brain



Axial fluid-attenuated inversion recovery (A) and sagittal T2 (B) images demonstrate hyperintense lesions in the pericallosal white matter suggestive of demyelination. Further lesions were noted in the left midbrain, right middle cerebellar peduncle, and left cerebellar hemispheres. No postcontrast enhancement was demonstrated (T1 postcontrast not shown).

A 30-year-old woman with recurring optic neuritis presented with tremor affecting her right hand when writing only (video at Neurology.org). An MRI brain (figure) revealed lesions in the left midbrain, right middle cerebellar peduncle, and left cerebellar hemisphere.

Primary writing tremor (PWT) is a task-specific tremor that occurs with writing. There is debate about whether it represents essential tremor, dystonia associated with writer's cramp, or a separate entity.¹

A combination of cerebellar dysfunction and dystonia underlies most multiple sclerosis upper limb tremors.² Similar mechanisms in our patient may contribute to PWT with injury within the cerebello-pallido-thalamo-cortical tract.

AUTHOR CONTRIBUTIONS

Dr. Kelly: acquisition of data, interpretation of data, drafting/revising the manuscript for content. Dr. Kelleher: drafting/revising the manuscript for content. Dr. O'Shea: interpretation of data, revising the manuscript for content. Dr. Sweeney: interpretation of data, drafting/revising the manuscript for content, study supervision.

STUDY FUNDING

No targeted funding reported.

DISCLOSURE

The authors report no disclosures relevant to the manuscript. Go to Neurology.org for full disclosures.

REFERENCES

- Hai C, Yu-ping W, Hua W, Ying S. Advances in primary writing tremor. *Parkinsonism Relat Disord* 2010;16:561–565.
- Van der Walt A, Buzzard K, Sung S, et al. The occurrence of dystonia in upper-limb multiple sclerosis tremor. *Mult Scler* 2015;21:1847–1855.

Supplemental data
at Neurology.org

Download teaching slides:
Neurology.org

From the Department of Neurology (D.M.K., B.S.), Cork University Hospital and University College Cork; and Royal College of Surgeons (E.M.K., A.O.), Dublin, Ireland.

Neurology®

Teaching Video *NeuroImages*: Primary writing tremor: Lessons from a patient with multiple sclerosis

Dearbhla M. Kelly, Eoin M. Kelleher, Aileen O'Shea, et al.

Neurology 2016;87:e131

DOI 10.1212/WNL.0000000000003120

This information is current as of September 19, 2016

Updated Information & Services	including high resolution figures, can be found at: http://n.neurology.org/content/87/12/e131.full
Supplementary Material	Supplementary material can be found at: http://n.neurology.org/content/suppl/2016/09/19/WNL.0000000000003120.DC1 http://n.neurology.org/content/suppl/2016/09/19/WNL.0000000000003120.DC2
References	This article cites 2 articles, 0 of which you can access for free at: http://n.neurology.org/content/87/12/e131.full#ref-list-1
Subspecialty Collections	This article, along with others on similar topics, appears in the following collection(s): Dystonia http://n.neurology.org/cgi/collection/dystonia Multiple sclerosis http://n.neurology.org/cgi/collection/multiple_sclerosis Tremor http://n.neurology.org/cgi/collection/tremor
Permissions & Licensing	Information about reproducing this article in parts (figures, tables) or in its entirety can be found online at: http://www.neurology.org/about/about_the_journal#permissions
Reprints	Information about ordering reprints can be found online: http://n.neurology.org/subscribers/advertise

Neurology® is the official journal of the American Academy of Neurology. Published continuously since 1951, it is now a weekly with 48 issues per year. Copyright © 2016 American Academy of Neurology. All rights reserved. Print ISSN: 0028-3878. Online ISSN: 1526-632X.

