

# Clinical Reasoning:

## A 57-year-old man with subacute gait difficulty and hand tremor



Vimal K. Paliwal, DM  
Ravi Uniyal, DM  
Zafar Neyaz, MD  
Vikas Agarwal, DM

Correspondence to  
Dr. Paliwal:  
dr\_vimalkaliwal@rediffmail.com

### SECTION 1

A 57-year-old man presented with progressive difficulty in walking for 2 weeks, resting hand tremors for 1 week, and low-volume speech for 2 days. Initially, he had difficulty in initiation of walking. Soon, he developed short-stepped gait with history of en bloc falling forward. Within 2 weeks of the onset of illness, he became bed-bound. While in bed, he remained very stiff and could not sit or turn sides by himself. He also had tremors in his upper limbs on action. His speech volume was reduced, but he always remained coherent. There was no bowel or bladder involvement, flexor spasms, or zosteresthesia. The patient had been treated for ankylosing spondylitis (AS) with nonsteroidal anti-inflammatory drugs for 4 years because of low back pain, progressively increasing stooped-forward gait, and sclerosis of sacroiliac joints on X-ray. On examination, he had a masklike face. His blink

rate was 1 to 4 blinks per minute. His Mini-Mental State Examination score was 29 of 30. He had hypophonic monotonous speech. His eye movements showed slow saccades and broken pursuit movements. Examination of motor system revealed normal muscle bulk, cogwheel rigidity of the upper limbs, and lead-pipe rigidity in the legs. His strength could not be tested because of profound muscle stiffness. Coarse action tremors were noticed in both hands. The patient had fixed-flexion deformity at the hip joint. Deep tendon jerks could not be elicited because of profound muscle rigidity. Plantar responses and abdominal reflexes also could not be elicited.

### Questions for consideration:

1. What is the differential diagnosis of subacute parkinsonism?
2. Is the history of AS related to parkinsonism?

[GO TO SECTION 2](#)

### Supplemental data at Neurology.org

From the Departments of Neurology (V.K.P.), Radiology (Z.N.), and Immunology (V.A.), SGPGIMS; and Department of Neurology (R.U.), King George Medical University, Lucknow, UP, India.

Go to Neurology.org for full disclosures. Funding information and disclosures deemed relevant by the authors, if any, are provided at the end of the article.

## SECTION 2

The patient presented with subacute parkinsonism. Subacute parkinsonism is most commonly drug-induced (dopamine receptor blocker). Other causes include encephalitis such as Japanese encephalitis and West Nile encephalitis; poisoning with methanol, 1-methyl-4-phenyl-1,2,3,6-tetrahydropyridine, ethylene oxide, or organophosphates; major alcohol withdrawal; and pontine-extrapontine myelinolysis (occurring after rapid correction of hyponatremia). Neuroleptic malignant syndrome and catatonia are psychiatric illnesses that manifest with marked rigidity and tremors. Rarely, Wilson disease can manifest in adults with acute dystonia and parkinsonism.

In our patient, there was no history of exposure to any offending drug or toxin, encephalitis-like illness, or any psychiatric illness. He was not alcoholic. He never had hyponatremia, and his slit-lamp examination did not reveal Kayser-Fleischer ring.

AS belongs to the group of seronegative spondyloarthropathies that also include psoriatic arthritis, reactive arthritis, and enteropathic arthropathy. None

of these conditions is known to present with parkinsonism. Our patient was treated for AS. However, despite having a supportive clinical picture, his human leukocyte antigen (HLA)-B27 was negative. More than 90% patients with AS have the HLA-B27 genotype. There are certain mimics of seronegative spondyloarthropathy. They include polymyalgia rheumatica, fibromyalgia, severe osteomalacia, diffuse idiopathic skeletal hyperostosis, hypoparathyroidism (HP), and destructive spondyloarthropathy. Among these conditions, HP may rarely present with acute parkinsonism.<sup>1</sup>

During his hospital stay, the patient developed intermittent, spontaneous, painless abnormal posturing of fingers and thumb of both hands at rest (video 1 at [Neurology.org](http://Neurology.org)).

### Questions for consideration:

1. How is this information of intermittent, spontaneous, abnormal posturing of fingers/thumbs helpful?
2. What investigations would you like to perform?

**GO TO SECTION 3**

### SECTION 3

During the hospital stay, the patient developed intermittent, spontaneous posturing of hands (carpal spasms). Carpopedal spasms are clinical indicators of hypocalcemia. Other important clinical signs for hypocalcemia include Chvostek and Trousseau signs.<sup>1</sup> Both of these signs were also present in the patient. The patient needed tests to confirm hypocalcemia and to evaluate the cause of hypocalcemia. His blood tests revealed the following: hemoglobin, 9.3 g/dL (13.3–16.2 g/dL); total calcium, 6.6 mg/dL (8.7–10.2 mg/dL); ionized calcium, 3.6 mg/dL (4.5–5.3 mg/dL); phosphorus, 7.7 mg/dL (2.5–4.3 mg/dL); alkaline phosphatase, 265 U/L (33–96 U/L); magnesium, 2.3 mg/dL (1.5–4.3 mg/dL); serum 25-hydroxy-vitamin D, 6.5 ng/mL (20–100 ng/mL); parathyroid hormone (PTH), <10 pg/mL (10–65 pg/mL); creatine phosphokinase (CPK), 4854 U/L (51–294 U/L); 24-hour urinary calcium, 169 mg (100–300 mg; volume, 3,700 mL); no urinary myoglobin; and normal renal/liver/thyroid functions, vasculitis profile, fasting and postprandial

blood glucose, serum cortisol, and serum adrenocorticotropic hormone levels. EMG revealed spontaneous motor unit activity suggestive of tetany. There was no evidence of myopathy.

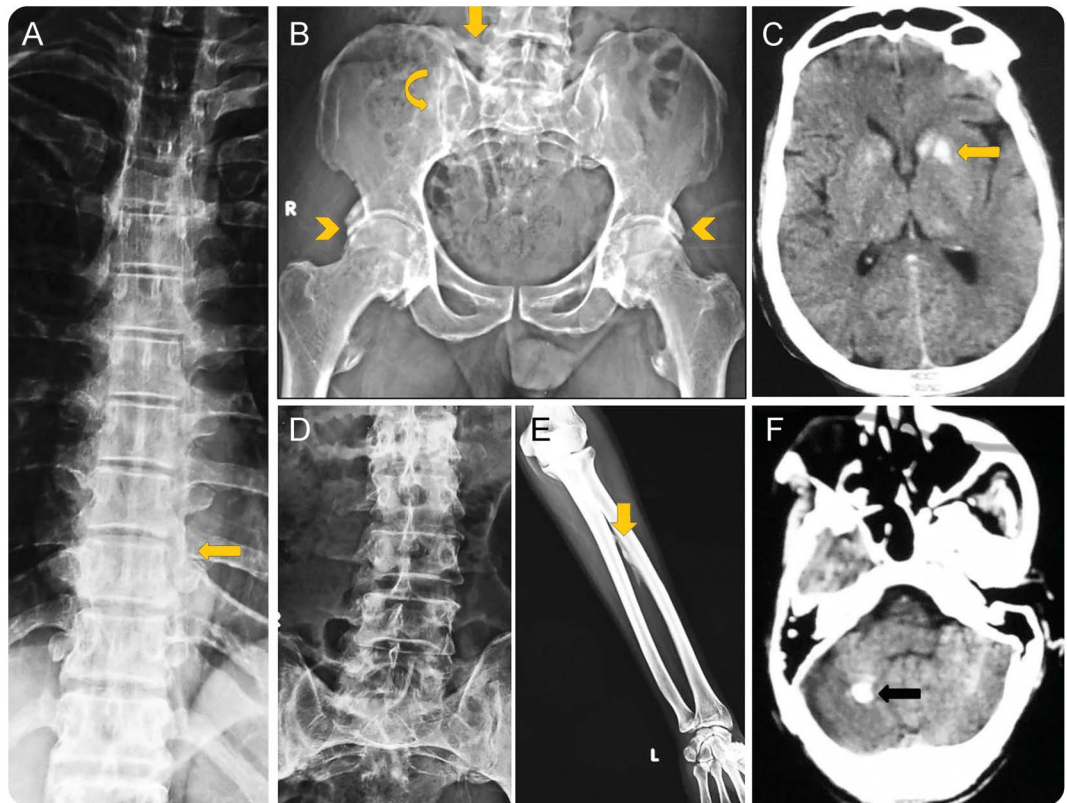
An X-ray of the patient's dorsal/lumbar spine showed lateral marginal osteophytes; however, there was no calcification of anterior or posterior longitudinal ligaments. An X-ray of the pelvis revealed calcification of iliolumbar ligaments, sclerosis around the sacroiliac joints, and calcification of acetabular margin. An X-ray of the forearm revealed calcification of interosseous membrane. Extensive vascular calcification was also noted. His bone mineral density was normal. A cranial CT scan showed calcification of the bilateral basal ganglia and right dentate nuclei (figure).

#### Questions for consideration:

1. What is the final diagnosis?
2. How would you treat this patient?
3. How can AS be differentiated from spondyloarthritis secondary to HP?

**GO TO SECTION 4**

**Figure** Figure collage showing radiologic features of hypoparathyroidism



Plain X-ray shows lateral-marginal osteophytes in the thoracic spine (A) without syndesmophytes in the lumbar spine (D). Pelvis x-ray (B) shows ossification of the iliolumbar ligament (arrow) and margins of the acetabulum (arrowheads), as well as sacroiliac joint sclerosis (curved arrow). The interosseous membrane in the forearm is also ossified (E). CT scan of the head shows calcification of the basal ganglia (C) and right dentate (F).

## SECTION 4

Because of the presence of tetany, hypocalcemia, reduced PTH, and basal ganglia calcification, the patient was diagnosed with HP.

The patient received oral elemental calcium (2 g/d) with calcitriol 0.75 µg/d. Over 1 week, the tremors and tetany improved. Over 2 months, the patient started walking independently (video 2). His muscle rigidity improved, and all deep tendon jerks were normally elicitable. His calcium/vitamin D supplementation was monitored by measurement of his 24-hour urinary calcium levels. His serum calcium, CPK, and alkaline phosphatase levels normalized.

Longstanding idiopathic HP may produce spondyloarthropathy-like changes in up to 40% of patients that may resemble AS.<sup>2</sup> However, certain radiologic features may differentiate HP from AS (table e-1). HP involves the lower one-third of the sacroiliac joint and produces calcification of iliolumbar ligament, whereas AS usually affects the upper part of the sacroiliac joint.<sup>3</sup> Exuberant calcification of hip joint (without erosions) is seen in HP with preserved joint space of sacroiliac/hip joints (figure). Syndesmophytes are more common in the dorsal spine compared with the lumbosacral spine in AS.<sup>3</sup> Calcification of pelvic ligaments, ligaments around hip joints, interosseous ligaments, and other organs or systems such as the basal ganglia is a feature of HP.<sup>3</sup> Differentiating AS from HP is important because treatment of AS with bisphosphonates may accentuate the hypocalcemia seen in HP.

**DISCUSSION** PTH is the primary regulator of extracellular calcium levels. PTH acts on bone, kidneys, and gastrointestinal tract to increase extracellular calcium. Biochemically, HP is characterized by hypocalcemia, hyperphosphatemia, and low PTH levels. HP is often produced iatrogenically by surgical removal or irradiation of parathyroid glands. However, autoantibodies against calcium-sensing receptors and autoimmune polyendocrinopathy, hereditary type (idiopathic), can also produce HP.<sup>1</sup> Clinical features of HP are primarily secondary to hypocalcemia such as tetany, muscle weakness, and seizures. Acute disabling parkinsonism, reversible neuropathy, and myopathy are rare manifestations of HP.<sup>4,5</sup>

Basal ganglia calcification is seen in 0.3% of general population on cranial CT scans.<sup>6</sup> When the intracranial calcification involves the globus pallidus, caudate-putamen, and cerebellum (striatal-pallidal-dentate), the condition is called Fahr syndrome.<sup>6</sup> In addition to the idiopathic and familial causes, Fahr syndrome could be caused by congenital infections, HP, and pseudo-HP. The mechanism of intracranial calcification in HP is not known. It is postulated that

chronic changes in the intracranial calcium/phosphate concentrations produce calcification.<sup>6</sup> The parkinsonism secondary to striatal calcification is usually nonresponsive to levodopa treatment.<sup>7</sup> The mechanism of parkinsonism in HP is also not clear. The parkinsonism in HP occurs regardless of intracranial calcifications, hypocalcemia, or basal ganglia ischemia (thought to be due to vascular calcification) but improves with calcium supplementation in those with hypocalcemia. Therefore, parkinsonism in HP could be multifactorial.

HP-induced myopathy has also been described. Our patient had no evidence of myopathy on EMG. Hypocalcemia-induced excessive muscle activity might have produced elevated CPK in our patient that improved with normocalcemia.

HP may produce acute parkinsonism and chronic spondyloarthropathy similar to AS, and their combination in a given patient may be unique to HP. Distribution of calcifications on plain X-rays of the spine and pelvis may suggest HP in patients with chronic spondyloarthropathy.

## AUTHOR CONTRIBUTIONS

V.K.P. provided the concept and drafting of manuscript. R.U. provided the acquisition and analysis of clinical and electronic data. Z.N. contributed to the acquisition and analysis of radiologic data and drafting of manuscript. V.A. wrote the figure legends and revised the manuscript.

## STUDY FUNDING

No targeted funding reported.

## DISCLOSURE

The authors report no disclosures relevant to the manuscript. Go to [Neurology.org](http://Neurology.org) for full disclosures.

## REFERENCES

1. Potts TJ, Juppner H. Disorders of the parathyroid gland and calcium homeostasis. In: Longo DL, AS Fauci, Kasper DL, Hauser SL, Jameson JL, Loscalzo J, eds. *Harrison's Principles of Internal Medicine*, 18th ed. New York, NY: McGraw-Hill; 2011:3096.
2. Goswami R, Ray D, Sharmat R, et al. Presence of spondyloarthropathy and its clinical profile in patients with hypoparathyroidism. *Clin Endocrinol* 2008;68:258–263.
3. Azad KAK, Hossain MZ, Hussain T, Ahmad J, Abdullah MS, Islam MS. Skeletal manifestations of hypoparathyroidism and spondyloarthropathic features in hypoparathyroidism. *J Dhaka Med Coll* 2013;22:72–76.
4. Walters RO. Idiopathic hypoparathyroidism with extrapyramidal and myopathic features. *Arch Dis Child* 1979;54:236–238.
5. Goswami R, Bhatia M, Goyal R, Kochupillai N. Reversible peripheral neuropathy in idiopathic hypoparathyroidism. *Acta Neurol Scand* 2002;105:128–131.
6. Verulashvili IV, Glonti LSh, Miminoshvili DK, Maniia MN, Mdivani KS. Basal ganglia calcification: clinical manifestations and diagnostic evaluation. *Georgian Med News* 2006; 140:39–43.
7. Klawans HL, Lupton M, Simon L. Calcification of the basal ganglia as a cause of levodopa-resistant parkinsonism. *Neurology* 1976;26:221–225.

# Neurology®

## Clinical Reasoning: A 57-year-old man with subacute gait difficulty and hand tremor

Vimal K. Paliwal, Ravi Uniyal, Zafar Neyaz, et al.

*Neurology* 2016;87:e110-e113

DOI 10.1212/WNL.0000000000003102

**This information is current as of September 12, 2016**

<b>Updated Information &amp; Services</b>	including high resolution figures, can be found at: <a href="http://n.neurology.org/content/87/11/e110.full">http://n.neurology.org/content/87/11/e110.full</a>
<b>Supplementary Material</b>	Supplementary material can be found at: <a href="http://n.neurology.org/content/suppl/2016/09/12/WNL.0000000000003102.DC1">http://n.neurology.org/content/suppl/2016/09/12/WNL.0000000000003102.DC1</a> <a href="http://n.neurology.org/content/suppl/2016/09/12/WNL.0000000000003102.DC2">http://n.neurology.org/content/suppl/2016/09/12/WNL.0000000000003102.DC2</a>
<b>References</b>	This article cites 6 articles, 2 of which you can access for free at: <a href="http://n.neurology.org/content/87/11/e110.full#ref-list-1">http://n.neurology.org/content/87/11/e110.full#ref-list-1</a>
<b>Subspecialty Collections</b>	This article, along with others on similar topics, appears in the following collection(s): <b>Electrolyte</b> <a href="http://n.neurology.org/cgi/collection/electrolyte">http://n.neurology.org/cgi/collection/electrolyte</a> <b>Endocrine</b> <a href="http://n.neurology.org/cgi/collection/endocrine">http://n.neurology.org/cgi/collection/endocrine</a> <b>Neuroendocrinology</b> <a href="http://n.neurology.org/cgi/collection/neuroendocrinology">http://n.neurology.org/cgi/collection/neuroendocrinology</a> <b>Parkinson's disease/Parkinsonism</b> <a href="http://n.neurology.org/cgi/collection/parkinsons_disease_parkinsonism">http://n.neurology.org/cgi/collection/parkinsons_disease_parkinsonism</a> <b>Tremor</b> <a href="http://n.neurology.org/cgi/collection/tremor">http://n.neurology.org/cgi/collection/tremor</a>
<b>Permissions &amp; Licensing</b>	Information about reproducing this article in parts (figures, tables) or in its entirety can be found online at: <a href="http://www.neurology.org/about/about_the_journal#permissions">http://www.neurology.org/about/about_the_journal#permissions</a>
<b>Reprints</b>	Information about ordering reprints can be found online: <a href="http://n.neurology.org/subscribers/advertise">http://n.neurology.org/subscribers/advertise</a>

*Neurology*® is the official journal of the American Academy of Neurology. Published continuously since 1951, it is now a weekly with 48 issues per year. Copyright © 2016 American Academy of Neurology. All rights reserved. Print ISSN: 0028-3878. Online ISSN: 1526-632X.

