

Neurology[®]

Table of Contents

Volume 86, Number 1, January 5, 2016

Neurology.org

THE MOST WIDELY READ AND HIGHLY CITED PEER-REVIEWED
NEUROLOGY JOURNAL



IN FOCUS

- 1 Spotlight on the January 5 Issue
- 78 This Week's *Neurology*[®] Podcast

ACKNOWLEDGMENT TO REVIEWERS

- 2 Message from the Editors to our Reviewers
R.A. Gross, B.B. Worrall, A.A. Amato, G.D. Cascino, O. Ciccarelli, J.R. Corboy, J.O. Dalmau, R.F. Gottesman, M. Grossman, J.W. Mink, S.M. Pulst, and R.J. Uitti

EDITORIALS





- 11 *Neurology* mini-sites: New content and re-use of previously published *Neurology* content
P.K. Baskin and R.A. Gross
- 13 Perinatal HIV in the brain: Mission incomplete despite combination antiretroviral therapy
B.M. Ances and J. Hoare
- 15 Neuroimaging in Aicardi-Goutières syndrome: Biomarkers for a progressive encephalopathy
B. Uzgil and E.H. Sherr

IN MEMORIAM

- 17 Alain Michault, PharmD (1950–2015)
P. Gérardin, S. Larrieu, and K. Dellagi, on behalf of Alain's friends

ARTICLES

- 19 Cerebral injury in perinatally HIV-infected children compared to matched healthy controls
S. Cohen, M.W.A. Caan, H.-J. Mutsaerts, H.J. Scherpbier, T.W. Kuijpers, P. Reiss, C.B.L.M. Majoie, and D. Pajkrt
Editorial, p. 13
- 28 Neuroradiologic patterns and novel imaging findings in Aicardi-Goutières syndrome
R. La Piana, C. Uggetti, F. Roncarolo, A. Vanderver, I. Olivieri, D. Tonduti, G. Helman, U. Balottin, E. Fazzi, Y.J. Crow, J. Livingston, and S. Orcesi
Editorial, p. 15

- 36 Relationship of regional brain β -amyloid to gait speed
N. del Campo, P. Payoux, A. Djilali, J. Delrieu, E.O. Hoogendijk, Y. Rolland, M. Cesari, M.W. Weiner, S. Andrieu, and B. Vellas, for the MAPT/DSA Study Group
- 44 ¹⁸F-FDG-PET correlates of cognitive impairment in ALS
A. Canosa, M. Pagani, A. Cistaro, A. Montuschi, B. Iazzolino, P. Fania, S. Cammarosano, A. Ilardi, C. Moglia, A. Calvo, and A. Chiò
- 50 Use of amyloid-PET to determine cutpoints for CSF markers: A multicenter study
M.D. Zwan, J.O. Rinne, S.G. Hasselbalch, A. Nordberg, A. Lleó, S.-K. Herukka, H. Soininen, I. Law, J.M.C. Bahl, S.F. Carter, J. Fortea, R. Blesa, C.E. Teunissen, F.H. Bouwman, B.N.M. van Berckel, and P.J. Visser

- 59 Time trends in causes of death after aneurysmal subarachnoid hemorrhage: A hospital-based study
M.D.I. Vergouwen, A.V. Jong-Tjien-Fa, A. Algra, and G.J.E. Rinkel

- 64 Medical vs invasive therapy in AVM-related epilepsy: Systematic review and meta-analysis
C.B. Josephson, K. Sauro, S. Wiebe, F. Clement, and N. Jette
- 72 Disparities in surgery among patients with intractable epilepsy in a universal health system
J.G. Burneo, S.Z. Shariff, K. Liu, S. Leonard, G. Saposnik, and A.X. Garg

- 79 Pregnancy outcomes in aquaporin-4-positive neuromyelitis optica spectrum disorder
M.M. Nour, I. Nakashima, E. Coutinho, M. Woodhall, F. Sousa, J. Revis, Y. Takai, J. George, J. Kitley, M.E. Santos, J.M. Nour, F. Cheng, H. Kuroda, T. Misu, A. Martins-da-Silva, G.C. DeLuca, A. Vincent, J. Palace, P. Waters, K. Fujihara, and M.I. Leite


CONTINUED

Neurology[®]

Table of Contents

continued



88 Association between age at onset of multiple sclerosis and vitamin D level-related factors
J.H. Laursen, H.B. Søndergaard, P.S. Sørensen, F. Sellebjerg, and A.B. Oturai

94 Chikungunya virus-associated encephalitis: A cohort study on La Réunion Island, 2005–2009
P. Gérardin, T. Couderc, M. Bintner, P. Tournebize, M. Renouil, J. Lémant, V. Boisson, G. Borgherini, F. Staikowsky, F. Schramm, M. Lecuit, and A. Michault, on behalf of the Encephalchik Study Group

CLINICAL/SCIENTIFIC NOTES

103 CLIPPERS with diffuse white matter and longitudinally extensive spinal cord involvement
Y.-X. Zhang, H.-T. Hu, X.-Y. Ding, L.-H. Chen, Y. Du, C.-H. Shen, Y. Guo, and M.-P. Ding

NEUROIMAGES

106 Frozen cord
S. Ali

RESIDENT & FELLOW SECTION

e1 Pearls & Oysters: Spinocerebellar ataxia type 3 presenting with cervical dystonia without ataxia
J.A. Muglan, S. Menon, and M.S. Jog



e4 Clinical Reasoning: A 64-year-old man with progressive paraspinal muscle weakness
R. Schneider, C. Steriade, P. Ashby, and T.-R. Kiehl

e10 Teaching NeuroImages: Interhemispheric multiloculated cyst with callosal dysgenesis in an infant
R. Shrestha and B.C. Warf

WRITECLICK[®] EDITOR'S CHOICE

108 Early EEG contributes to multimodal outcome prediction of postanoxic coma
N.K. Sethi, S. Lattanzi, M. Silvestrini; Author Response: J. Hofmeijer, M.J.A.M. van Putten

DEPARTMENT

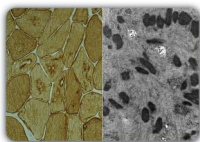
In the Next Issue of *Neurology*[®]

Podcast at Neurology.org CME Video Patient Page LOE classification LOE recommendation



Find us on Facebook

tinyurl.com/neurologyfan twitter.com/GreenJournal



Cover image: Immunohistochemistry for desmin (left) highlights the periphery of the aggregates while not labeling the centers and higher magnification of nemaline bodies (right) in a patient with progressive paraspinal muscle weakness. See page e4.

Look for **Publish Ahead of Print** articles and editorials under the Ahead of Print tab at Neurology.org

Neurology®

86 (1)

Neurology 2016;86:e4-109

This information is current as of January 1, 2016

Updated Information & Services

including high resolution figures, can be found at:
<http://n.neurology.org/content/86/1.full>

Permissions & Licensing

Information about reproducing this article in parts (figures, tables) or in its entirety can be found online at:
http://www.neurology.org/about/about_the_journal#permissions

Reprints

Information about ordering reprints can be found online:
<http://n.neurology.org/subscribers/advertise>

Neurology® is the official journal of the American Academy of Neurology. Published continuously since 1951, it is now a weekly with 48 issues per year. Copyright . All rights reserved. Print ISSN: 0028-3878. Online ISSN: 1526-632X.

