

Neurology[®]

Table of Contents

Volume 85, Number 7, August 18, 2015
Neurology.org

THE MOST WIDELY READ AND HIGHLY CITED PEER-REVIEWED
NEUROLOGY JOURNAL







IN FOCUS


- 559 Spotlight on the August 18 Issue
- 645 This Week's *Neurology*[®] Podcast

EDITORIALS

- 560 Should we train respiratory muscles after stroke?
S.T. Kulnik
- 562 Dual antiplatelet therapy for TIA reduces subsequent disability: A CHANCE to improve outcomes?
Y.J. Alderazi

ARTICLES

- 564 Inspiratory and expiratory muscle training in subacute stroke: A randomized clinical trial
M. Messaggi-Sartor, A. Guillen-Solà, M. Depolo, E. Duarte, D.A. Rodríguez, M.-C. Barrera, E. Barreiro, F. Escalada, M. Orozco-Levi, and E. Marco
 **Editorial, p. 560**
- 573 Effect of clopidogrel with aspirin on functional outcome in TIA or minor stroke: CHANCE substudy
X. Wang, X. Zhao, S.C. Johnston, Y. Xian, B. Hu, C. Wang, D. Wang, L. Liu, H. Li, J. Fang, X. Meng, A. Wang, Y. Wang, and Y. Wang, for the CHANCE investigators
  **Editorial, p. 562**
- 580 Antiepileptic drugs and intrauterine death: A prospective observational study from EURAP
T. Tomson, D. Battino, E. Bonizzoni, J.J. Craig, D. Lindhout, E. Perucca, A. Sabers, S.V. Thomas, and F. Vajda, for the EURAP Study Group

- 587 Comment: Stillbirths and spontaneous abortions in women with epilepsy on AEDs
N. Jetté
- 589 Focal seizure symptoms in idiopathic generalized epilepsies
U. Seneviratne, J.J. Woo, R.C. Boston, M. Cook, and W. D'Souza

- 594 Comment: Be careful what you ask when interviewing patients with epilepsy
J.C. Henry
- 596 Effect of vaccinations on seizure risk and disease course in Dravet syndrome
N.E. Verbeek, N.A.T. van der Maas, A.C.M. Sonsma, E. Ippel, P.E. Vermeer-de Bondt, E. Hagebeuk, F.E. Jansen, H.H. Geesink, K.P. Braun, A. de Louw, P.B. Augustijn, R.F. Neuteboom, J.H. Schieving, H. Stroink, R.J. Vermeulen, J. Nicolai, O.F. Brouwer, M. van Kempen, C.G.F. de Kovel, J.M. Kemmeren, B.P.C. Koeleman, N.V. Knoers, D. Lindhout, W.B. Gunning, and E.H. Brilstra
- 604 MRI in assessing children with learning disability, focal findings, and reduced automaticity
D.K. Urion, H.V. Huff, and M.P. Carullo
- 610 Retinal pathology in Susac syndrome detected by spectral-domain optical coherence tomography
M. Ringelstein, P. Albrecht, I. Kleffner, B. Bühn, J. Harmel, A.-K. Müller, D. Finis, R. Guthoff, R. Bergholz, T. Duning, M. Krämer, F. Paul, A. Brandt, T. Oberwahrenbrock, J. Mikolajczak, B. Wildemann, S. Jarius, H.-P. Hartung, O. Aktas, and J. Dörr
- 619 Cost-effectiveness of shared medical appointments for neuromuscular patients
F.M. Seesing, H.J. Groenewoud, G. Drost, B.G.M. van Engelen, and G.J. van der Wilt

- 626 Amyloid precursor protein metabolism and inflammation markers in preclinical Alzheimer disease
D. Alcolea, P. Martínez-Lage, P. Sánchez-Juan, J. Olazarán, C. Antúnez, A. Izagirre, M. Ecay-Torres, A. Estanga, M. Clerigué, M.C. Guisasola, D. Sánchez Ruiz, J. Marín Muñoz, M. Calero, R. Blesa, J. Clarimón, M. Carmona-Iragui, E. Morenas-Rodríguez, E. Rodríguez-Rodríguez, J.L. Vázquez Higuera, J. Fortea, and A. Lleó

CONTINUED

Neurology[®]

Table of Contents


continued



CLINICAL IMPLICATIONS OF NEUROSCIENCE RESEARCH

- 634 The autophagy-lysosomal pathway:
General concepts and clinical implications
D.L. Kenney and E.E. Benarroch


VIEWS & REVIEWS

- 646 Opioids for chronic noncancer pain: To
prescribe or not to prescribe—What is the
question?
S.E. Nadeau

- 650 Comment: Prescription opioids—Misused or
misunderstood?
J.C.M. Brust

CLINICAL/SCIENTIFIC NOTES

- 652 Diffuse leukoencephalopathy with spheroids
presenting as primary progressive
aphasia
*C. Oboudiyat, E.H. Bigio, B. Bonakdarpour,
M.C. Baker, R. Rademakers, S. Weintraub, and
M.-M. Mesulam*

VIDEO NEUROIMAGES

- 654 Axial myoclonus after ischemic stroke
*P.N. Alves, M. de Carvalho, R. Peralta, R. Gerales,
A.C. Fonseca, and T. Pinho e Melo*


RESIDENT & FELLOW SECTION

- e57 Clinical Reasoning: Worsening neurologic symptoms
in a brain tumor patient
*G. Faivre, E. Pentsova, A. Demopoulos, S. Taillibert,
M. Rosenblum, and A. Omuro*

WRITECLICK[®] EDITOR'S CHOICE

- 655 Teaching *NeuroImages*: The lentiform fork sign: An MRI
pattern of metformin-associated encephalopathy
*C. Kaiwar; Author Response: G.C. Fernandes,
C.R.M. Rieder, L. Vedolin, L. Campos, T. Koltermann*
- 655 Vigabatrin retinal toxicity in children with infantile
spasms: An observational cohort study
J.D. Akula; Author Response: C.A. Westall, T. Wright

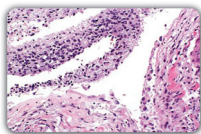
DEPARTMENT

In the Next Issue of *Neurology*[®]

 Podcast at Neurology.org  CME  Video  Patient Page  LOE classification  LOE recommendation



tinyurl.com/neurologyfan  twitter.com/GreenJournal



Cover image: Autopsy revealed extensive leptomeningeal spread of glioma, which coated the spinal cord and engulfed nerve roots, contrasting with unremarkable imaging. See page e57.

Look for **Publish Ahead of Print** articles and editorials under the Ahead of Print tab at Neurology.org

Neurology®

85 (7)

Neurology 2015;85:e57-656

This information is current as of January 1, 2015

Updated Information & Services

including high resolution figures, can be found at:
<http://n.neurology.org/content/85/7.full>

Permissions & Licensing

Information about reproducing this article in parts (figures, tables) or in its entirety can be found online at:
http://www.neurology.org/about/about_the_journal#permissions

Reprints

Information about ordering reprints can be found online:
<http://n.neurology.org/subscribers/advertise>

Neurology® is the official journal of the American Academy of Neurology. Published continuously since 1951, it is now a weekly with 48 issues per year. Copyright . All rights reserved. Print ISSN: 0028-3878. Online ISSN: 1526-632X.

