

Clinical Reasoning:

A 51-year-old woman with weakness and stiff neck

Charles D. Kassardjian,
MD
Margherita Milone, MD,
PhD

Correspondence to
Dr. Kassardjian:
kassardjian.charles@mayo.edu

SECTION 1

A 51-year-old woman presented to the neuromuscular clinic for evaluation of predominantly proximal bilateral lower limb weakness that had slowly progressed for 5 years. However, her husband noted that for at least 20–30 years she has had a waddling gait. She denied upper limb weakness, ptosis, diplopia, bulbar symptoms, and fluctuations of the weakness. There was no history of myalgia, cramps, or urine discoloration. She had no sensory symptoms, cognitive changes, or cardiorespiratory symptoms.

The patient was the product of a normal pregnancy and had normal motor development. She was able to keep up with her peers in gym class. Her medical history was unremarkable. The family history was relevant for leg weakness resulting in difficulty climbing stairs in her mother since her 50s. Two brothers (ages 41 and 47 years) and 2 sons (ages 26 and 30 years) had no weakness. There was no family history of cardiomyopathy, cardiac arrhythmia, cataracts, or early disability.

On examination, she had moderate to marked predominantly proximal lower limb muscle weakness

(Medical Research Council [MRC] grade 2–3) and milder proximal more than distal upper limb weakness (MRC grade 3–4). The weakness was relatively symmetric (right minimally worse than left). Tendon reflexes were absent, except for biceps bilaterally and left knee jerk, which were present but hypoactive. She had a waddling gait and could not walk on heels or toes. She was unable to rise from a chair without pushing on it with her hands. She had mild hyperlordosis, paraspinal muscle atrophy, and spinal rigidity in the cervical region. She also had laxity of the left metacarpophalangeal and distal interphalanges joints of both thumbs. The rest of the neurologic examination was normal, and, in particular, she had no weakness of the extraocular or facial muscles. Her blood pressure and heart rate were normal.

Questions for consideration:

1. What is your differential diagnosis at this point?
2. What tests would you consider to help narrow your differential diagnosis?

[GO TO SECTION 2](#)

SECTION 2

The patient presented with slowly progressive lower greater than upper limb weakness, with both proximal and distal muscle involvement. Paraspinal muscle atrophy and spinal rigidity were notable. Sensory symptoms were absent and there was no sensory loss. Therefore this is a pure motor syndrome that could localize to the anterior horn cells, neuromuscular junction, or muscle. A polyradiculopathy could explain proximal and distal weakness, but the absence of sensory features would be atypical for it. Although the patient only noted symptoms for 5 years, it was clear from her husband that her gait was abnormal for 20–30 years. The longstanding minimally and very slowly progressive course of her symptoms would favor an inherited etiology, as opposed to an acquired disease (such as inflammatory or immune-mediated disorders of the muscle, neuromuscular junction, or nerve roots).

The evaluation included creatine kinase (CK) of 177 U/L (normal <176 U/L) and normal blood

count, erythrocyte sedimentation rate, and thyroid-stimulating hormone. Acetylcholine receptor antibodies were absent. Nerve conduction studies showed normal peroneal, tibial, and ulnar nerve motor studies, and normal sural and medial nerve sensory studies. 2-Hz repetitive nerve stimulation of the facial and spinal accessory nerves was normal. Needle EMG of the biceps brachii, triceps, infraspinatus, medial gastrocnemius, gluteus medius, tibialis anterior, vastus lateralis, and lumbar paraspinal muscles revealed short-duration low-amplitude polyphasic motor unit potentials with rapid recruitment especially in the biceps and triceps. Fibrillation potentials and myotonic discharges were absent.

Questions for consideration:

1. What is your differential diagnosis based on this information?
2. What testing could you consider performing at this time?

GO TO SECTION 3

SECTION 3

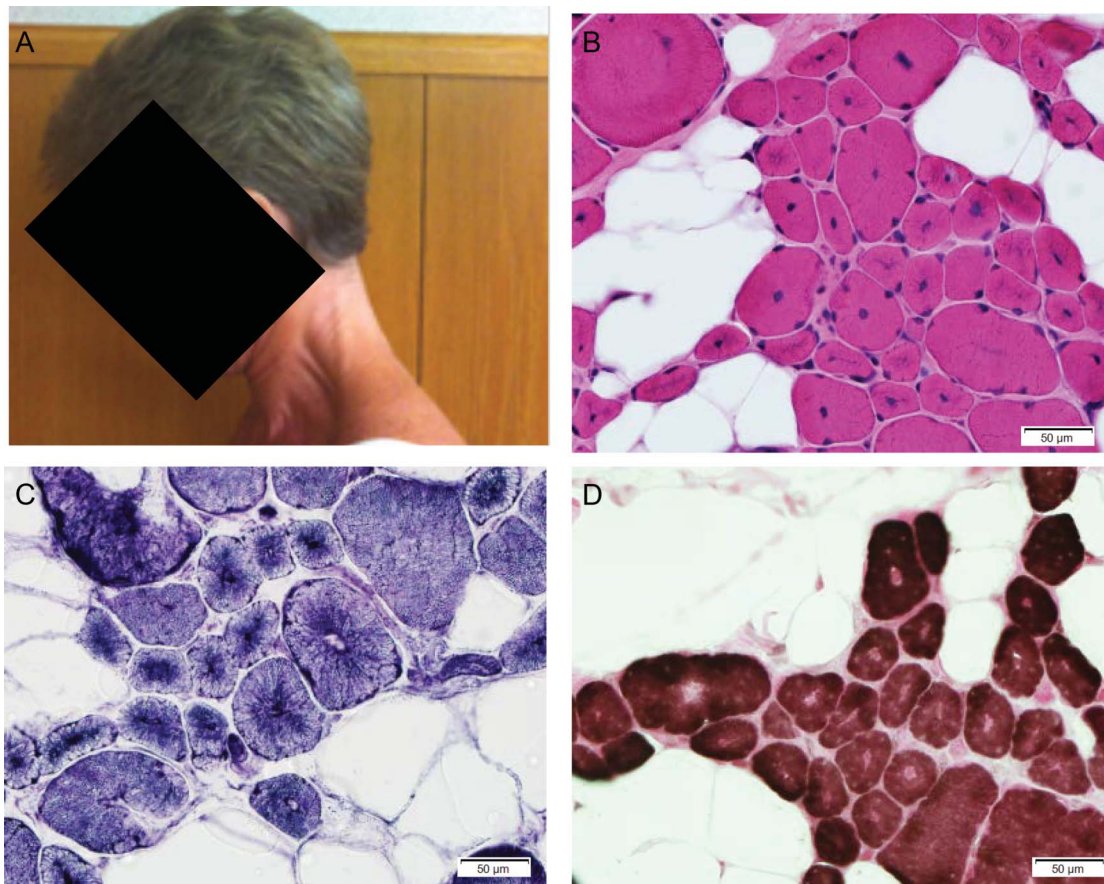
The EMG findings are highly suggestive of a myopathy, and rule out disorders of the anterior horn cells, nerve roots, and neuromuscular junction. The differential diagnosis for a generalized myopathy is broad. The longstanding, slowly progressive course points away from acquired myopathies and favors a hereditary myopathy. The history of weakness in the patient's mother suggests an autosomal dominant disease. The near-normal CK value does not rule out a myopathy, since many inherited myopathies (e.g., congenital myopathies) may have a normal or only minimally elevated CK value.

One feature that may help narrow the differential diagnosis is the presence of paraspinal muscle atrophy and spinal rigidity. Spinal rigidity, characterized by limited range of motion of the cervical, thoracic, or lumbosacral spinal segments, has sometimes been referred to as the rigid spine syndrome (RSS). RSS can accompany or be prominent in several inherited myopathies, including congenital myopathy due to mutations in selenoprotein N (*SEPN1*),^{1,2} which often

demonstrates multi-minicores on muscle biopsy; centronuclear myopathy³; nemaline myopathy²; collagen-VI-related myopathies; and Emery-Dreifuss muscular dystrophy, some of which display autosomal dominant inheritance (lamin A/C [*LMNA*], nesprin-1 [*SYNE1*], nesprin-2 [*SYNE2*], and transmembrane protein 43 [*TMEM43*]).⁴ Rarely, acid maltase deficiency has been associated with RSS.⁵ Joint hyperlaxity may be seen in some congenital myopathies, such as collagen-VI-related myopathy, centronuclear, or multi-minicores myopathy.⁶ The patient did not have limb contractures that may suggest an Emery-Dreifuss phenotype. In addition, she had no evidence of cardiac involvement by ECG and echocardiogram.

A muscle biopsy of the left vastus lateralis was performed (figure, B–D). The majority of fibers contained a single large central nucleus, while rare fibers had multiple internalized nuclei. In oxidative enzyme-reacted sections, numerous fibers had sarcolemmal strands radiating from the central nucleus and resulting in a spoke-like appearance. Nuclei or perinuclear area of fibers with centralized nuclei often

Figure Patient photograph and muscle biopsy



(A) Spinal rigidity at the cervical level (the patient is attempting to flex the neck, but is unable to do so). (B) Hematoxylin & eosin-stained section demonstrates fiber size variability (diameter ranging from 10–140 µm), the majority of fibers harboring a single central nucleus, and increased endomysial fibrous connective tissue. (C) NADH-TR-stained section shows sarcolemmal strands radiating from the central nuclei. (D) ATPase-stained section, pH 4.3, demonstrates type 1 fiber preponderance and lack of reactivity in central nuclei and perinuclear area.

lacked myofibrillar ATPase reactivity. There was increased muscle fiber size variability (range 10–140 μm) and a marked type 1 fiber predominance. No necrotic fibers were present but a single regenerating fiber was observed. The histologic features were consistent with a centronuclear myopathy (CNM).

CNM are classified as congenital myopathies and are genetically heterogeneous. Because of the suspected autosomal dominant pattern of inheritance, sequencing of the dynamin-2 gene (*DNM2*) was performed and revealed a known pathogenic heterozygous mutation in exon 8 (c.1106 G>A, p.Arg369Gln).

DISCUSSION The clinical presentation of CNM is heterogeneous, ranging from a severe neonatal-onset myopathy to adult-onset forms.⁷ Mutations in 3 genes explain the majority of CNM: myotubularin (*MTM1*), dynamin-2 (*DNM2*), and amphiphysin-2 (*BINI*) genes.^{7–9} *MTM1* mutations cause X-linked CNM (also termed myotubular myopathy). The clinical phenotype is usually of a severe myopathy in male neonates, causing hypotonia, muscle weakness, respiratory failure, and feeding difficulties. Other clinical findings include ptosis, facial diplegia, and ophthalmoplegia. Affected infants may have pectus carinatum, micrognathia, macrocephaly, or cryptorchidism. Milder phenotypes also occur. *MTM1* mutation female carriers may be either asymptomatic or have a mild adult-onset myopathy.⁷ Mutations in *BINI* are inherited with an autosomal recessive pattern and exceptionally rarely with an autosomal dominant pattern.^{10,11} *BINI*-CNM also has a broad clinical spectrum of severity. Most cases present in childhood with delayed motor milestones, limb weakness, variable ptosis, and ophthalmoplegia. Very rarely, autosomal recessive mutations in *RYR1* cause a congenital myopathy with prominent central nuclei.⁷ Rare genes associated with CNM include the coiled coil domain containing protein 78 (*CCDC78*), myotubularin-related protein 14 (*MTM14*), and myogenic factor 6 (*MYF6*) genes (all autosomal dominant) and striated preferentially expressed protein (*SPEG*, autosomal recessive).

DNM2 mutations cause an autosomal dominant CNM presenting usually in childhood or in adulthood.⁸ Severe infantile forms can occur.^{3,7} Children often have delayed motor milestones, along with limb and facial weakness, and associated atrophy. Ophthalmoparesis and ptosis are common.³ Skeletal abnormalities include scoliosis and pes cavus; RSS is a rarely reported manifestation. Cardiac abnormalities are exceedingly infrequent, but many patients can have restrictive lung disease.³ Adult-onset forms are usually milder. Muscle biopsy tends to show a triad of (1) nuclear centralization, (2) radiating sarcoplasmic strands easily

recognizable in NADH-TR-stained transverse sections, and (3) type 1 fiber preponderance and smallness.⁷

Dynamin-2 is one of 3 isoforms of dynamin, and acts as a GTPase involved in endocytosis and membrane remodeling.^{12,13} Their major role is in membrane fission, but there is an expanding number of functions attributed to the dynamin proteins, such as microtubule and cytoskeletal maintenance, transportation of molecules from organelles like the Golgi apparatus, and calcium homeostasis.^{11,12} Mutations in *DNM2* can also cause intermediate and axonal dominant forms of Charcot-Marie-Tooth neuropathy (CMT). The mutations associated with CNM tend to occur in different locations within the *DNM2* gene than those associated with CMT. In CNM, most mutations are in the pleckstrin homology and GTPase-effector domains, while in CMT mutations tend to cluster in the N-terminal of the pleckstrin homology domain.^{11,13} Hence, the disease mechanisms are also thought to differ: in CNM, there may be impaired autophagy and calcium homeostasis, whereas in CMT, a defect in clathrin-mediated endocytosis leading to defective myelination may be the responsible mechanism.¹³

AUTHOR CONTRIBUTIONS

C.D.K. contributed to the study design, data analysis, and drafting of the manuscript. M.M. contributed to study design, data analysis, drafting, and critical revision of the manuscript.

STUDY FUNDING

No targeted funding reported.

DISCLOSURE

The authors report no disclosures relevant to the manuscript. Go to Neurology.org for full disclosures.

REFERENCES

1. Moghadaszadeh B, Petit N, Jaillard C, et al. Mutations in *SEPN1* cause congenital muscular dystrophy with spinal rigidity and restrictive respiratory syndrome. *Nat Genet* 2001;29:17–18.
2. Maggi L, Scoto M, Cirak S, et al. Congenital myopathies: clinical features and frequency of individual subtypes diagnosed over a 5-year period in the United Kingdom. *Neuromuscul Disord* 2013;23:195–205.
3. Catteruccia M, Fattori F, Codemo V, et al. Centronuclear myopathy related to dynamin 2 mutations: clinical, morphological, muscle imaging and genetic features of an Italian cohort. *Neuromuscul Disord* 2013;23:229–238.
4. Astejada MN, Goto K, Nagano A, et al. Emerinopathy and laminopathy clinical, pathological and molecular features of muscular dystrophy with nuclear envelopathy in Japan. *Acta Myol* 2007;26:159–164.
5. Fadic R, Waclawik AJ, Brooks BR, Lotz BP. The rigid spine syndrome due to acid maltase deficiency. *Muscle Nerve* 1997;20:364–366.
6. Voermans NC, Bonnemann CG, Hamel BC, Jungbluth H, van Engelen BG. Joint hypermobility as a distinctive feature in the differential diagnosis of myopathies. *J Neurol* 2009;256:13–27.

7. Romero NB, Bitoun M. Centronuclear myopathies. *Semin Pediatr Neurol* 2011;18:250–256.
8. Bitoun M, Maugère S, Jeannot PY, et al. Mutations in dynamin 2 cause dominant centronuclear myopathy. *Nat Genet* 2005;37:1207–1209.
9. Laporte J, Hu LJ, Kretz C, et al. A gene mutated in X-linked myotubular myopathy defines a new putative tyrosine phosphatase family conserved in yeast. *Nat Genet* 1996;13:175–182.
10. Nicot AS, Toussaint A, Tosch V, et al. Mutations in amphiphysin 2 (BIN1) disrupt interaction with dynamin 2 and cause autosomal recessive centronuclear myopathy. *Nat Genet* 2007;39:1134–1139.
11. Jungbluth H, Wallgren-Pettersson C, Laporte JF. 198th ENMC International Workshop: 7th Workshop on Centronuclear (Myotubular) myopathies, 31st May–2nd June 2013, Naarden, The Netherlands. *Neuromuscul Disord* 2013;23:1033–1043.
12. Gonzalez-Jamett AM, Haro-Acuna V, Momboisse F, Caviedes P, Bevilacqua JA, Cardenas AM. Dynamin-2 in nervous system disorders. *J Neurochem* 2014;128:210–223.
13. Sidiropoulos PN, Mische M, Bock T, et al. Dynamin 2 mutations in Charcot-Marie-Tooth neuropathy highlight the importance of clathrin-mediated endocytosis in myelination. *Brain* 2012;135:1395–1411.

Neurology®

Clinical Reasoning: A 51-year-old woman with weakness and stiff neck

Charles D. Kassardjian and Margherita Milone

Neurology 2015;85:e32-e36

DOI 10.1212/WNL.0000000000001795

This information is current as of July 27, 2015

Updated Information & Services	including high resolution figures, can be found at: http://n.neurology.org/content/85/4/e32.full
References	This article cites 13 articles, 0 of which you can access for free at: http://n.neurology.org/content/85/4/e32.full#ref-list-1
Subspecialty Collections	This article, along with others on similar topics, appears in the following collection(s): Muscle disease http://n.neurology.org/cgi/collection/muscle_disease
Permissions & Licensing	Information about reproducing this article in parts (figures, tables) or in its entirety can be found online at: http://www.neurology.org/about/about_the_journal#permissions
Reprints	Information about ordering reprints can be found online: http://n.neurology.org/subscribers/advertise

Neurology® is the official journal of the American Academy of Neurology. Published continuously since 1951, it is now a weekly with 48 issues per year. Copyright © 2015 American Academy of Neurology. All rights reserved. Print ISSN: 0028-3878. Online ISSN: 1526-632X.

