



## In Focus

### Spotlight on the July 7 Issue

**Robert A. Gross, MD, PhD, FAAN**  
Editor-in-Chief, *Neurology*<sup>®</sup>



#### Notable in *Neurology*

This issue features articles discussing the gadolinium-based MRI characterization of leptomeningeal inflammation in multiple sclerosis and altered lysosomal proteins in neural-derived plasma exosomes in preclinical Alzheimer disease. Another featured article focuses on *ADCY5* mutations as another cause of benign hereditary chorea.

#### ARTICLES

##### Switching from natalizumab to fingolimod: A randomized, placebo-controlled study in RRMS

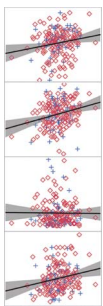
Starting fingolimod 8–12 weeks after the last natalizumab infusion, rather than at 16 weeks, leads to better control of disease activity both clinically and on monthly MRI. Better control of disease activity with shorter intervals outweighs the theoretical risk of additive immunosuppression when switching from natalizumab to fingolimod.

See p. 29

*From editorialists Stüve & Bourdette: "As we seek to personalize the treatment of RRMS using the array of medications now available, we need accurate information not only about the individual medication, but also about how to transition from one medication to another. It is not good enough to rely on guessing and expert opinion."*

See p. 14

##### Cognitive activity relates to cognitive performance but not to Alzheimer disease biomarkers



The authors found that lifestyle factors such as cognitive and physical activity were associated with better cognitive function, which may mitigate Alzheimer disease symptoms. Identifying modifiable factors that may delay or prevent onset of disease is critical but likely will require a carefully controlled prospective study.

See p. 48

##### Subjective cognitive concerns, amyloid- $\beta$ , and neurodegeneration in clinically normal elderly

In a sample of clinically normal elderly individuals, those with biomarker evidence of amyloidosis and neurodegeneration reported greater memory concerns than those who were biomarker negative. There is growing consensus that self-reported memory concerns may be an early sign of Alzheimer disease rather than an artifact of the "worried well."

See p. 56

##### Clinical effect of white matter network disruption related to amyloid and small vessel disease

Using multimodal imaging analyses of 232 patients with cognitive impairment, the authors found that disrupted white matter networks mediate the effect of small vessel disease, but not amyloid, with specific patterns of cortical atrophy and cognitive impairment. Their findings provide a better understanding of how amyloid and small vessel disease affect cognition through different pathways.

See p. 63

*From editorialists Stevens & Hannawi: "As the authors acknowledge, their results cannot attest to a causative sequence of neurobiological events; they highlight a set of associations whose true magnitude and directionality require further investigation."*

See p. 16

*NB: "The preclinical stage of spinocerebellar ataxias," see p. 96. To check out other Views & Reviews, point your browser to [Neurology.org](http://Neurology.org). At the end of the issue, check out the NeuroImages discussing retinal and intracranial hemorrhage in acute leukemic disseminated intravascular coagulation, and pulse-synchronous pendular nystagmus following cholesteatoma surgery. This week also includes a Resident & Fellow Section Teaching NeuroImage titled "Superior divisional oculomotor nerve palsy due to orbital lymphoma."*

Podcasts can be accessed at [Neurology.org](http://Neurology.org)

# Neurology®

## Spotlight on the July 7 Issue

Robert A. Gross

*Neurology* 2015;85;1

DOI 10.1212/WNL.0000000000001703

### This information is current as of July 6, 2015

<b>Updated Information &amp; Services</b>	including high resolution figures, can be found at: <a href="http://n.neurology.org/content/85/1/1.full">http://n.neurology.org/content/85/1/1.full</a>
<b>Citations</b>	This article has been cited by 5 HighWire-hosted articles: <a href="http://n.neurology.org/content/85/1/1.full##otherarticles">http://n.neurology.org/content/85/1/1.full##otherarticles</a>
<b>Permissions &amp; Licensing</b>	Information about reproducing this article in parts (figures, tables) or in its entirety can be found online at: <a href="http://www.neurology.org/about/about_the_journal#permissions">http://www.neurology.org/about/about_the_journal#permissions</a>
<b>Reprints</b>	Information about ordering reprints can be found online: <a href="http://n.neurology.org/subscribers/advertise">http://n.neurology.org/subscribers/advertise</a>

*Neurology*® is the official journal of the American Academy of Neurology. Published continuously since 1951, it is now a weekly with 48 issues per year. Copyright © 2015 American Academy of Neurology. All rights reserved. Print ISSN: 0028-3878. Online ISSN: 1526-632X.

