

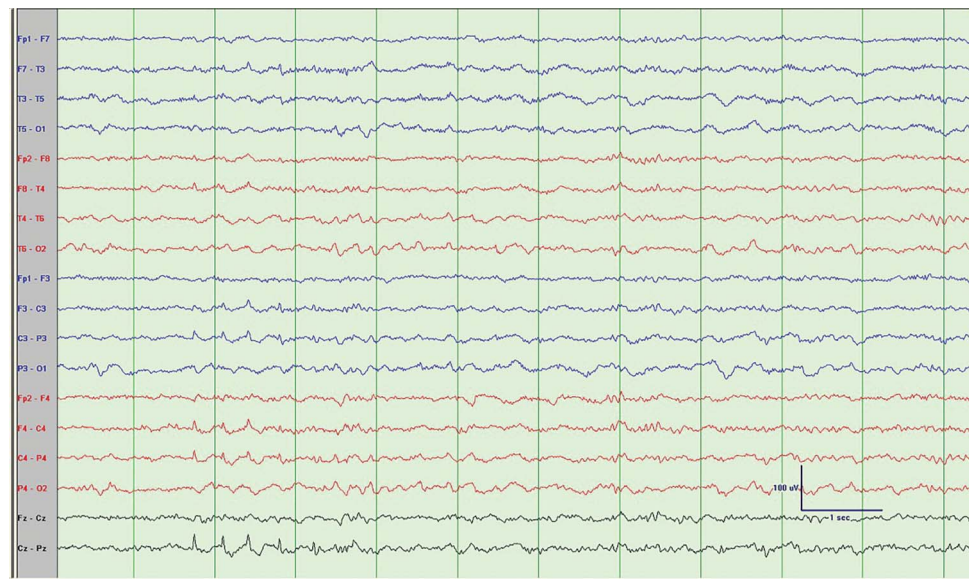
Mystery Case: Sawtooth waves

Another normal variant not to over-read as epileptiform discharges

Yazan M. Suradi, MD
Fahad Salih Algreeshah,
MD
Noemi Rincon-Flores,
MD
Selim R. Benbadis, MD

Correspondence to
Dr. Suradi:
ysuradi@health.usf.edu

Figure 1 Bipolar longitudinal (double-banana) montage



The sawtooth waves are seen in channels CZ, C4, and C3. Note the location (central), the amplitude (between 10 and 70 μ V), and the frequency (3–5 Hz). There are no REM sleep patterns shown, so they could be misinterpreted as sharp waves.

A 20-year-old-woman demonstrated sawtooth waves but no epileptiform discharges while undergoing EEG-video monitoring for new-onset generalized tonic-clonic seizure-like activity and staring spells (figures 1 and 2). Sawtooth waves are an uncommon EEG pattern of REM sleep.¹ They have a unique morphology, first described in 1937 by Alfred Lee Loomis, are maximum in the central regions, and typically occur in repetitive bursts. They are seen in REM sleep, typically in the vicinity of eye movements, but at times they can be found seconds or minutes away from REM.¹ The identification of sawtooth waves is important to avoid their misinterpretation as epileptic discharges and the (common) misdiagnosis of epilepsy.²

AUTHOR CONTRIBUTIONS

Yazan M. Suradi: drafting/revising the manuscript, accepts responsibility for conduct of research and final approval, contribution of vital

reagents/tools/patients, acquisition of data. Fahad Salih Algreeshah: study concept or design, analysis or interpretation of data, accepts responsibility for conduct of research and final approval, acquisition of data. Noemi Rincon-Flores: analysis or interpretation of data, accepts responsibility for conduct of research and final approval, acquisition of data. Selim R. Benbadis: drafting/revising the manuscript, study concept or design, analysis or interpretation of data, accepts responsibility for conduct of research and final approval, acquisition of data, study supervision.

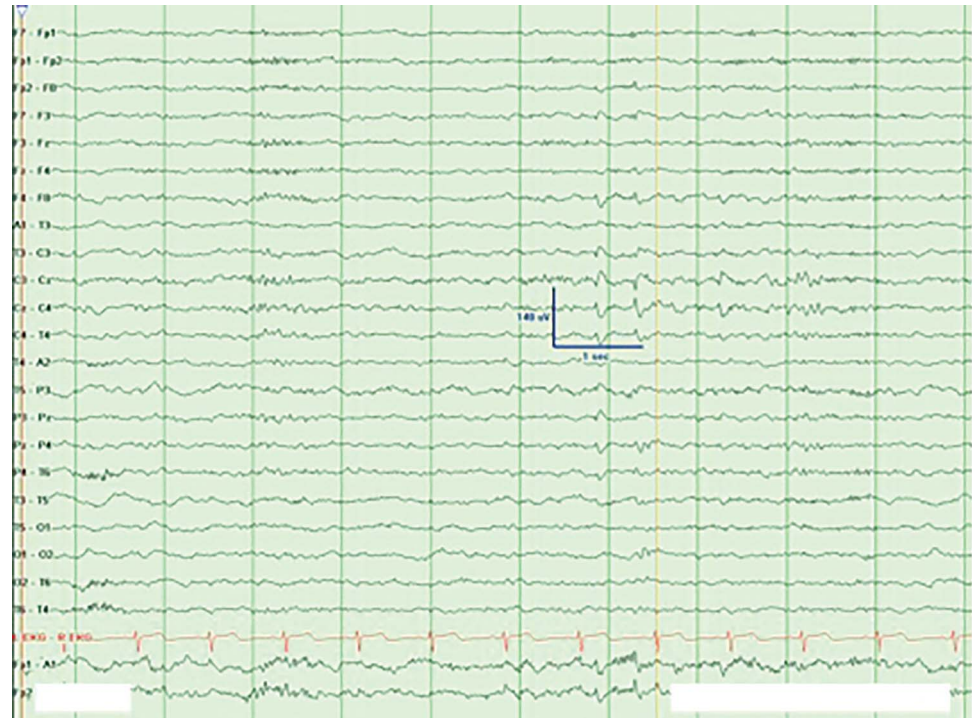
STUDY FUNDING

No targeted funding reported.

DISCLOSURE

Y. Suradi, F. Algreeshah, and N. Rincon-Flores report no disclosures relevant to the manuscript. S. Benbadis has served as a consultant for Cyberonics, Lundbeck, Supernus, and UCB Pharma; is on the speakers bureau for Cyberonics, Glaxo Smith Kline, Lundbeck, Supernus, and UCB Pharma; has received grant support from Cyberonics, Lundbeck, Sepracor, Sunovion, Supernus, UCB Pharma, and Upsher-Smith; received royalties as an author or editor for Emedicine-Medscape-WebMD and UpToDate; and is on the Editorial Board for Emedicine-Medscape-WebMD, *European Neurology*, *Epileptic Disorders*, *Epilepsy and*

Figure 2 Transverse montage shows sawtooth waves in non-REM sleep in the patient



Behavior, and Expert Review of Neurotherapeutics. Go to Neurology.org for full disclosures.

REFERENCES

1. Sato S, McCutchen C, Graham B, Freeman A, von Albertini-Carletti I, Alling DW. Relationship between muscle tone changes, sawtooth waves and rapid eye movements during sleep. *Electroencephalogr Clin Neurophysiol* 1997;103:627–632.
2. Benbadis SR. Just like EKGs! Should EEGs undergo a confirmatory interpretation by a clinical neurophysiologist? *Neurology* 2013;80(suppl 1):S47–S51.

Neurology®

Mystery Case: Sawtooth waves: Another normal variant not to over-read as epileptiform discharges

Yazan M. Suradi, Fahad Salih Algreeshah, Noemi Rincon-Flores, et al.

Neurology 2015;84:e87-e88

DOI 10.1212/WNL.0000000000001386

This information is current as of March 23, 2015

Updated Information & Services	including high resolution figures, can be found at: http://n.neurology.org/content/84/12/e87.full
References	This article cites 2 articles, 1 of which you can access for free at: http://n.neurology.org/content/84/12/e87.full#ref-list-1
Subspecialty Collections	This article, along with others on similar topics, appears in the following collection(s): EEG http://n.neurology.org/cgi/collection/eeg_ Epilepsy semiology http://n.neurology.org/cgi/collection/epilepsy_semiology Epileptogenic zone http://n.neurology.org/cgi/collection/epileptogenic_zone
Permissions & Licensing	Information about reproducing this article in parts (figures, tables) or in its entirety can be found online at: http://www.neurology.org/about/about_the_journal#permissions
Reprints	Information about ordering reprints can be found online: http://n.neurology.org/subscribers/advertise

Neurology® is the official journal of the American Academy of Neurology. Published continuously since 1951, it is now a weekly with 48 issues per year. Copyright © 2015 American Academy of Neurology. All rights reserved. Print ISSN: 0028-3878. Online ISSN: 1526-632X.

