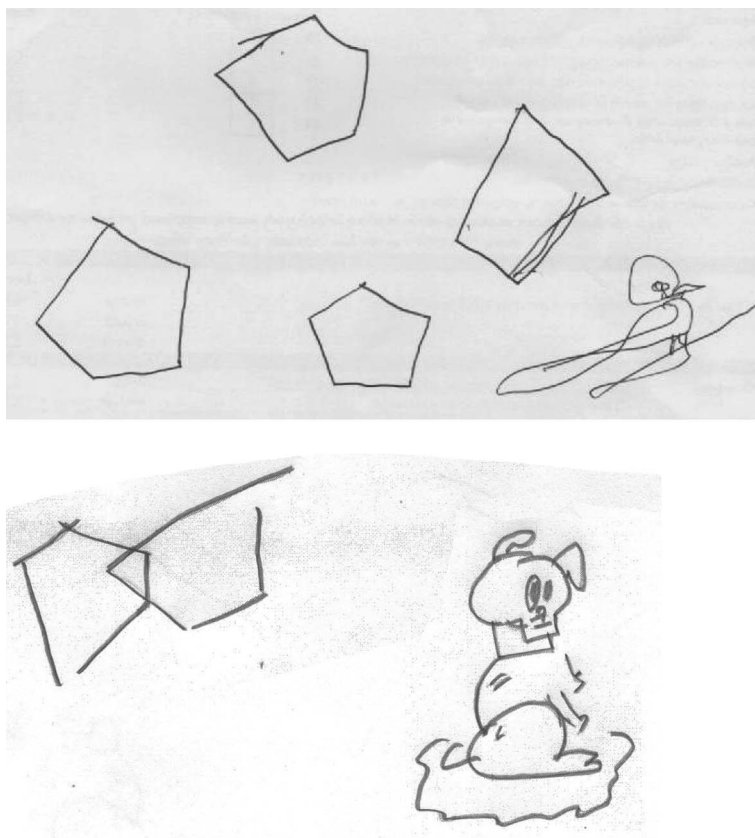


Drawing perseveration in the behavioral variant of frontotemporal dementia

Figure Drawing perseveration



The first patient drew a pigeon and the second drew a dog after they were asked to copy the pentagons.

The behavioral variant of frontotemporal dementia (bvFTD) represents a distinct clinical FTD subtype, dominated by progressive deterioration in cognition, personality, and social conduct. Perseverative behavior is a core clinical feature in the proposed diagnostic criteria.¹ Two patients with bvFTD exhibited a peculiar form of perseveration, which we named drawing perseveration. During neuropsychometric testing, especially after copying pentagons, they both spontaneously drew animals: a pigeon or a dog (figure). They both used to draw these animals during childhood, but not during adulthood, in contrast to the emergence of artistic talent that can occur in FTD.²

Panagiotis Ioannidis, MD, PhD, Eleni Konstantinopoulou, MSc, Dimitris Karacostas, MD, PhD

From the 2nd Department of Neurology, AHEPA University Hospital, Thessaloniki, Greece.

Author contributions: Dr. Ioannidis: study concept and design. E. Konstantinopoulou: acquisition of data. Dr. Karacostas: study supervision.

Study funding: No targeted funding reported.

Disclosure: The authors report no disclosures relevant to the manuscript. Go to Neurology.org for full disclosures.

Correspondence to Dr. Ioannidis: ispanagi@auth.gr

1. Rascovsky K, Hodges RJ, Knopman D, et al. Sensitivity of the revised diagnostic criteria for the behavioural variant of frontotemporal dementia. *Brain* 2011;134:2456–2477.
2. Miller BL, Cummings J, Mishkin F, et al. The emergence of artistic talent in frontotemporal dementia. *Neurology* 1998;51:978–982.

Neurology®

Drawing perseveration in the behavioral variant of frontotemporal dementia

Panagiotis Ioannidis, Eleni Konstantinopoulou and Dimitris Karacostas

Neurology 2015;84;101

DOI 10.1212/WNL.0000000000001108

This information is current as of December 29, 2014

Updated Information & Services	including high resolution figures, can be found at: http://n.neurology.org/content/84/1/101.full
References	This article cites 2 articles, 1 of which you can access for free at: http://n.neurology.org/content/84/1/101.full#ref-list-1
Subspecialty Collections	This article, along with others on similar topics, appears in the following collection(s): All Cognitive Disorders/Dementia http://n.neurology.org/cgi/collection/all_cognitive_disorders_dementia Corticobasal degeneration http://n.neurology.org/cgi/collection/corticobasal_degeneration Dementia aphasia http://n.neurology.org/cgi/collection/dementia_aphasia Frontotemporal dementia http://n.neurology.org/cgi/collection/frontotemporal_dementia
Permissions & Licensing	Information about reproducing this article in parts (figures, tables) or in its entirety can be found online at: http://www.neurology.org/about/about_the_journal#permissions
Reprints	Information about ordering reprints can be found online: http://n.neurology.org/subscribers/advertise

Neurology® is the official journal of the American Academy of Neurology. Published continuously since 1951, it is now a weekly with 48 issues per year. Copyright © 2014 American Academy of Neurology. All rights reserved. Print ISSN: 0028-3878. Online ISSN: 1526-632X.

