

Neurology[®]

Table of Contents

Volume 83, Number 2, July 8, 2014
Neurology.org

THE MOST WIDELY READ AND HIGHLY CITED PEER-REVIEWED
NEUROLOGY JOURNAL





IN FOCUS





- 105 Spotlight on the July 8 Issue
- 150 This Week's *Neurology*[®] Podcast

EDITORIALS

- 106 Ranvier revisited: Novel nodal antigens stimulate interest in GBS pathogenesis
H. Willison and S.S. Scherer
- 109 The relationship of CPE to HIV dementia: Slain by an ugly fact?
J.R. Berger and D.B. Clifford
- 111 B-cell depletion in children with neuroimmunologic conditions: The learning curve
T. Chitnis and E. Waubant

ARTICLES

- 113 Moesin is a possible target molecule for cytomegalovirus-related Guillain-Barré syndrome
S. Sawai, M. Satoh, M. Mori, S. Misawa, K. Sogawa, T. Kazami, M. Ishibashi, M. Beppu, K. Shibuya, T. Ishige, Y. Sekiguchi, K. Noda, K. Sato, K. Matsushita, Y. Kodera, F. Nomura, and S. Kuwabara
 **Editorial, p. 106**
- 118 Antibodies to single glycolipids and glycolipid complexes in Guillain-Barré syndrome subtypes
N. Shahrizaila, N. Kokubun, S. Sawai, T. Umapathi, Y.-C. Chan, S. Kuwabara, K. Hirata, and N. Yuki

- 125 Serum FGF21 levels in adult m.3243A>G carriers: Clinical implications
S. Koene, P. de Laat, D.H. van Tienoven, D. Vriens, A.M. Brandt, F.C.G.J. Sweep, R.J.T. Rodenburg, A.R.T. Donders, M.C.H. Janssen, and J.A.M. Smeitink
- 134 Antiretroviral penetration into the CNS and incidence of AIDS-defining neurologic conditions
E.C. Caniglia, L.E. Cain, A. Justice, J. Tate, R. Logan, C. Sabin, A. Winston, A. van Sighem, J.M. Miro, D. Podzamczar, A. Olson, J.R. Arribas, S. Moreno, L. Meyer, J. del Romero, F. Dabis, H.C. Bucher, G. Wandeler, G. Vourli, A. Skoutelis, E. Lanoy, J. Gasnault, D. Costagliola, and M.A. Hernán, on behalf of the HIV-CAUSAL Collaboration
Editorial, p. 109

- 142 Utility and safety of rituximab in pediatric autoimmune and inflammatory CNS disease
R.C. Dale, F. Brilot, L.V. Duffy, M. Twilt, A.T. Waldman, S. Narula, E. Muscal, K. Deiva, E. Andersen, M.R. Eyre, D. Eleftheriou, P.A. Brogan, R. Kneen, G. Alper, B. Anlar, E. Wassmer, K. Heineman, C. Hemingway, C.J. Riney, A. Kornberg, M. Tardieu, A. Stocco, B. Banwell, M.P. Gorman, S.M. Benseler, and M. Lim
  **Editorial, p. 111**
- 151 Variations in EEG discharges predict ADHD severity within individual Smith-Lemli-Opitz patients
J.M. Schreiber, D.C. Lanham, W.H. Trescher, S.E. Sparks, C.A. Wassif, B.S. Caffo, F.D. Porter, E. Tierney, A.L. Gropman, and J.B. Ewen
- 157 Comment: EEGs not likely helpful for behavioral assessments in Smith-Lemli-Opitz
D.L. Gilbert
- 160 Early developmental trajectories associated with ASD in infants with tuberous sclerosis complex
S.S. Jeste, J.Y. Wu, D. Senturk, K. Varcin, J. Ko, B. McCarthy, C. Shimizu, K. Dies, V. Vogel-Farley, M. Sahin, and C.A. Nelson III

- 169 Small strokes causing severe vertigo: Frequency of false-negative MRIs and nonlacunar mechanisms
A.S. Saber Tehrani, J.C. Kattah, G. Mantokoudis, J.H. Pula, D. Nair, A. Blitz, S. Ying, D.F. Hanley, D.S. Zee, and D.E. Newman-Toker

- 174 Factors associated with unfavorable outcome in minor ischemic stroke
S. Sato, T. Uehara, T. Ohara, R. Suzuki, K. Toyoda, and K. Minematsu, for the Stroke Unit Multicenter Observational (SUMO) Study Investigators
- 182 Microinfarct disruption of white matter structure: A longitudinal diffusion tensor analysis
E. Auriel, B.L. Edlow, Y.D. Reijmer, P. Fotiadis, S. Ramirez-Martinez, J. Ni, A.K. Reed, A. Vashkevich, K. Schwab, J. Rosand, A. Viswanathan, O. Wu, M.E. Gurol, and S.M. Greenberg

GLOBAL PERSPECTIVES

- 189 European Database for Myasthenia Gravis: A model for an international disease registry
B. Fulvio and R. Mantegazza

CONTINUED

Neurology[®]

Table of Contents

continued



CLINICAL/SCIENTIFIC NOTES

- 192 Improvement of internuclear ophthalmoparesis in multiple sclerosis with dalfampridine
A. Serra, M.M. Skelly, J.B. Jacobs, M.F. Walker, and J.A. Cohen



REFLECTIONS: NEUROLOGY AND THE HUMANITIES

- 195 A Soliloquy in LP Humility
Z. Ahmed

NEUROIMAGES

- 196 Pseudo tethered cord: An unusual complication of lumbar puncture
H. Ogul, B. Genc, and M. Kantarci

RESIDENT & FELLOW SECTION

- e12 Opinion & Special Articles: Professionalism in neurology: Maintaining patient rapport in a world of EMR
G. Dalla Costa, S. Maida, P. Sorrentino, M. Braunstein, G. Comi, and V. Martinelli
- e16 Pearls & Oy-sters: Bilateral thalamic involvement in West Nile virus encephalitis
J.C. Guth, S.A. Futterer, T.A. Hijaz, E.M. Liotta, N.F. Rosenberg, A.M. Naidech, and M.B. Maas
- e18 Teaching NeuroImages: Reversible pontomesencephalic edema caused by traumatic carotid cavernous fistula
Y.J. Alderazi, S. Dharmadhikari, D.C. Haussen, and D.R. Yavagal

WRITECLICK: EDITOR'S CHOICE

- 198 Sonographic diagnosis of true neurogenic thoracic outlet syndrome
C.A. Selmonosky; Author Response: N.G. Simon, J.W. Ralph, M. Kliot
- 198 Revised diagnostic criteria for the pseudotumor cerebri syndrome in adults and children
M. Wall, J.J. Corbett; Author Response: D.I. Friedman, G. Liu, K. Digre

CORRECTION

- 200 Hemodynamic Changes Associated with Interictal Epileptiform Activities Using Simultaneous Video Electro-encephalography (EEG)/Near Infrared Spectroscopy (NIRS) in Patient Self Control Study (P4.330)

CORRECTED AND REPUBLISHED ARTICLES

- e19 Structural and functional brain connectivity in presymptomatic familial frontotemporal dementia
E.G.P. Dopper, S.A.R.B. Rombouts, L.C. Jiskoot, T. den Heijer, J.R.A. de Graaf, I. de Koning, A.R. Hammerschlag, H. Seelaar, W.W. Seeley, I.M. Veer, M.A. van Buchem, P. Rizzu, and J.C. van Swieten
- e27 Herpes zoster as a risk factor for stroke and TIA: A retrospective cohort study in the UK
J. Breuer, M. Pacou, A. Gautier, and M.M. Brown

OPEN

AAN ANNUAL MEETING ABSTRACTS

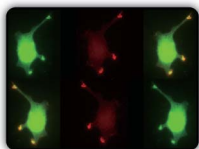
- e34 2014 Emerging Science Abstracts

DEPARTMENT

- A31 In the Next Issue of *Neurology*[®]

Podcast at Neurology.org CME Video Patient Page LOE classification LOE recommendation

Find us on Facebook tinyurl.com/neurologyfan twitter twitter.com/GreenJournal



Cover image: Subcellular localization of anti-moesin and serum immunofluorescence staining of YST-1 schwannoma cells in a patient with cytomegalovirus-related Guillain-Barré syndrome. Image stylized by Cindy Abair, *Neurology* Senior Graphics Editor. See page 113.

Look for **Publish Ahead of Print** articles and editorials under the Ahead of Print tab at Neurology.org

Neurology[®]

83 (2)

Neurology 2014;83:e18-200

This information is current as of January 1, 2014

Updated Information & Services

including high resolution figures, can be found at:
<http://n.neurology.org/content/83/2.full>

Permissions & Licensing

Information about reproducing this article in parts (figures, tables) or in its entirety can be found online at:
http://www.neurology.org/about/about_the_journal#permissions

Reprints

Information about ordering reprints can be found online:
<http://n.neurology.org/subscribers/advertise>

Neurology® is the official journal of the American Academy of Neurology. Published continuously since 1951, it is now a weekly with 48 issues per year. Copyright . All rights reserved. Print ISSN: 0028-3878. Online ISSN: 1526-632X.

