

International Issues: Acute ischemic stroke

An international experience

Meaghan Colling, MD
Vasileios-Arsenios
Lioutas, MD
Vaishnav Krishnan, MD,
PhD

Correspondence to
Dr. Krishnan:
vkrish@bidmc.harvard.edu

Mr. Q, a 72-year-old right-handed man with hypertension, hyperlipidemia, recurrent angina, and a 30 pack-year smoking history is a retired scientist living in the United States with his wife. He recently visited his native country, Ukraine, for the first time in almost 30 years. After an emotional day with family members, he returned home and suddenly became diaphoretic and weak, and ultimately lost consciousness. His wife drove him to the nearest open medical clinic. Because it was severely underresourced, he was then emergently taken by ambulance to a larger hospital 6 hours away. He regained consciousness by the time he arrived at this second hospital. After he was examined, his wife was told that, as a consequence of an acute stroke, her husband would no longer be able to move the left side of his body or produce speech. The physician explained that nothing could be done because the pharmacy was closed and that Mr. Q might not survive. His wife insisted that she could “pay with dollars” and that the pharmacy be opened. The physician then provided her with a list of 3 medications, which she obtained at this pharmacy (after it opened at her insistence) and swiftly brought back to the hospital. She described how her husband received a yellow powder that was then mixed in saline and administered IV. The second and third medications were clear liquids delivered IV and subcutaneously, respectively. Mr. Q also received IV fluids, and over the next 2 hours, the patient’s strength and language functions recovered to baseline. He continued to receive care at this hospital and received his first head CT scan on his fourth hospital day. Upon discharge, he and his wife quickly flew back to the United States.

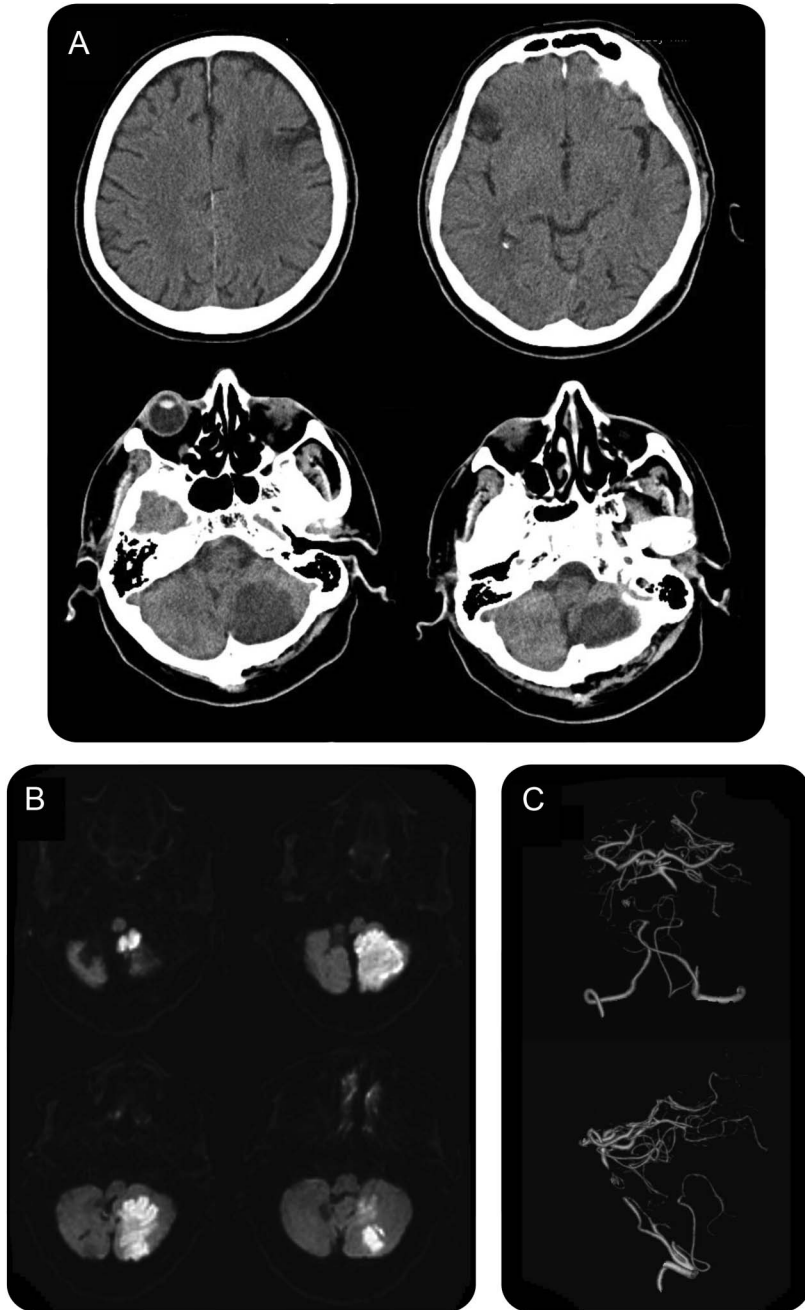
Mr. and Mrs. Q presented to our emergency room the following day. Armed with a file of hospital documents in Ukrainian and a compact disc containing his CT scan, Mrs. Q eloquently described the recent turn of events. She was particularly upset and embarrassed by the quality of care that her husband had received back home. Mr. Q’s neurologic examination was completely normal. We were able to view his original CT scan (figure, A), and identified at least 3 hypodensities suggestive of prior stroke. Concerned that

his stroke workup was incomplete, we admitted him to our inpatient service. MRI confirmed that he had indeed sustained an acute infarction of the left posterior inferior cerebellar artery territory just a few days prior (figure, B), and a CT angiogram demonstrated an occluded basilar artery, with a robust collateral system indicative of a chronic occlusion (figure, C). Outpatient Holter monitoring identified numerous episodes of paroxysmal atrial fibrillation, and the patient was started on warfarin.

Mr. Q’s story exemplifies a crisis in international stroke care. Many economically advantaged regions of the world such as the United States have stroke protocols, with access to rapid CTs and tissue plasminogen activator (tPA) readily available. In these regions, academic medical centers are also furnished with stroke units, staffed by skilled nurses who specialize in the care of this patient population. These health care services are not available globally, particularly in nations where the incidence of stroke is increasing. While there has been a 42% reduction in stroke incidence in high-income countries over the past 4 decades, there has been a greater than 2-fold increase in the incidence rates of stroke in low- to middle-income countries.¹ The increased incidence may be partially explained by changes in the epidemiology of traditional stroke risk factors, such as in the case of sub-Saharan Africa, where stroke caused by hypertension is now a major cause of premature death.² Rates of stroke-associated disability and mortality are highest in those countries with the lowest national income, with mortality decreasing by 4% for every additional US \$1,000 in per-capita gross national income.³ Developing countries with lower incomes will continue to bear a disproportionately greater fraction of the global burden of stroke as long as the complicated barriers contributing to these disparities remain poorly addressed. Poor public awareness of the symptoms of stroke and the importance of the time window for acute therapy are critical “prehospital” barriers. Poor infrastructure also contributes, because patient transportation systems are often limited and functional CT scanners unavailable or only available on select days of the week. Financial barriers

From Harvard Medical School (M.C.), Boston; and Department of Neurology (V.-A.L., V.K.), Beth Israel Deaconess Medical Center, Boston, MA. Go to Neurology.org for full disclosures. Funding information and disclosures deemed relevant by the authors, if any, are provided at the end of the article.

Figure Results from neuroimaging studies of Mr. Q demonstrating an ischemic stroke in the left cerebellum



(A) Noncontrast CT scan obtained 4 days after Mr. Q's acute loss of consciousness episode identifying bifrontal hypodensities as well as a left cerebellar hypodensity suggestive of subacute stroke. (B) Diffusion-weighted MRI obtained approximately 6 days after the event identifying an acute infarction of the left cerebellar hemisphere. (C) CT angiography-guided 3-dimensional reconstructed images of the vertebrobasilar system identifying a midbasilar occlusion.

are perhaps the most significant. Health care budget allocations in developing nations are low, such that the costs of tPA (approximately US \$1,400) are often not covered by governmental health care.⁴ These costs ultimately have to be borne by patients themselves, leaving many tPA-eligible patients without treatment and limiting the use of thrombolytic

therapy to private sector hospitals.^{4,5} These problems support the need for a global endeavor to aggressively address stroke risk factors in low- to middle-income countries as well as to identify funding sources to overcome these barriers to providing rapid stroke care.

What were those 3 medications that Mrs. Q had heroically acquired? Given the speed of his recovery, we wondered whether he had received tPA, and perhaps an IV antihypertensive agent and/or mannitol. On our request, Mrs. Q provided us with that very sheet of paper that contained the 3 drugs inscribed in a foreign script. We were quite surprised to learn that the 3 medications were in fact dexamethasone, citicoline, and L-lysine aescinate. Despite its known effects in ameliorating cerebral edema, clinical studies conducted before the 1980s demonstrated dexamethasone's lack of efficacy in the treatment of acute ischemic stroke (particularly among patients with a depressed level of consciousness). These publications uniformly used small, poorly randomized cohorts of patients, and were conducted at a time when CSF analysis was needed to distinguish between ischemic and hemorrhagic stroke.⁶ There have been no newer large randomized studies examining the role of dexamethasone in acute ischemic stroke. Citicoline is an exogenously administered form of a membrane phospholipid precursor that showed promising effects in preclinical testing, but failed to show significant benefits in a recent large multicenter randomized controlled trial.⁷ However, like most modern neuroprotectant trials, this study enrolled patients that presented to "stroke centers" with well-equipped emergency departments and almost half of these patients received tPA, a scenario vastly different from Mr. Q's experience. L-Lysine aescinate is commercially available in some countries as a medication to combat edema, but there are no English-language publications on the use of this medication in acute stroke. Finally, Mr. Q was treated with IV fluids. We were not able to find any trials examining the role of IV fluids in the treatment of acute ischemic stroke. However, a number of retrospective studies have demonstrated that patients with TIAs or strokes display a high incidence of dehydration (as measured by plasma osmolality), and that this is exacerbated by diuretic intake and dysphagia, and leads to poorer outcome,^{8,9} suggesting that at least a proportion of patients with acute ischemic stroke may benefit from volume repletion.

While Mrs. Q was thankful for our efforts to shed light on the recent turn of events, she was a little upset to learn that we would not continue to administer these 3 medications to her husband to prevent future strokes. Fortunately for Mr. Q, he had experienced a good outcome and was able to travel back to the

United States and receive follow-up care. Our team spent time reflecting on how we would react if a loved one was to experience a stroke in a similar setting. Neuroimaging results several days later confirmed the presence of a large cerebellar ischemic stroke without any associated hemorrhage. However, because of the unavailability of a CT scanner at the time of his initial presentation, Mr. Q's physicians could not have ruled out a hemorrhagic stroke, and tPA would have been contraindicated. Thus, if citicoline or dexamethasone was all that was available, would we also insist on administering these medications emergently?

While efforts to overcome socioeconomic and educational barriers to appropriate tPA use are paramount, these efforts are futile and inapt for countries where the safe storage and use of tPA remains prohibitively expensive. Instead, our efforts should focus on stroke prevention as a more cost-effective means to address global disparities in stroke disability and mortality, particularly with regard to addressing hypertension.¹⁰ In conjunction with these preventative strategies, we should develop the means to provide standardized high-quality acute stroke care in technologically underdeveloped settings using cheap treatment strategies. Our case also suggests the need to reevaluate the efficacy of previously studied neuroprotective therapies, specifically in rural regions of the world, where their relative benefit may be the greatest.

AUTHOR CONTRIBUTIONS

Meaghan Colling: drafting/revising the manuscript, study concept or design, analysis or interpretation of data, accepts responsibility for conduct of research and will give final approval. Vasileios-Arsenios Lioutas: drafting/revising the manuscript, study concept or design, accepts responsibility for conduct of research and will give final approval, study supervision. Vaishnav Krishnan: drafting/revising the manuscript, accepts responsibility for conduct of research and will give final approval.

STUDY FUNDING

No targeted funding reported.

DISCLOSURE

The authors report no disclosures relevant to the manuscript. Go to Neurology.org for full disclosures.

REFERENCES

1. Feigin VL, Lawes CM, Bennett DA, Barker-Collo SL, Parag V. Worldwide stroke incidence and early case fatality reported in 56 population-based studies: a systematic review. *Lancet Neurol* 2009;8:355–369.
2. Ntsekhe M, Damasceno A. Recent advances in the epidemiology, outcome, and prevention of myocardial infarction and stroke in sub-Saharan Africa. *Heart* 2013;99:1230–1235.
3. Johnston SC, Mendis S, Mathers CD. Global variation in stroke burden and mortality: estimates from monitoring, surveillance, and modelling. *Lancet Neurol* 2009;8:345–354.
4. Ghandehari K. Barriers of thrombolysis therapy in developing countries. *Stroke Res Treat* 2011;2011:686797.
5. Nandigam K, Narayan SK, Elangovan S, Dutta TK, Sethuraman KR, Das AK. Feasibility of acute thrombolytic therapy for stroke. *Neurol India* 2003;51:470–473.
6. Bauer RB, Tellez H. Dexamethasone as treatment in cerebrovascular disease: 2: a controlled study in acute cerebral infarction. *Stroke* 1973;4:547–555.
7. Davalos A, Alvarez-Sabin J, Castillo J, et al. Citicoline in the treatment of acute ischaemic stroke: an international, randomised, multicentre, placebo-controlled study (ICTUS trial). *Lancet* 2012;380:349–357.
8. Bhalla A, Sankaralingam S, Dundas R, Swaminathan R, Wolfe CD, Rudd AG. Influence of raised plasma osmolality on clinical outcome after acute stroke. *Stroke* 2000;31:2043–2048.
9. Rodriguez GJ, Cordina SM, Vazquez G, et al. The Hydration Influence on the Risk of Stroke (THIRST) Study. *Neurocrit Care* 2009;10:187–194.
10. Morgenstern LB, Smith WS. Setting priorities for stroke care and research. *Int J Stroke* 2013;8:445–446.

Neurology®

International Issues: Acute ischemic stroke: An international experience

Meaghan Colling, Vasileios-Arsenios Lioutas and Vaishnav Krishnan

Neurology 2014;83:e174-e176

DOI 10.1212/WNL.0000000000000956

This information is current as of November 3, 2014

Updated Information & Services	including high resolution figures, can be found at: http://n.neurology.org/content/83/19/e174.full
References	This article cites 10 articles, 3 of which you can access for free at: http://n.neurology.org/content/83/19/e174.full#ref-list-1
Subspecialty Collections	This article, along with others on similar topics, appears in the following collection(s): All Cerebrovascular disease/Stroke http://n.neurology.org/cgi/collection/all_cerebrovascular_disease_stroke Cost effectiveness/economic http://n.neurology.org/cgi/collection/cost_effectiveness_economic_outcome_research Outcome research http://n.neurology.org/cgi/collection/outcome_research Quality of life http://n.neurology.org/cgi/collection/quality_of_life Stroke prevention http://n.neurology.org/cgi/collection/stroke_prevention
Permissions & Licensing	Information about reproducing this article in parts (figures, tables) or in its entirety can be found online at: http://www.neurology.org/about/about_the_journal#permissions
Reprints	Information about ordering reprints can be found online: http://n.neurology.org/subscribers/advertise

Neurology® is the official journal of the American Academy of Neurology. Published continuously since 1951, it is now a weekly with 48 issues per year. Copyright © 2014 American Academy of Neurology. All rights reserved. Print ISSN: 0028-3878. Online ISSN: 1526-632X.

