



In Focus

Spotlight on the July 1 Issue

Robert A. Gross, MD, PhD, FAAN
Editor-in-Chief, *Neurology*[®]



Quantitative analysis of dietary protein intake and stroke risk

The association between dietary protein intake and stroke risk remains inconsistent. This meta-analysis involving 254,489 participants provides evidence that protein intake was independently associated with a decreased risk of stroke, indicating that moderate dietary protein intake may lower stroke risk.

See p. 19; Editorial, p. 13

Recurrent thromboembolic events after ischemic stroke in patients with cancer

The authors identified 263 patients with active systemic cancer diagnosed with acute ischemic stroke at a cancer center. Despite a median survival of 84 days, 90 patients had 117 recurrent thromboembolic events. Patients with acute ischemic stroke with active cancer faced a substantial short-term risk of recurrent stroke and other types of thromboembolism.

See p. 26

From editorialist Robert M. Starke: "The authors should be commended for highlighting this important subject because it underscores the risk of recurrent thromboembolic events in these patients and will help define the most appropriate management strategies."

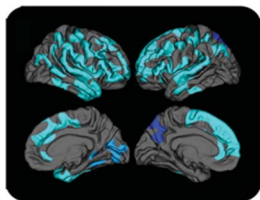
See p. 15

Genetic risk load according to the site of intracranial aneurysms

Intracranial aneurysms (IAs) are clinically heterogeneous, but their genetic heterogeneity is largely unknown. The authors counted known IA risk alleles in 1,691 patients with different characteristics, finding a higher genetic load in patients with IA at the middle cerebral artery. This suggests a larger role for genetic factors at this location.

See p. 34

Vascular risk and A β interact to reduce cortical thickness in AD vulnerable brain regions



The presence of A β was assessed using [¹¹C] Pittsburgh compound B-PET imaging and was correlated to cortical thickness in 66 cognitively normal and mildly impaired older individuals. Vascular risk and A β have a synergistic negative effect on cortical thickness in posterior (especially

parietal) brain regions that are particularly vulnerable to Alzheimer disease.

See p. 40

Automated detection of cortical dysplasia type II in MRI-negative epilepsy

The absence of a visible lesion is one of the greatest challenges in epileptology. This automated classifier detected focal cortical dysplasia in cases initially diagnosed as MRI-negative on routine radiologic inspection. By facilitating the a priori hypothesis about the epileptogenic zone, machine learning made surgery accessible to more patients.

See p. 48; Comment, p. 54

Frontal cortex BOLD signal changes in premanifest Huntington disease: A possible fMRI biomarker

Sixteen persons with premanifest Huntington disease and 18 healthy participants had anatomical and fMRI acquisitions during the execution of the exogenous covert orienting of attention task. fMRI activations in the right-frontal oculomotor cortex during inhibition of return may be a functional imaging biomarker in premanifest Huntington disease.

See p. 65; Comment, p. 71

Long-term safety and effectiveness of natalizumab redosing and treatment in the STRATA MS Study

Patients previously enrolled in natalizumab trials were followed with neurologic assessments, and adverse events were noted. Relapse rates in treated patients remained low with little change in disability; however, several cases of progressive multifocal leukoencephalopathy (PML) emerged. Natalizumab is effective in long-term use but the major adverse event requiring constant vigilance is the emergence of PML.

See p. 78

VIEWS & REVIEWS

Alemtuzumab: The advantages and challenges of a novel therapy in MS

This review analyzes the differential reconstitution of T and B cells to treat autoimmune conditions. Alemtuzumab is a humanized monoclonal antibody that rapidly depletes CD52⁺ cells from peripheral blood but spares lymphoid precursor cells. This new drug will be positioned for treating active relapsing-remitting MS, enlarging our therapeutic armamentarium.

See p. 87

NB: "Low-flow vascular malformation: Contribution of sequential postcontrast MRI acquisitions," see p. 100. To check out other NeuroImages, point your browser to Neurology.org.

Podcasts can be accessed at Neurology.org

Neurology[®]

Spotlight on the July 1 Issue

Robert A. Gross

Neurology 2014;83;1

DOI 10.1212/WNL.0000000000000561

This information is current as of June 30, 2014

Updated Information & Services

including high resolution figures, can be found at:
<http://n.neurology.org/content/83/1/1.full>

Permissions & Licensing

Information about reproducing this article in parts (figures, tables) or in its entirety can be found online at:
http://www.neurology.org/about/about_the_journal#permissions

Reprints

Information about ordering reprints can be found online:
<http://n.neurology.org/subscribers/advertise>

Neurology® is the official journal of the American Academy of Neurology. Published continuously since 1951, it is now a weekly with 48 issues per year. Copyright © 2014 American Academy of Neurology. All rights reserved. Print ISSN: 0028-3878. Online ISSN: 1526-632X.

