

Neurology[®]

Table of Contents

Volume 83, Number 1, July 1, 2014

Neurology.org

THE MOST WIDELY READ AND HIGHLY CITED PEER-REVIEWED
NEUROLOGY JOURNAL



IN FOCUS

- 1 Spotlight on the July 1 Issue
- 77 This Week's *Neurology*[®] Podcast

EDITORIAL MESSAGE

- 2 Publishing rigor: An extension of scientific rigor: Minding the business of scientific reporting
P.K. Baskin and R.A. Gross


ACKNOWLEDGMENT TO REVIEWERS

- 4 Message from the Editors to our Reviewers
R.A. Gross, D.S. Knopman, A.A. Amato, G.D. Cascino, O. Ciccarelli, J.R. Corboy, M.S.V. Elkind, J.W. Mink, R.M. Ransohoff, R.J. Uitti, and B.B. Worrall


EDITORIALS

- 13 Dietary protein and stroke prevention: Is the Eskimo diet the answer to avoid stroke?
A. Tamayo and L. Castilla-Guerra
- 15 Risk of recurrent thromboembolic phenomena after ischemic stroke in patients with malignancy
R.M. Starke
- 17 Alemtuzumab and multiple sclerosis: Is it safe?
D. Bourdette


ARTICLES

- 19 Quantitative analysis of dietary protein intake and stroke risk
Z. Zhang, G. Xu, F. Yang, W. Zhu, and X. Liu
Editorial, p. 13
- 26 Recurrent thromboembolic events after ischemic stroke in patients with cancer
B.B. Navi, S. Singer, A.E. Merkle, N.T. Cheng, J.B. Stone, H. Kamel, C. Iadecola, M.S.V. Elkind, and L.M. DeAngelis
 **Editorial, p. 15**
- 34 Genetic risk load according to the site of intracranial aneurysms
F.N.G. van 't Hof, M.I. Kurki, R. Kleinloog, P.I.W. de Bakker, M. von und zu Fraunberg, J.E. Jääskeläinen, E.I. Gaál, H. Lehto, R. Kivisaari, A. Laakso, M. Niemelä, J. Hernesniemi, M.C. Brouwer, D. van de Beek, G.J.E. Rinkel, and Y.M. Ruigrok

- 40 Vascular risk and A β interact to reduce cortical thickness in AD vulnerable brain regions
S. Villeneuve, B.R. Reed, C.M. Madison, M. Wirth, N.L. Marchant, S. Kriger, W.J. Mack, N. Sanossian, C. DeCarli, H.C. Chui, M.W. Weiner, and W.J. Jagust

- 48 Automated detection of cortical dysplasia type II in MRI-negative epilepsy
S.-J. Hong, H. Kim, D. Schrader, N. Bernasconi, B.C. Bernhardt, and A. Bernasconi



- 54 Comment: Has automated detection of cortical dysplasias come of age?
S. Wiebe

- 56 Spectrogram screening of adult EEGs is sensitive and efficient
L.M.V.R. Moura, M.M. Shafi, M. Ng, S. Pati, S.S. Cash, A.J. Cole, D.B. Hoch, E.S. Rosenthal, and M.B. Westover



- 65 Frontal cortex BOLD signal changes in premanifest Huntington disease: A possible fMRI biomarker
S. Ferraro, L. Nanetti, S. Piacentini, M.L. Mandelli, N. Bertolino, F. Ghielmetti, F. Epifani, M.G. Bruzzone, M. Savoardo, C. Mariotti, and M. Grisoli

- 71 Comment: fMRI biomarker for premanifest HD?
J.S. Perlmutter

- 73 Dynamic formation of macular microcysts independent of vitreous traction changes
A.U. Brandt, T. Oberwahrenbrock, E.M. Kadas, W.A. Lagrèze, and F. Paul

- 78 Long-term safety and effectiveness of natalizumab redosing and treatment in the STRATA MS Study
P. O'Connor, A. Goodman, L. Kappos, F. Lublin, C. Polman, R.A. Rudick, K. Hauswirth, L.M. Cristiano, F. Forrester, and P. Duda


VIEWS & REVIEWS

- 87 Alemtuzumab: The advantages and challenges of a novel therapy in MS
T. Menge, O. Stüve, B.C. Kieseier, and H.-P. Hartung
 **Editorial, p. 17**

CONTINUED

Neurology[®]

Table of Contents

continued



CLINICAL/SCIENTIFIC NOTES

- 98 Inclusion body myositis and chronic lymphocytic leukemia: A case series
E.H. Beck, A.A. Amato, and S.A. Greenberg

NEUROIMAGES

- 100 Low-flow vascular malformation: Contribution of sequential postcontrast MRI acquisitions
O. Heck, A. Krainik, K. Boubagra, F. Tahon, A. Attye, J.F. Le Bas, J. Boutonnat, and S. Grand

RESIDENT & FELLOW SECTION

- e1 Clinical Reasoning: A 69-year-old man with leukocytosis and hemorrhagic brain lesions
K.M. Scott, F.P. Gardner, B.H. Eidelman, C.E. Rivera, D.M. Menke, and K.M. Barrett
- e6 Clinical Reasoning: Progressive visuospatial problems in a 71-year-old man
M. Symmonds, W. Küker, and U.G. Schulz

- e11 Teaching NeuroImages: Macaroni sign
T. Siepmann and U. Bodechtel

WRITECLICK: EDITOR'S CHOICE

- 102 Higher glucose levels associated with lower memory and reduced hippocampal microstructure
L.B. Grabenhenrich, S. Roll; Author Response: L. Kerti, A.V. Witte, U. Grittner, A. Floeel
- 102 Gait speed in Parkinson disease correlates with cholinergic degeneration
W.M. Landau; Author Response: N.I. Bohnen, V. Kotagal, R. Albin, M. Muller

CORRECTION

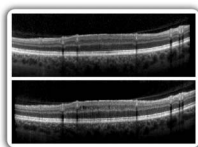
- 103 The Effects of Salsa Dance on Gait and Balance in Multiple Sclerosis (P3.053)

DEPARTMENT

- A28 In the Next Issue of *Neurology*[®]

Podcast at Neurology.org CME Video Patient Page LOE classification LOE recommendation

Find us on Facebook tinyurl.com/neurologyfan twitter twitter.com/GreenJournal



Cover image: OCT B-scans through macular microcystic areas of a patient with chronic relapsing inflammatory optic neuropathy. See page 73.

Look for **Publish Ahead of Print** articles and editorials under the Ahead of Print tab at Neurology.org

Neurology®

83 (1)

Neurology 2014;83:e11-103

This information is current as of January 1, 2014

Updated Information & Services

including high resolution figures, can be found at:
<http://n.neurology.org/content/83/1.full>

Permissions & Licensing

Information about reproducing this article in parts (figures, tables) or in its entirety can be found online at:
http://www.neurology.org/about/about_the_journal#permissions

Reprints

Information about ordering reprints can be found online:
<http://n.neurology.org/subscribers/advertise>

Neurology® is the official journal of the American Academy of Neurology. Published continuously since 1951, it is now a weekly with 48 issues per year. Copyright . All rights reserved. Print ISSN: 0028-3878. Online ISSN: 1526-632X.

