

Pearls & Oysters: Clues to the diagnosis of adult-onset acid maltase deficiency

Tania B. Beltran Papsdorf,
MD
James F. Howard, Jr.,
MD
Nizar Chahin, MD

Correspondence to
Dr. Chahin:
chahinn@neurology.unc.edu

PEARLS Adult-onset Pompe disease (acid maltase deficiency, glycogen storage disease type II) should be considered in the differential diagnosis in the adult patient presenting with slowly progressive selective lower extremity weakness, specifically of the hip flexors. Hip flexion weakness may be the only finding in the earliest stages of this disease. EMG findings of myotonic discharges occurring predominantly in the lower extremities or paraspinal muscles, in combination with the clinical presentation, are a clue to the diagnosis of late-onset Pompe disease. Testing of all 3 paraspinal muscle levels may be useful in an otherwise unrevealing EMG when Pompe disease is suspected.

OY-STERS The lack of respiratory insufficiency should not dissuade the clinician from considering the diagnosis of late-onset Pompe disease. Further, the muscle biopsy can be nonspecific or even normal if sampling from a mildly affected muscle.¹ While a vacuolar myopathy with accumulation of glycogen is a classic feature, this is not always the case. Common misdiagnoses include adult-onset spinal muscular atrophy (SMA) and certain muscular dystrophies because of the selective involvement of the lower limbs.

PATIENT 1 A 58-year-old woman began to have symptoms at age 44 of slowly progressive proximal muscle weakness predominantly affecting the lower limbs. She had difficulty climbing stairs and standing from a seated position. She had undergone evaluation that included a muscle biopsy of the left thigh at age 46 demonstrating denervation atrophy. Genetic testing for SMA genes I, II, and III was negative and she was diagnosed with SMA type IV. The muscle had been stained for periodic acid–Schiff (PAS) and acid phosphatase and was normal. Her creatine kinase (CK) level at presentation had been elevated as high as 429 U/L (normal range 45–145) but was normal at the time of diagnosis. There was no family history of muscle disease. On examination, there was weakness of hip flexion 2–3/5, hip abduction 2/5, and hip adduction 2/5 (Medical Research Council score). EMG performed at our institution demonstrated

spontaneous activity with myotonic discharges in the lumbar paraspinals, vastus medialis, and tensor fasciae latae muscles. Myopathic changes without spontaneous activity at rest or myotonic discharges were present in other muscles, including the thoracic paraspinal muscles. Glucosidase- α acid (GAA) enzyme activity assay was 1 (normal range 10–49 pmol/punch/h). She was found to have 2 heterozygous mutations, c.-32-13T>G and c.525delT, in the *GAA* gene.

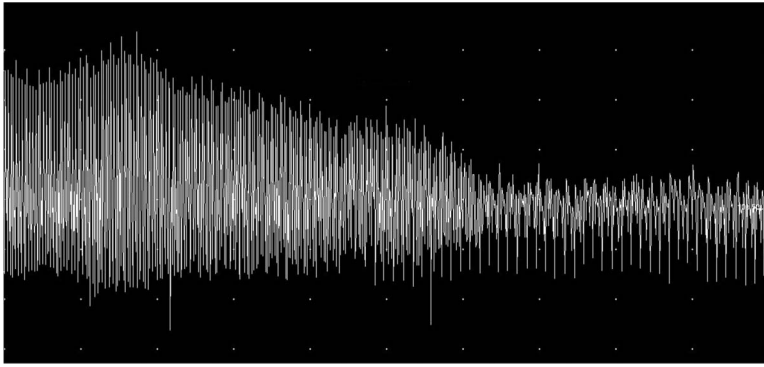
PATIENT 2 A 71-year-old man began to have slowly progressive proximal lower limb muscle weakness at age 51. His symptoms began with difficulty climbing stairs. He was diagnosed at age 52 with SMA type III following an EMG reporting neurogenic changes and a muscle biopsy from a hamstring muscle that demonstrated denervation atrophy. Staining for PAS and acid phosphatase was normal. Genetic testing for SMA was not performed. Serum CK was 208 U/L (normal range 70–185). There was no family history of muscle disease. On examination, there was normal strength in the upper extremities with moderate weakness of hip flexion at 3/5, hip abduction 3–4/5, hip adduction 3–4/5, and hamstrings 4/5. He was referred to our EMG laboratory at age 71 for evaluation of a right lower limb radiculopathy. EMG showed myotonic discharges in the anterior tibialis, medial gastrocnemius, iliopsoas, tensor fasciae latae, and biceps brachii muscles. The paraspinal muscles were not examined as it was determined this would not add to the diagnosis. GAA activity was 1.3 (normal 10–49 pmol/punch/h) and he was found to have 2 heterozygous mutations at c.-32-13T>G and c.1841C>A in the *GAA* gene.

PATIENT 3 A 21-year-old athletic man was referred for evaluation of asymptomatic CK elevation, noted a year and half previously while undergoing evaluation for flu-like symptoms that were diagnosed as mononucleosis. He did not have any complaints of muscle weakness. He was found to have an elevated aspartate aminotransferase of 172 and alanine aminotransferase of 203 (normal ranges 19–55 and 19–72 I/U, respectively) but normal alkaline phosphatase and

From the Neuromuscular Disorders Section, Department of Neurology, The University of North Carolina at Chapel Hill.

Go to Neurology.org for full disclosures. Funding information and disclosures deemed relevant by the authors, if any, are provided at the end of the article.

Figure 1 Myotonic discharge from lumbar paraspinal muscle



Gain: 1 s/div, 50 μ V/div.

γ -glutamyl transpeptidase. Liver ultrasound and biopsy at an outside facility were normal. Serum CK was elevated at 1,373 U/L (normal range 70–185). There was no family history of muscle disease. His examination demonstrated a muscular man with mild weakness (4/5) of iliopsoas muscles. EMG performed at our institution demonstrated prominent myotonic discharges isolated to the lumbar paraspinal muscles. Iliopsoas, tensor fascia latae, and cervical and thoracic paraspinal muscles demonstrated myopathic changes without spontaneous activity or myotonic discharges. GAA level was 1.4 (normal range 10–49 pmol/punch/h) and he was found to have 2 heterozygous mutations, c.-32-13T>G and c.877G>A, in the GAA gene.

DISCUSSION Pompe disease (glycogen storage disease type II) is a deficiency of acid- α -glucosidase, an enzyme that degrades lysosomal glycogen. A deficiency of the enzyme leads to deposition of glycogen in the heart, skeletal, and respiratory muscles. In the infantile-onset form of the disease, symptoms present in the first month or year of life with hypotonia, macroglossia, generalized muscle weakness or delayed motor milestones, liver failure, feeding difficulties, failure to thrive, and respiratory distress, with or without cardiomegaly. There is progressive proximal muscle weakness and respiratory insufficiency without cardiac involvement in late-onset (i.e., childhood, juvenile, and adult-onset) Pompe disease. The muscle weakness predominantly affects the lower limbs and can be specific to the iliopsoas muscles. Presentation is usually in the second to the seventh decade of life.

Our patients demonstrate key diagnostic features that should lead the clinician to consider adult-onset Pompe disease early in the workup of a myopathy. This is important as enzyme replacement therapy is available. These key features include 1) predominant involvement of hip flexion weakness at

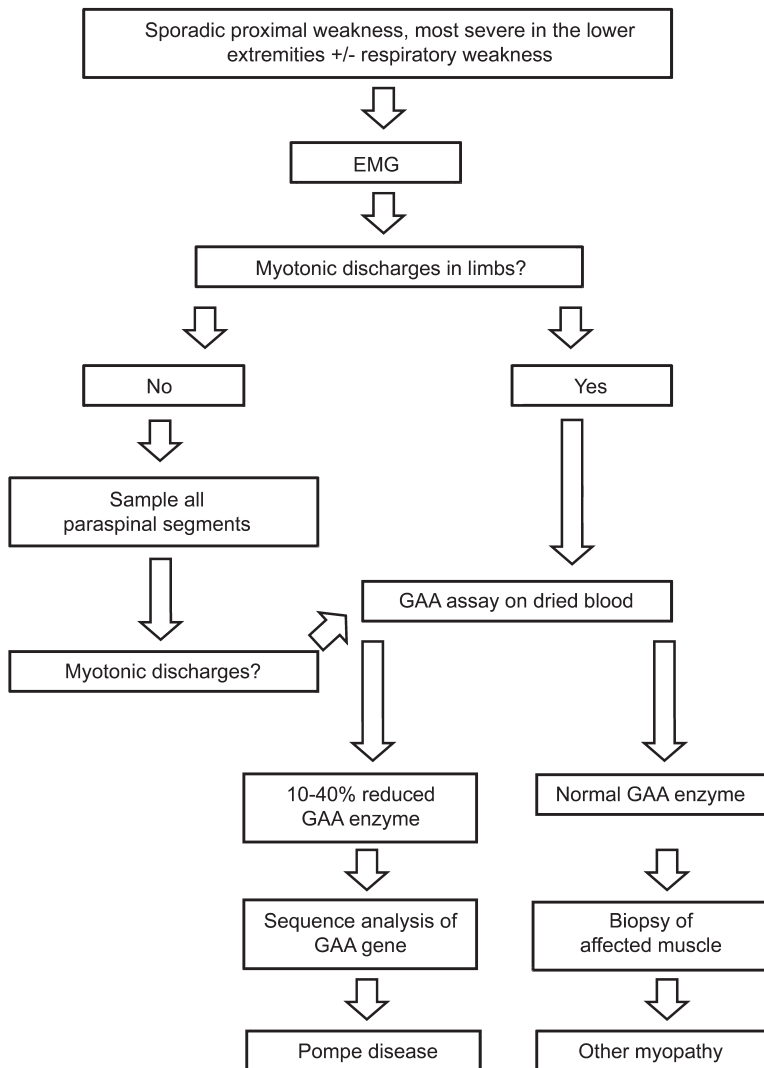
the onset of the disease; 2) EMG findings of myotonic discharges predominating in the lower extremities; and 3) isolated myotonic discharges to one or more paraspinal levels when EMG of the limb is unrevealing. Although myotonic discharges are nonspecific and can be seen in many disorders, including myotonic dystrophy, inflammatory myopathies, and some inherited myopathies, the presence of myotonic discharges (figure 1) in a specific distribution with the characteristic clinical features is highly suggestive of acid maltase deficiency. None of our patients presented with exercise-dependent weakness.

The clinical presentation of late-onset Pompe disease has been previously described as variable in presentation, laboratory values, and EMG patterns of abnormality.^{2,3} There are no reports regarding the electrophysiologic specificity of myotonic discharges isolated to the lower limbs despite the well-known involvement of lower extremity weakness. In an earlier case report of 4 patients with Pompe disease, extensive testing of muscles demonstrated that 3 of the 4 patients had myotonic discharges predominantly in the torso and proximal limb muscles.¹ Examination of our patients demonstrated the predilection of the disease to affect the lower extremities, particularly early in the course of the illness, and their EMG findings of myotonic discharges correlated well with the examination findings of predominantly lower extremity weakness.

Predominant findings of myotonic discharges in the paraspinal muscles in Pompe disease have been reported.^{4,5} However, we further recommend that all 3 paraspinal levels be sampled as one particular level may not be affected. Our third case demonstrates the importance of multilevel evaluation of the paraspinal muscles, especially when the EMG is otherwise unrevealing. A recent study that reviewed the clinical and neurophysiologic spectrum of 38 patients reported that 9% of the patients had a normal EMG.³ The study did not include paraspinal muscle evaluation of patients whose EMG was normal and therefore it is unknown whether myotonic discharges may have been present in the paraspinal muscles of these patients. There is a case report of a patient who presented with respiratory failure whose EMG was abnormal in only the thoracic paraspinal muscles and the patient was later found to have Pompe disease on muscle biopsy.⁶

It should also be noted that in our patients respiratory complaints were not part of their presentation and all had a normal forced vital capacity; therefore, the lack of respiratory muscle involvement should not guide the clinician away from this diagnosis. The association of respiratory insufficiency and degree of weakness or muscle involvement has been previously noted to have poor direct correlation.^{7,8} Muscle biopsy can be nonspecific in these patients,

Figure 2 Proposed laboratory approach for the diagnosis of late-onset acid maltase deficiency



GAA = glucosidase- α acid.

as illustrated in our first and second cases, where the biopsy demonstrated denervation atrophy. The first 2 cases presented were misdiagnosed as SMA, for which there is no treatment.

All of our patients were ambulatory at the time of their diagnosis; one used a walker and the other used a cane. Diagnosis at an early presentation may prove to be important with the advent of enzyme replacement. An algorithm (figure 2) is proposed to facilitate the diagnosis. There should be a high index of suspicion

for late-onset Pompe disease when predominant lower extremity weakness and myotonic discharges are noted on EMG examination as enzyme replacement is readily available and relatively inexpensive.

AUTHOR CONTRIBUTIONS

Tania Beatriz Beltran Papsdorf: drafting/revising the manuscript, accepts responsibility for conduct of research and final approval. James Francis Howard Jr.: drafting/revising the manuscript, study concept or design, analysis or interpretation of data, accepts responsibility for conduct of research and final approval, acquisition of data. Nizar Chahin: drafting/revising the manuscript, study concept or design, analysis or interpretation of data, accepts responsibility for conduct of research and final approval, study supervision.

STUDY FUNDING

No targeted funding reported.

DISCLOSURE

T. Beltran Papsdorf reports no disclosures. J. Howard is a consultant for Alexion Pharmaceuticals but receives no remuneration. Current grant support is from NIH, National Institute of Neurological Disorders and Stroke, NIAMS, the Myasthenia Gravis Foundation, and Cytokinetics, Inc. Previous research support in the last 2 years has been from Alexion Pharmaceuticals, Inc., and the American Urogynecologic Society. N. Chahin reports no disclosures. Go to Neurology.org for full disclosures.

REFERENCES

- Engel A. Acid maltase deficiency in adults: studies in four cases of a syndrome which may mimic muscular dystrophy or other myopathies. *Brain* 1970;93:599–616.
- Hagemans MLC, Winkel LPF, Van Doorn PA, et al. Clinical manifestation and natural course of late-onset Pompe's disease in 54 Dutch patients. *Brain* 2005;128:671–677.
- Müller-Felber W, Horvath R, Gempel K, et al. Late onset Pompe disease: clinical and electrophysiological spectrum of 38 patients including long-term follow-up in 18 patients. *Neuromuscul Disord* 2007;17:698–706.
- Barohn R, McVey A, DiMauro S. Adult acid maltase deficiency. *Muscle Nerve* 1993;16:672–676.
- Hobson-Webb LD, DeArmev S, Kishnani PS. The clinical and electrodiagnostic characteristics of Pompe disease with post-enzyme replacement therapy findings. *Clin Neurophysiol* 2011;122:2312–2317.
- Salem B, Thaisethawatkul P, Fernandes JA, McComb RD. Adult-onset acid maltase deficiency with isolated axial muscle involvement. *J Clin Neuromuscul Dis* 2010;12:30–35.
- Laforet P, Nicolino M, Eymard PB, et al. Juvenile and adult-onset acid maltase deficiency in France: genotype-phenotype correlation. *Neurology* 2000;55:1122–1128.
- Mellies U, Ragette R, Schwake C, Baethmann M, Voit T, Teschler H. Sleep-disordered breathing and respiratory failure in acid maltase deficiency. *Neurology* 1999;53:1648–1654.

Neurology®

Pearls & Oysters: Clues to the diagnosis of adult-onset acid maltase deficiency

Tania B. Beltran Papsdorf, James F. Howard, Jr and Nizar Chahin

Neurology 2014;82:e73-e75

DOI 10.1212/WNL.000000000000163

This information is current as of March 3, 2014

Updated Information & Services	including high resolution figures, can be found at: http://n.neurology.org/content/82/9/e73.full
References	This article cites 8 articles, 2 of which you can access for free at: http://n.neurology.org/content/82/9/e73.full#ref-list-1
Subspecialty Collections	This article, along with others on similar topics, appears in the following collection(s): Muscle disease http://n.neurology.org/cgi/collection/muscle_disease
Permissions & Licensing	Information about reproducing this article in parts (figures, tables) or in its entirety can be found online at: http://www.neurology.org/about/about_the_journal#permissions
Reprints	Information about ordering reprints can be found online: http://n.neurology.org/subscribers/advertise

Neurology® is the official journal of the American Academy of Neurology. Published continuously since 1951, it is now a weekly with 48 issues per year. Copyright © 2014 American Academy of Neurology. All rights reserved. Print ISSN: 0028-3878. Online ISSN: 1526-632X.

