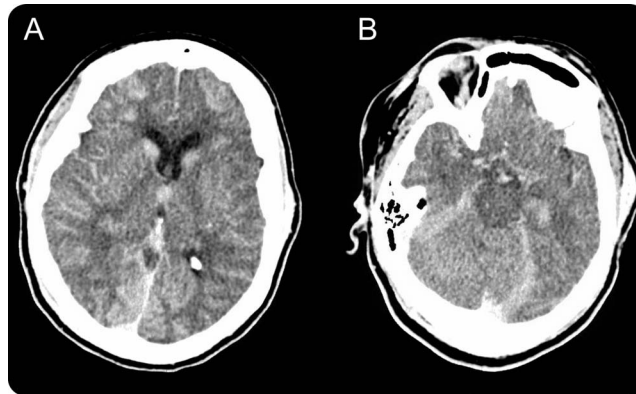


Teaching NeuroImages: “Subarachnoid hemorrhage” from decreased contrast elimination after therapeutic hypothermia

Wazim Mohamed, MD
Preet Varade, MD
Gregory M. Norris, MD

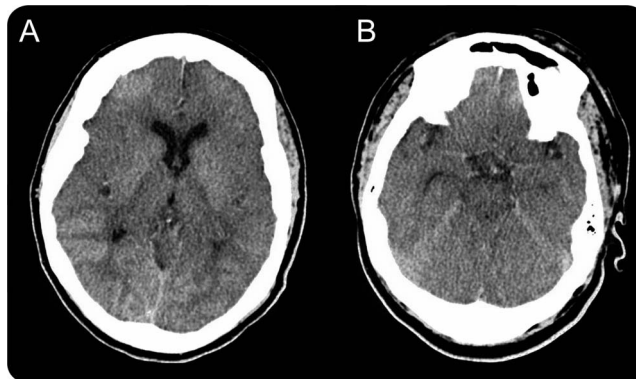
Correspondence to
Dr. Mohamed:
wmohamed@med.wayne.edu

Figure 1 CT at 24 hours



(A, B) Diffuse hyperattenuation in the subarachnoid space with relative sparing of the left lateral fissure.

Figure 2 CT at 48 hours



(A, B) Interval clearance of the hyperattenuation in the subarachnoid space.

A 50-year-old woman underwent therapeutic hypothermia after a witnessed cardiac arrest and cardiac catheterization. A 24-hour head CT (figure 1) showed diffuse hyperattenuation in the subarachnoid space and was reported as subarachnoid hemorrhage. Repeat CT at 48 hours (figure 2) showed significant clearing of the “subarachnoid hemorrhage.”

DISCUSSION Cerebrocirculatory arrest and reperfusion causes injury that breaks down the blood–brain

barrier.¹ In patients undergoing contrast imaging, there may be active extravasation of contrast into the subarachnoid space. Hypothermia alters contrast viscosity, decreases glomerular filtration, and subsequently decreases elimination of the contrast.² It is important to recognize such mimickers of subarachnoid hemorrhage in the era of hypothermia.

AUTHOR CONTRIBUTIONS

Dr. Wazim Mohamed: manuscript concept, design, research, and preparation. Dr. Preet Varade: manuscript preparation and preparation

Download teaching slides:
www.neurology.org

From the Division of Neurocritical Care, Department of Neurology, Wayne State University/Detroit Medical Center, MI.
Go to Neurology.org for full disclosures. Funding information and disclosures deemed relevant by the authors, if any, are provided at the end of the article.

of images. Dr. Gregory M. Norris: manuscript concept, design, and supervision.

STUDY FUNDING

No targeted funding reported.

DISCLOSURE

W. Mohamed and P. Varade report no disclosures. G. Norris is on the speaker bureau for UCB, which manufactures Vimpat (lacosamide). Go to Neurology.org for full disclosures.

REFERENCES

1. Yoon W, Seo JJ, Kim JK, Cho KH, Park JG, Kang HK. Contrast enhancement and contrast extravasation on computed tomography after intra-arterial thrombolysis in patients with acute ischemic stroke. *Stroke* 2004;35:876–881.
2. Guluma KZ, Liu L, Hemmen TM, et al. Therapeutic hypothermia is associated with a decrease in urine output in acute stroke patients. *Resuscitation* 2010;81:1642–1647.

Neurology®

Teaching *NeuroImages*: "Subarachnoid hemorrhage" from decreased contrast elimination after therapeutic hypothermia

Wazim Mohamed, Preet Varade and Gregory M. Norris

Neurology 2014;82:e44-e45

DOI 10.1212/WNL.0000000000000088

This information is current as of February 3, 2014

Updated Information & Services	including high resolution figures, can be found at: http://n.neurology.org/content/82/5/e44.full
Supplementary Material	Supplementary material can be found at: http://n.neurology.org/content/suppl/2014/02/02/82.5.e44.DC1
References	This article cites 2 articles, 1 of which you can access for free at: http://n.neurology.org/content/82/5/e44.full#ref-list-1
Citations	This article has been cited by 1 HighWire-hosted articles: http://n.neurology.org/content/82/5/e44.full##otherarticles
Subspecialty Collections	This article, along with others on similar topics, appears in the following collection(s): CT http://n.neurology.org/cgi/collection/ct Subarachnoid hemorrhage http://n.neurology.org/cgi/collection/subarachnoid_hemorrhage
Permissions & Licensing	Information about reproducing this article in parts (figures, tables) or in its entirety can be found online at: http://www.neurology.org/about/about_the_journal#permissions
Reprints	Information about ordering reprints can be found online: http://n.neurology.org/subscribers/advertise

Neurology® is the official journal of the American Academy of Neurology. Published continuously since 1951, it is now a weekly with 48 issues per year. Copyright © 2014 American Academy of Neurology. All rights reserved. Print ISSN: 0028-3878. Online ISSN: 1526-632X.

