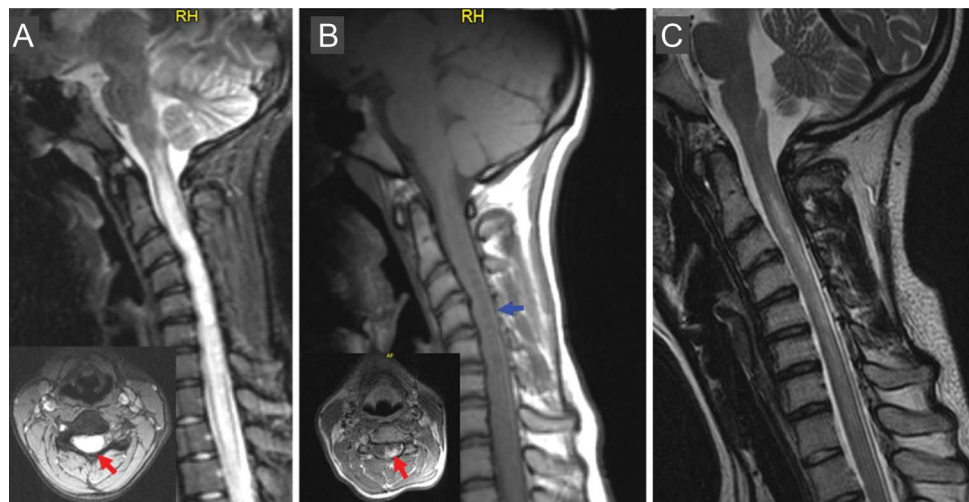


Teaching NeuroImages: Neuromyelitis optica misdiagnosed as spinal cord tumor

Georgios Tsivgoulis, MD
Stefanos Kontokostas,
MD
Efstathios Boviatis, MD
Anastasios Bonakis, MD
Leonidas Stefanis, MD
Konstantinos
Voumvourakis, MD

Correspondence to
Dr. Tsivgoulis:
tsivgoulisgiorg@yahoo.gr

Figure MRI findings of neuromyelitis optica before and after rescue plasmapheresis



(A) Sagittal T2 fat-saturation cervical cord MRI shows an extensive (C2-T4 level) hyperintense lesion involving nearly the whole cord cross-section (insert, red arrow). (B) Sagittal T1 shows “swollen cord” appearance with areas of central hypointensity (blue arrow) that may reflect necrosis, as necrosis has been found on histopathologic specimens in patients with neuromyelitis optica. Enhancement was noted in the left cross-section of the spinal cord after gadolinium injection (insert, red arrow). (C) Substantial resolution of the T2-hyperintense lesion was shown on follow-up sagittal T2 brain MRI following rescue plasmapheresis.

A 17-year-old girl presented with acute-onset cervical pain, followed by left arm weakness and gait disturbances. Spinal cord astrocytoma was diagnosed by MRI performed at an outpatient facility (figure, A and B). The patient was admitted to the neurosurgery department to undergo spinal cord biopsy. A second neurologic evaluation indicated neuromyelitis optica (NMO) as the most likely diagnosis, which was confirmed by NMO-immunoglobulin G seropositivity. The patient was treated with rescue plasmapheresis with substantial clinical and radiologic (figure, C) improvement.

NMO presenting with longitudinally extensive spinal cord lesions resulting in a “swollen cord” appearance and involving a whole cross-sectional area of the cord may be initially misdiagnosed as spinal cord intramedullary tumor.^{1,2} Spinal cord tumors should be added to the differential diagnosis of NMO including transverse myelitis, spinal cord ischemia, and systemic autoimmune disease.

AUTHOR CONTRIBUTIONS

Georgios Tsivgoulis: study design, drafting and revising the manuscript. Stefanos Kontokostas: data collection, critical comments during manuscript revision. Efstathios Boviatis: data collection, critical comments during manuscript revision. Anastasios Bonakis: critical comments during manuscript revision. Leonidas Stefanis: critical comments during manuscript revision. Konstantinos Voumvourakis: study design, drafting and revising the manuscript.

STUDY FUNDING

Dr. Tsivgoulis was supported by the European Regional Development Fund—Project FNUSA-ICRC (no. CZ.1.05/1.1.00/02.0123).

DISCLOSURE

The authors report no disclosures relevant to the manuscript. Go to Neurology.org for full disclosures.

REFERENCES

- Habek M, Adamec I, Brinar VV. Spinal cord tumor versus transverse myelitis. *Spine J* 2011;1:1143–1145.
- Brinar M, Rados M, Habek M, Poser CM. Enlargement of the spinal cord: inflammation or neoplasm? *Clin Neurol Neurosurg* 2006;108:284–289.

Download teaching slides:
www.neurology.org

From the Second Department of Neurology (G.T., S.K., A.B., L.S., K.V.) and Second Department of Neurosurgery (E.B.), University of Athens, School of Medicine, “Attikon” University Hospital, Greece; and the International Clinical Research Center (G.T.), St. Anne’s University Hospital, Brno, Czech Republic.

Neurology®

Teaching *NeuroImages*: Neuromyelitis optica misdiagnosed as spinal cord tumor

Georgios Tsivgoulis, Stefanos Kontokostas, Efstathios Boviatsis, et al.

Neurology 2014;82:e33

DOI 10.1212/WNL.0000000000000064

This information is current as of January 27, 2014

Updated Information & Services	including high resolution figures, can be found at: http://n.neurology.org/content/82/4/e33.full
Supplementary Material	Supplementary material can be found at: http://n.neurology.org/content/suppl/2014/01/26/82.4.e33.DC1
References	This article cites 2 articles, 0 of which you can access for free at: http://n.neurology.org/content/82/4/e33.full#ref-list-1
Subspecialty Collections	This article, along with others on similar topics, appears in the following collection(s): Devic's syndrome http://n.neurology.org/cgi/collection/devics_syndrome Transverse myelitis http://n.neurology.org/cgi/collection/transverse_myelitis
Permissions & Licensing	Information about reproducing this article in parts (figures, tables) or in its entirety can be found online at: http://www.neurology.org/about/about_the_journal#permissions
Reprints	Information about ordering reprints can be found online: http://n.neurology.org/subscribers/advertise

Neurology® is the official journal of the American Academy of Neurology. Published continuously since 1951, it is now a weekly with 48 issues per year. Copyright © 2014 American Academy of Neurology. All rights reserved. Print ISSN: 0028-3878. Online ISSN: 1526-632X.

