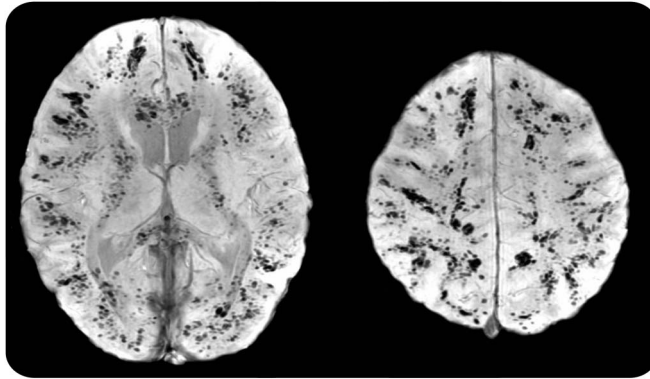


# Diffuse cerebral petechial hemorrhage in an 8-year-old girl with MRSA pneumonia and sepsis

**Figure** Susceptibility-weighted MRI of cerebral hemispheres



Innumerable discrete petechial hemorrhages throughout the cerebral hemispheres demonstrated on axial susceptibility-weighted MRI. The majority of the lesions are located at the gray-white interface.

An 8-year-old girl in septic shock due to necrotizing methicillin-resistant *Staphylococcus aureus* (MRSA) pneumonia developed signs of end-organ damage, new right hemiplegia, and left gaze preference. Susceptibility-weighted MRI demonstrated extensive multifocal petechial hemorrhage preferentially at the gray-white matter interface due to septic microemboli (figure). Mechanisms of hemorrhage include small-vessel occlusion leading to mycotic aneurysm formation with rupture or pyogenic arteritis without aneurysm formation.<sup>1</sup> Intracranial hemorrhage associated with metastatic staphylococcal infections is rarely described<sup>2</sup> and is especially noteworthy with diffuse cerebral petechial hemorrhage in the setting of metastatic MRSA.

*Mitchel T. Williams, MD, Huiyan Jiang, MD*

From the Department of Neurology, Children's Hospital of Michigan, Wayne State University, Detroit.

*Author contributions:* M. Williams: study concept and design, acquisition and interpretation of data, writing of draft manuscript. H. Jiang: discussion of case and revision of manuscript.

*Study funding:* No targeted funding reported.

*Disclosure:* The authors report no disclosures relevant to the manuscript. Go to Neurology.org for full disclosures.

*Correspondence to Dr. Williams:* [mitchellwilliams8@gmail.com](mailto:mitchellwilliams8@gmail.com)

1. Masuda J, Yutani C, Waki R, Ogata J, Kuriyama Y, Yamaguchi T. Histopathological analysis of the mechanisms of intracranial hemorrhage complicating infective endocarditis. *Stroke* 1992;23:843–850.
2. Pniitt AA, Rubin RH, Karchmer AW, Duncan GW. Neurologic complications of bacterial endocarditis. *Medicine* 1978;57:329–343.

# Neurology®

## Diffuse cerebral petechial hemorrhage in an 8-year-old girl with MRSA pneumonia and sepsis

Mitchel T. Williams and Huiyan Jiang

*Neurology* 2014;82;282

DOI 10.1212/WNL.0000000000000039

**This information is current as of January 20, 2014**

<b>Updated Information &amp; Services</b>	including high resolution figures, can be found at: <a href="http://n.neurology.org/content/82/3/282.full">http://n.neurology.org/content/82/3/282.full</a>
<b>References</b>	This article cites 2 articles, 1 of which you can access for free at: <a href="http://n.neurology.org/content/82/3/282.full#ref-list-1">http://n.neurology.org/content/82/3/282.full#ref-list-1</a>
<b>Subspecialty Collections</b>	This article, along with others on similar topics, appears in the following collection(s): <b>All Imaging</b> <a href="http://n.neurology.org/cgi/collection/all_imaging">http://n.neurology.org/cgi/collection/all_imaging</a> <b>Bacterial infections</b> <a href="http://n.neurology.org/cgi/collection/bacterial_infections">http://n.neurology.org/cgi/collection/bacterial_infections</a> <b>Intracerebral hemorrhage</b> <a href="http://n.neurology.org/cgi/collection/intracerebral_hemorrhage">http://n.neurology.org/cgi/collection/intracerebral_hemorrhage</a> <b>Pediatric stroke; see Cerebrovascular Disease/ Childhood stroke</b> <a href="http://n.neurology.org/cgi/collection/pediatric_stroke_see_cerebrovascular_disease-childhood_stroke">http://n.neurology.org/cgi/collection/pediatric_stroke_see_cerebrovascular_disease-childhood_stroke</a>
<b>Permissions &amp; Licensing</b>	Information about reproducing this article in parts (figures, tables) or in its entirety can be found online at: <a href="http://www.neurology.org/about/about_the_journal#permissions">http://www.neurology.org/about/about_the_journal#permissions</a>
<b>Reprints</b>	Information about ordering reprints can be found online: <a href="http://n.neurology.org/subscribers/advertise">http://n.neurology.org/subscribers/advertise</a>

*Neurology*® is the official journal of the American Academy of Neurology. Published continuously since 1951, it is now a weekly with 48 issues per year. Copyright © 2014 American Academy of Neurology. All rights reserved. Print ISSN: 0028-3878. Online ISSN: 1526-632X.

