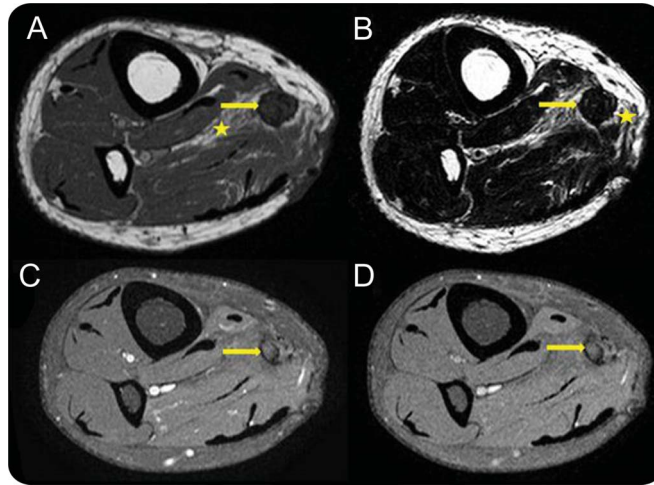


Teaching NeuroImages: Posttraumatic neuroma-in-continuity of the right tibial nerve

Sathya Narayanan, MBBS
Radha Sarawagi, MD

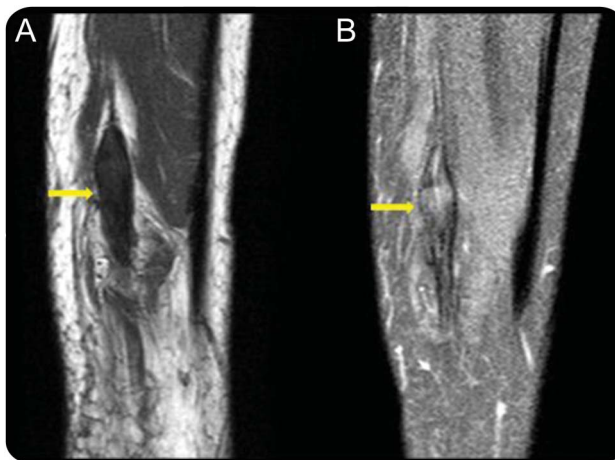
Correspondence to
Dr. Narayanan:
sathyadr88@gmail.com

Figure 1 MRI right leg



Axial T1-weighted (A) and T2-weighted (B) MRI of the right leg show thickened tibial nerve (arrow) isointense to muscles with perineural scarring (asterisk). Axial T1-weighted fat suppressed pregadolinium (C) and postgadolinium contrast images (D) reveal no significant enhancement of the lesion.

Figure 2 MRI right leg



Sagittal T1-weighted precontrast without fat suppression (A) and T1-weighted postcontrast fat-suppressed (B) MRI show fusiform thickening of the tibial nerve with nerve continuity on either side without significant enhancement of the lesion.

A 40-year-old man with a history of penetrating injury to the right lower leg complained of shooting pain along the distribution of the tibial nerve and the small nodule beneath the cutaneous scar. MRI demonstrated

nonenhancing fusiform thickening of the tibial nerve, which was isointense to muscle with perineural scarring (figures 1 and 2). The features were characteristic of posttraumatic neuroma-in-continuity.

Download teaching
slides: Neurology.org

From the Department of Radiology, Mahatma Gandhi Medical College and Research Institute, Pondicherry, India.

Go to Neurology.org for full disclosures. Funding information and disclosures deemed relevant by the authors, if any, are provided at the end of the article.

Posttraumatic neuromas are divided into neuroma-in-continuity and end-bulb neuroma. Neuroma-in-continuity is fusiform thickening of nerve due to injury or chronic friction of intact nerve. End-bulb neuroma occurs in completely transected nerve, which is not in apposition with distal nerve.¹

Perineural fibrosis, T2 hypointensity, and absence of contrast enhancement (figure 2) differentiate neuroma-in-continuity from nerve sheath tumors.²

AUTHOR CONTRIBUTIONS

Sathya Narayanan: data acquisition, drafting of manuscript. Radha Sarawagi: data acquisition, drafting and revising of manuscript, concept of the manuscript.

STUDY FUNDING

No targeted funding reported.

DISCLOSURE

The authors report no disclosures relevant to the manuscript. Go to Neurology.org for full disclosures.

REFERENCES

1. Mark D, Murphey MD, Smith WS, et al. Imaging of musculoskeletal neurogenic tumors: radiologic-pathologic correlation. *Radiographics* 1999;19:1253–1280.
2. Chhabra A, Andreisek G, Soldatos T, et al. MR neurography: past, present, and future. *AJR Am J Roentgenol* 2011; 197:583–591.

Neurology®

Teaching NeuroImages: Posttraumatic neuroma-in-continuity of the right tibial nerve

Sathya Narayanan and Radha Sarawagi

Neurology 2014;82:e198-e199

DOI 10.1212/WNL.0000000000000472

This information is current as of June 2, 2014

Updated Information & Services	including high resolution figures, can be found at: http://n.neurology.org/content/82/22/e198.full
Supplementary Material	Supplementary material can be found at: http://n.neurology.org/content/suppl/2014/06/01/82.22.e198.DC1
References	This article cites 2 articles, 0 of which you can access for free at: http://n.neurology.org/content/82/22/e198.full#ref-list-1
Subspecialty Collections	This article, along with others on similar topics, appears in the following collection(s): All Clinical Neurology http://n.neurology.org/cgi/collection/all_clinical_neurology Clinical neurology examination http://n.neurology.org/cgi/collection/clinical_neurology_examination Neuropathic pain http://n.neurology.org/cgi/collection/neuropathic_pain Peripheral nerve trauma http://n.neurology.org/cgi/collection/peripheral_nerve_trauma Peripheral neuropathy http://n.neurology.org/cgi/collection/peripheral_neuropathy
Permissions & Licensing	Information about reproducing this article in parts (figures, tables) or in its entirety can be found online at: http://www.neurology.org/about/about_the_journal#permissions
Reprints	Information about ordering reprints can be found online: http://n.neurology.org/subscribers/advertise

Neurology® is the official journal of the American Academy of Neurology. Published continuously since 1951, it is now a weekly with 48 issues per year. Copyright © 2014 American Academy of Neurology. All rights reserved. Print ISSN: 0028-3878. Online ISSN: 1526-632X.

