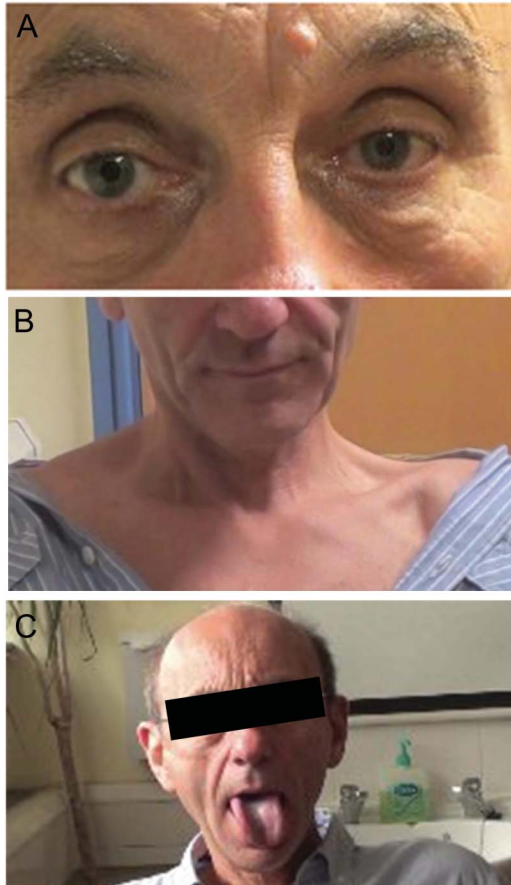


Teaching NeuroImages: Internal carotid artery dissection presenting as Villaret syndrome

Ogechukwu Okpala*
Anna Von Essen*
Gemma Cummins,
MRCPI
Mark Manford, MD,
FRCP

Correspondence to
Dr. Cummins:
gac54@cam.ac.uk

Figure 1 Cranial nerve palsies in Villaret syndrome

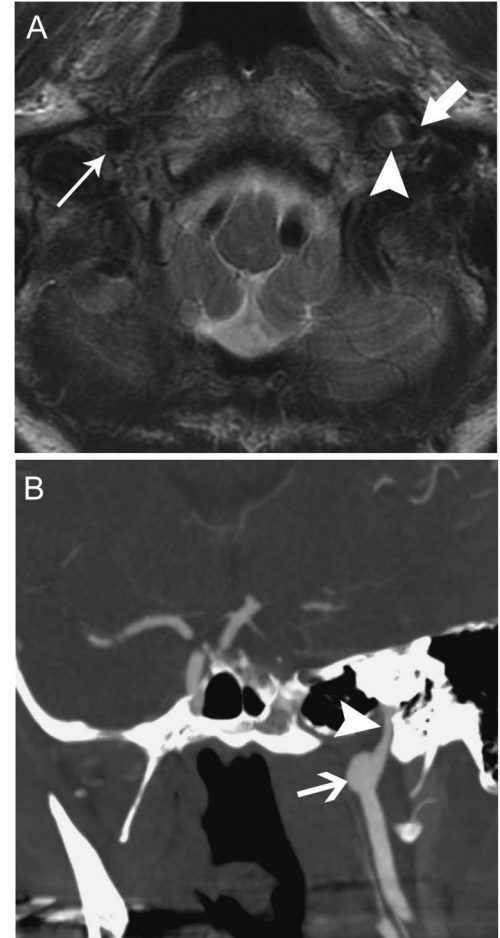


(A) Left Horner sign. (B) Wasting of the left sternocleidomastoid muscle. (C) Deviation of the tongue to the left.

A 63-year-old man presented with headache, hoarseness, and dysphagia. He had a left-sided Horner syndrome and wasting of the left sternocleidomastoid muscle. His tongue was deviated to the left on protrusion (figure 1). MRI and CT angiography revealed a distal left internal carotid artery dissection (figure 2).

Villaret syndrome is a rare clinical entity comprising IX, X, XI, and XII cranial nerve palsies together with Horner sign.¹ This constellation of signs should prompt the clinician to seek pathology in the retroparotid space,

Figure 2 Radiologic evaluation of carotid artery dissection



(A) Axial T2-weighted MRI shows normal flow void in the right internal carotid artery (ICA) (thin arrow). The flow void of the left ICA (thick arrow) is narrowed by the medially positioned intramural hematoma, which is of mixed signal intensity (arrowhead). (B) CT angiography shows a pseudoaneurysm of the left ICA (thin arrow) proximal to an area of luminal stenosis (arrowhead).

as this is the only area where the lower 4 cranial nerves and sympathetic fibers to the eye lie in close proximity. When the sympathetic fibers are spared, it is termed Collet-Sicard syndrome.²

[Download teaching slides:
Neurology.org](#)

*These authors contributed equally to this work.

From the Department of Neurology, Addenbrooke's Hospital, Cambridge University Hospitals, Cambridge Biomedical Campus, UK.

Go to [Neurology.org](#) for full disclosures. Funding information and disclosures deemed relevant by the authors, if any, are provided at the end of the article.

AUTHOR CONTRIBUTIONS

Oge Okpala: drafting the manuscript, acquisition of data. Anna Von Essen: drafting the manuscript, acquisition of data. Dr. Gemma Cummins: drafting and revising the manuscript. Dr. Mark Manford: study design, supervision of study.

ACKNOWLEDGMENT

The authors thank Dr. Daniel Scoffings, Cambridge University Hospitals, for providing the radiology images.

STUDY FUNDING

No targeted funding reported.

DISCLOSURE

The authors report no disclosures relevant to the manuscript. Go to Neurology.org for full disclosures.

REFERENCES

1. Villaret M. Le syndrome nerveux de l'espace rétro-parotidien postérieur. *Rev Neurol* 1916;29:188–190.
2. Collet FJ. Sur un nouveau syndrome paralytique pharyngo-larynge par blessure de guerre (hemiplegie glosso-laryngo-scapulo-pharyngee). *Lyon Med* 1915;124: 121–129.

Neurology®

Teaching *NeuroImages*: Internal carotid artery dissection presenting as Villaret syndrome

Ogechukwu Okpala, Anna Von Essen, Gemma Cummins, et al.

Neurology 2014;82:e110-e111

DOI 10.1212/WNL.0000000000000266

This information is current as of March 31, 2014

| | |
|---|--|
| Updated Information & Services | including high resolution figures, can be found at: http://n.neurology.org/content/82/13/e110.full |
| Supplementary Material | Supplementary material can be found at: http://n.neurology.org/content/suppl/2014/03/29/82.13.e110.DC1 |
| References | This article cites 2 articles, 0 of which you can access for free at: http://n.neurology.org/content/82/13/e110.full#ref-list-1 |
| Subspecialty Collections | This article, along with others on similar topics, appears in the following collection(s): All Cerebrovascular disease/Stroke http://n.neurology.org/cgi/collection/all_cerebrovascular_disease_stroke All Imaging http://n.neurology.org/cgi/collection/all_imaging Carotid artery dissection http://n.neurology.org/cgi/collection/carotid_artery_dissection Cranial neuropathy http://n.neurology.org/cgi/collection/cranial_neuropathy |
| Permissions & Licensing | Information about reproducing this article in parts (figures, tables) or in its entirety can be found online at: http://www.neurology.org/about/about_the_journal#permissions |
| Reprints | Information about ordering reprints can be found online: http://n.neurology.org/subscribers/advertise |

Neurology® is the official journal of the American Academy of Neurology. Published continuously since 1951, it is now a weekly with 48 issues per year. Copyright © 2014 American Academy of Neurology. All rights reserved. Print ISSN: 0028-3878. Online ISSN: 1526-632X.

