

Neurology[®]

Table of Contents

Volume 81, Number 7, August 13, 2013
Neurology.org

THE MOST WIDELY READ AND HIGHLY CITED PEER-REVIEWED
NEUROLOGY JOURNAL



IN FOCUS

- 607 Spotlight on the August 13 Issue
- 640 This Week's *Neurology*[®] Podcast



EDITORIALS


- 608 Multimodal imaging for acute stroke: When is it worth it?
S. Chaturvedi and M. Selim
- 610 Toward a better understanding of PFO and stroke risk
S.R. Messé and W.N. Kernan


IN MEMORIAM

- 612 Hilary Koprowski, MD (1916–2013)
D. Gilden

ARTICLES

- 614 Comparison of the response to endovascular reperfusion in relation to site of arterial occlusion
R. Lemmens, M. Mlynash, M. Straka, S. Kemp, R. Bammer, M.P. Marks, G.W. Albers, and M.G. Lansberg
Editorial, p. 608
- 619 An index to identify stroke-related vs incidental patent foramen ovale in cryptogenic stroke
D.M. Kent, R. Ruthazer, C. Weimar, J.-L. Mas, J. Serena, S. Homma, E. Di Angelantonio, M.R. Di Tullio, J.S. Lutz, M.S.V. Elkind, J. Griffith, C. Jaigobin, H.P. Mattle, P. Michel, M.-L. Mono, K. Nedeltchev, F. Papetti, and D.E. Thaler
 **Editorial, p. 610**
- 626 Prevalence and mechanisms of cortical superficial siderosis in cerebral amyloid angiopathy
A. Charidimou, R.H. Jäger, Z. Fox, A. Peeters, Y. Vandermeeren, P. Laloux, J.-C. Baron, and D.J. Werring

- 633 Central pain modulation after subthalamic nucleus stimulation: A crossover randomized trial
A. Marques, O. Chassin, D. Morand, B. Pereira, B. Debilly, P. Derost, M. Ulla, J.J. Lemaire, and F. Durif
- 641 Contribution of cortical lesion subtypes at 7T MRI to physical and cognitive performance in MS
A.S. Nielsen, R.P. Kinkel, N. Madigan, E. Tinelli, T. Benner, and C. Mainero

- 650 Very low levels of education and cognitive reserve: A clinicopathologic study
J.M. Farfel, R. Nitrini, C.K. Suemoto, L.T. Grinberg, R.E.L. Ferretti, R.E.P. Leite, E. Tampellini, L. Lima, D.S. Farias, R.C. Neves, R.D. Rodriguez, P.R. Menezes, F. Fregni, D.A. Bennett, C.A. Pasqualucci, and W. Jacob Filho, on behalf of the Brazilian Aging Brain Study Group


- 658 Naming vs knowing faces in primary progressive aphasia: A tale of 2 hemispheres
T. Gefen, C. Wieneke, A. Martersteck, K. Whitney, S. Weintraub, M.-M. Mesulam, and E. Rogalski


- 665 Networks underlying paroxysmal fast activity and slow spike and wave in Lennox-Gastaut syndrome
N. Pillay, J.S. Archer, R.A.B. Badawy, D.F. Flanagan, S.F. Berkovic, and G. Jackson


- 674 α -[¹¹C]-Methyl-L-tryptophan-PET in 191 patients with tuberous sclerosis complex
H.T. Chugani, A.F. Luat, A. Kumar, R. Govindan, K. Pawlik, and E. Asano

- 681 Intellectual disability and bleeding diathesis due to deficient CMP-sialic acid transport
M. Mohamed, A. Ashikov, M. Guillard, J.H. Robben, S. Schmidt, B. van den Heuvel, A.P.M. de Brouwer, R. Gerardy-Schahn, P.M.T. Deen, R.A. Wevers, D.J. Lefeber, and E. Morava

CLINICAL/SCIENTIFIC NOTES

- 688 Head impulses in complete bilateral vestibular loss: Catch-up saccades require visual input
N. Lehnen, S. Glasauer, K. Jahn, and K.P. Weber

VIDEO NEUROIMAGES

- 691 Sleep apnea and snoring
P. Kavcic, A. Koren, B. Koritnik, and L. Dolenc Groselj


REFLECTIONS: NEUROLOGY AND THE HUMANITIES

- 692 Inside the Superstorm That Rattled NYU
A. Kurzweil

CONTINUED

Neurology[®]

Table of Contents

continued



RESIDENT & FELLOW SECTION

- e42 Mystery Case: An unexpected complication of IV thrombolysis for acute ischemic stroke
S.A. Sheth and A.H. Yee
- e44 Teaching NeuroImages: Characteristic phenotype of Ullrich congenital muscular dystrophy
W.K.M. Liew and B.T. Darras
- e46 Teaching NeuroImages: Diffuse cerebral neurosarcoidosis mimicking gliomatosis cerebri
R.S. Ramanathan, K. Malhotra, and T. Scott

WRITECLICK: EDITOR'S CHOICE

- 694 Screening for impulse control symptoms in patients with de novo Parkinson disease: A case-control study
C. O'Callaghan, M. Hornberger; Author Response: D. Weintraub, A. Siderowf, K. Papay
- 695 Clinical course of idiopathic intracranial hypertension with transverse sinus stenosis
F. Bono, A. Quattrone; Author Response: B. B. Bruce, N. J. Newman, V. Biousse

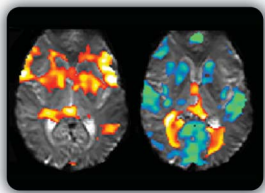
DEPARTMENT

- A29 In the Next Issue of *Neurology*[®]

Podcast at www.neurology.org CME Video Patient Page LOE classification LOE recommendation



tinyurl.com/neurologyfan twitter.com/GreenJournal



Cover image: EEG-fMRI findings from a patient with Lennox-Gastaut syndrome in whom robust activation maps of both paroxysmal fast activity and slow spike and wave were obtained. See page 665.

Look for **Publish Ahead of Print** articles and editorials under the Ahead of Print tab at Neurology.org



Neurology[®] Online CME Program

Earn CME while reading *Neurology*. This program is available only to online *Neurology* subscribers. Simply read the articles marked CME, go to www.neurology.org, and click on CME. This will provide all of the information necessary to get started. The American Academy of Neurology (AAN) is accredited by the Accreditation Council for Continuing Medical Education (ACCME) to sponsor continuing medical education for physicians. *Neurology* is planned and produced in accordance with the ACCME Essentials. For more information, contact AAN Member Services at 800-879-1960.

Neurology®

81 (7)

Neurology 2013;81:e46-695

This information is current as of January 1, 2013

Updated Information & Services

including high resolution figures, can be found at:
<http://n.neurology.org/content/81/7.full>

Permissions & Licensing

Information about reproducing this article in parts (figures, tables) or in its entirety can be found online at:
http://www.neurology.org/about/about_the_journal#permissions

Reprints

Information about ordering reprints can be found online:
<http://n.neurology.org/subscribers/advertise>

Neurology® is the official journal of the American Academy of Neurology. Published continuously since 1951, it is now a weekly with 48 issues per year. Copyright . All rights reserved. Print ISSN: 0028-3878. Online ISSN: 1526-632X.

