

Pearls & Oysters: Transient Horner syndrome associated with autonomic dysreflexia

Jacquelyn J. Cragg, MPH
Andrei V. Krassioukov,
MD, PhD, FRCPC

Correspondence to
Dr. Krassioukov:
krassioukov@icord.org

PEARLS

- Autonomic dysreflexia is a potentially life-threatening condition that occurs in individuals with high thoracic and cervical spinal cord injuries (SCIs) and is characterized by severe episodic hypertension.
- If left unmanaged, autonomic dysreflexia can result in myocardial infarction, intracranial hemorrhage, or death.
- Episodes of autonomic dysreflexia are typically associated with severe headache, blurred vision, flushing, diaphoresis, anxiety, and piloerection above the level of the injury, while below the level of the injury, the skin is typically pale and cold. Reflexive bradycardia is commonly present due to the elevated blood pressure, although tachycardia can occur.
- The typical resting systolic blood pressure in individuals with high cervical SCI is low (90–100 mm Hg).

OY-STER

- Episodes of autonomic dysreflexia can in some cases be asymptomatic or associated with unusual signs/symptoms, as in this case report.

CASE REPORT A 34-year-old man with a complete cervical SCI (C5 AIS A according to the American Spinal Injury Association Impairment Scale criteria) was examined at a follow-up appointment, 9 years after a motor vehicle accident. During his visit, he developed a sudden onset of pounding headache and heart palpitations that were typical symptoms of autonomic dysreflexia. His assessment revealed unilateral flushing on the left side of his face and chest, with diaphoresis on the same side (figure, A). His right pupil was constricted, and the right side of his face was pale and dry. His blood pressure measured 240/60 mm Hg with a heart rate of 50 beats per minute (bpm). These signs and symptoms occurred simultaneously. From his medical history, it was known that his typical resting blood pressure is 90/60 mm Hg with a heart rate of

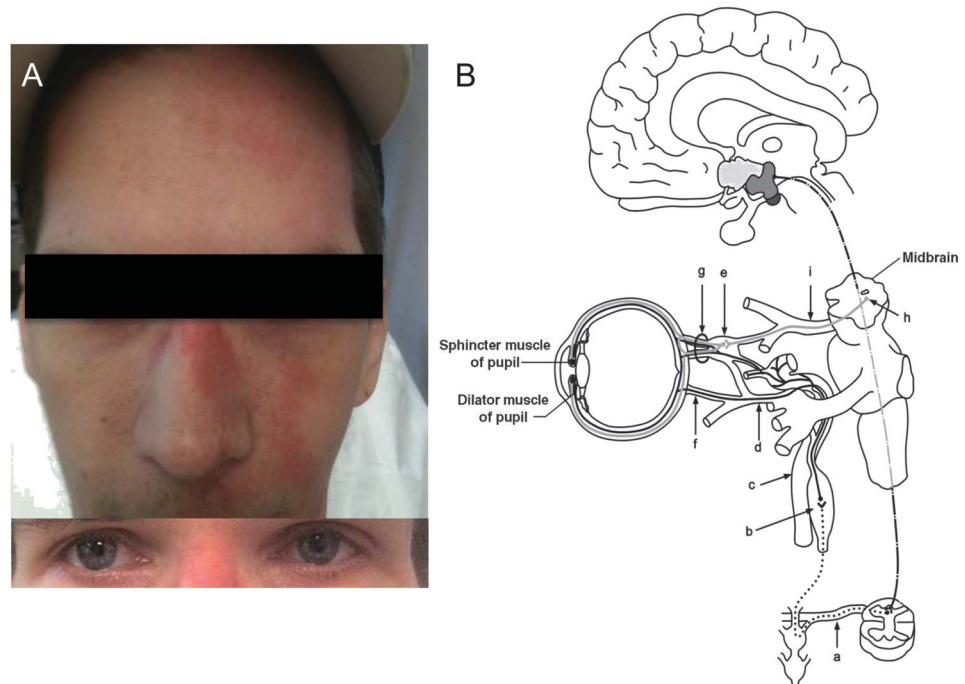
75 bpm. It was also known that he has a neurogenic bladder, frequent urinary tract infections, and a history of progressive cervical cord syringomyelia. Within 10 minutes of emptying his bladder, his blood pressure returned to baseline, and the symptoms accompanying the episode of autonomic dysreflexia also resolved, including the right-sided Horner syndrome.

DISCUSSION Horner syndrome refers to the cluster of signs—ptosis, miosis, and anhidrosis—that occur as a result of interruption of the sympathetic supply to half of the face. Depending on the anatomical location of the underlying pathologic process, Horner syndrome usually is associated with unique clinical features classified into central, preganglionic, and postganglionic types (figure, B).¹

While Horner syndrome occurs as a result of interruption of sympathetic activity, autonomic dysreflexia is defined as acute episodic hypertension resulting from overactivity of spinal sympathetic circuits in individuals with SCI. The etiology of autonomic dysreflexia is not entirely understood. However, the loss of supraspinal inhibitory inputs following cervical or high thoracic injuries (typically at or above the sixth thoracic spinal segment [T6]) is among the primary causes for the development of autonomic dysreflexia. These injuries isolate sympathetic preganglionic neurons that supply the mesenteric arterial bed from inhibitory supraspinal control. In addition, evidence from human and animal studies indicates there are plastic changes in the spinal cord and periphery that result in this aberrant cardiovascular response following SCI. Namely, hyperresponsiveness of vascular α -adrenergic receptors or impaired reuptake of catecholamines following SCI may contribute to the development of autonomic dysreflexia.² Injury-induced hypertrophy and sprouting of primary sensory neurons could also contribute.³ Furthermore, SCI-induced alterations of intraspinal autonomic circuits, including abnormal connections on interneurons and morphologic alterations of sympathetic preganglionic neurons, may also contribute to the etiology of autonomic dysreflexia.^{4,5}

From the International Collaboration on Repair Discoveries (ICORD) (J.J.C., A.V.K.), School of Population and Public Health (J.J.C.), and Department of Medicine, Division of Physical Medicine and Rehabilitation (A.V.K.), University of British Columbia, Vancouver; and GF Strong Rehabilitation Centre (A.V.K.), Vancouver Health Authority, Vancouver, Canada.

Go to Neurology.org for full disclosures. Funding information and disclosures deemed relevant by the authors, if any, are provided at the end of the article.



(A) Photograph of the patient during the episode of autonomic dysreflexia. There was noticeable flushing of the left side of his face and upper part of his chest. His right pupil was constricted (miosis), and the right side of his face was pale and dry. (B) Schematic diagram of the autonomic innervations of the eye for Horner syndrome in the present case. A posterolateral hypothalamic neuron (dashed line) descends into the brainstem and intermediolateral column of the spinal cord, and synapses on spinal sympathetic preganglionic neurons localized within the cervical and thoracic levels of the spinal cord. Axons of these neurons (preganglionic fibers [a], dotted line) leave the spinal cord and synapse on postganglionic neurons within the superior cervical ganglion (b). Finally, sympathetic postganglionic fibers (solid line) innervate the target organ. Neural fibers for sweating of the face, except the medial forehead, travel with the external carotid artery. Sympathetic postganglionic fibers travel with the carotid artery (c) into the cavernous sinus and with the ophthalmic branch (d) of the fifth cranial nerve join the nasociliary branch of the fifth cranial nerve or pass through the ciliary ganglion (e) directly, reaching the eye as long (f) and short (g) ciliary nerves. Preganglionic parasympathetic fibers (gray lines) arise from the accessory oculomotor nucleus (h), exit as the oculomotor nerve (i), synapse at the ciliary ganglion, and reach the eye as short ciliary nerves. Schematic and portion of figure legend modified and reprinted with permission from the *American Journal of Roentgenology*.¹

Transient Horner syndrome has been previously described in another study with respect to hypertension (in an able-bodied individual) where Horner syndrome was resolved 1 month after the initial event.⁶ The authors attributed Horner syndrome in this able-bodied individual to a TIA.⁶ In addition, autonomic dysreflexia has been previously described in relation to syringomyelia.⁷ However, transient Horner syndrome has not been previously described in relation to an episode of autonomic dysreflexia.

It may be that in our patient, as a result of the autonomic dysreflexia-induced hypertension, there was an increase in intramedullary pressure with a concomitant increase of intrasyrinx pressure that would selectively compromise sympathetic output.⁸ We could only speculate that the pressure was distributed asymmetrically on the preserved tissue of the spinal cord, with more prominent compression of the right side during the episode of autonomic dysreflexia. With resolution of the episode and normalization of blood pressure, the intraspinal pressure would decline, and pressure on the

fragile nervous tissue would resolve, resulting in the disappearance of Horner syndrome.

While this was an unusual presentation of autonomic dysreflexia, the condition is relatively common among individuals with high thoracic and cervical SCI. Autonomic dysreflexia occurs to some extent in up to 90% of these individuals and can be a daily event for many people with SCI.⁵ Autonomic dysreflexia also occurs, though less frequently, in nontraumatic SCIs, such as multiple sclerosis.⁹

Although autonomic dysreflexia can in some cases be silent, there are several characteristic signs and symptoms. In addition to the aforementioned signs and symptoms of headache, flushing, diaphoresis, and elevated blood pressure, other signs and symptoms include reflexive bradycardia, anxiety, blurred vision, nasal congestion, and piloerection.⁵

Episodes of autonomic dysreflexia are triggered by painful or nonpainful stimuli originating from below the level of injury, and are most commonly related to bladder or bowel irritation.⁵ Such stimuli may include

bladder distention, bladder or kidney stones, blocked or kinked catheters, urinary tract infections, fecal impaction, constipation, and bladder or rectal examination. Other stimuli may include tight clothing or equipment, hemorrhoids, sunburns, pressure sores, ingrown toenails, broken bones or fractures, sexual activity, menstruation, and labor.

It is important for the clinical management of patients with SCI to recognize that individuals with higher injuries typically have low resting systolic blood pressure (90–100 mm Hg), as in this case, so the elevated blood pressure from autonomic dysreflexia may go unrecognized upon initial presentation. In most instances, autonomic dysreflexia is resolved as soon as the irritating stimuli are removed. However, in some cases, malignant episodes can occur that require immediate medical attention. Autonomic dysreflexia has been linked to adverse events such as cerebral hemorrhage, myocardial ischemia, and even death.¹⁰

Guidelines for the management of autonomic dysreflexia recommend to first sit the patient upright in order to induce a decrease in blood pressure due to the orthostatic response.⁵ It is recommended next to loosen or remove restrictive clothing, and survey the precipitating causes. If systolic blood pressure remains above 150 mm Hg, it is recommended to use an antihypertensive agent such as nifedipine or captopril. Also, heart rate and blood pressure should be monitored regularly at 5-minute intervals. In this case, the cause of autonomic dysreflexia was bladder related, and antihypertensive agents were not necessary.

We report on an unusual presentation of a common condition among individuals with high thoracic and cervical SCIs. Early recognition and prompt management of this potentially life-threatening condition are imperative to reduce the risk of cardiac and cerebrovascular events in this population.

AUTHOR CONTRIBUTIONS

Both authors (A.V.K., J.J.C.) drafted and critically revised the manuscript for important intellectual content. A.V.K. collected the patient information.

STUDY FUNDING

Dr. Krassioukov is supported by grants from the Canadian Heart and Stroke Foundation, Canadian Institute of Health Research, Canadian Foundation for Innovation, Christopher and Dana Reeve Foundation, and Craig Neilsen Foundation. J.J. Cragg is supported by a University of British Columbia Killam Doctoral Scholarship.

DISCLOSURE

The authors report no disclosures relevant to this manuscript. Go to Neurology.org for full disclosures.

REFERENCES

1. Lee JH, Lee HK, Lee DH, Choi CG, Kim SJ, Suh DC. Neuroimaging strategies for three types of Horner syndrome with emphasis on anatomic location. *AJR Am J Roentgenol* 2007;188:W74–W81.
2. Alan N, Ramer LM, Inskip JA, et al. Recurrent autonomic dysreflexia exacerbates vascular dysfunction after spinal cord injury. *Spine J* 2010;10:1108–1117.
3. Ramer LM, van Stolk AP, Inskip JA, Ramer MS, Krassioukov AV. Plasticity of TRPV1-expressing sensory neurons mediating autonomic dysreflexia following spinal cord injury. *Front Physiol* 2012;3:257.
4. Krassioukov AV, Johns DG, Schramm LP. Sensitivity of sympathetically correlated spinal interneurons, renal sympathetic nerve activity, and arterial pressure to somatic and visceral stimuli after chronic spinal injury. *J Neurotrauma* 2002;19:1521–1529.
5. Krassioukov A, Warburton DE, Teasell R, Eng JJ, Spinal Cord Injury Rehabilitation Evidence Research Team. A systematic review of the management of autonomic dysreflexia after spinal cord injury. *Arch Phys Med Rehabil* 2009;90:682–695.
6. Williams GP, Lukaris A, Hawksworth NR. Transient Horner's syndrome associated with hypertension. *Eye* 2007;21:139–140.
7. Kerrison JB, Biousse V, Newman NJ. Isolated Horner's syndrome and syringomyelia. *J Neurol Neurosurg Psychiatry* 2000;69:131–132.
8. Milhorat TH, Capocelli AL Jr, Kotzen RM, Bolognese P, Heger IM, Cottrell JE. Intramedullary pressure in syringomyelia: clinical and pathophysiological correlates of syrinx distension. *Neurosurgery* 1997;41:1102–1110.
9. Kulcu DG, Akbas B, Citci B, Cihangiroglu M. Autonomic dysreflexia in a man with multiple sclerosis. *J Spinal Cord Med* 2009;32:198–203.
10. Eltorai I, Kim R, Vulpe M, Kasravi H, Ho W. Fatal cerebral hemorrhage due to autonomic dysreflexia in a tetraplegic patient: case report and review. *Paraplegia* 1992;30:355–360.

Neurology®

Pearls & Oy-sters: Transient Horner syndrome associated with autonomic dysreflexia

Jacquelyn J. Cragg and Andrei V. Krassioukov

Neurology 2013;81:e35-e37

DOI 10.1212/WNL.0b013e31829e6fe8

This information is current as of August 5, 2013

Updated Information & Services	including high resolution figures, can be found at: http://n.neurology.org/content/81/6/e35.full
References	This article cites 10 articles, 1 of which you can access for free at: http://n.neurology.org/content/81/6/e35.full#ref-list-1
Citations	This article has been cited by 1 HighWire-hosted articles: http://n.neurology.org/content/81/6/e35.full##otherarticles
Subspecialty Collections	This article, along with others on similar topics, appears in the following collection(s): Spinal cord trauma; see Trauma/spinal cord trauma http://n.neurology.org/cgi/collection/spinal_cord_trauma-see_trauma-spinal_cord_trauma
Permissions & Licensing	Information about reproducing this article in parts (figures, tables) or in its entirety can be found online at: http://www.neurology.org/about/about_the_journal#permissions
Reprints	Information about ordering reprints can be found online: http://n.neurology.org/subscribers/advertise

Neurology® is the official journal of the American Academy of Neurology. Published continuously since 1951, it is now a weekly with 48 issues per year. Copyright © 2013 American Academy of Neurology. All rights reserved. Print ISSN: 0028-3878. Online ISSN: 1526-632X.

