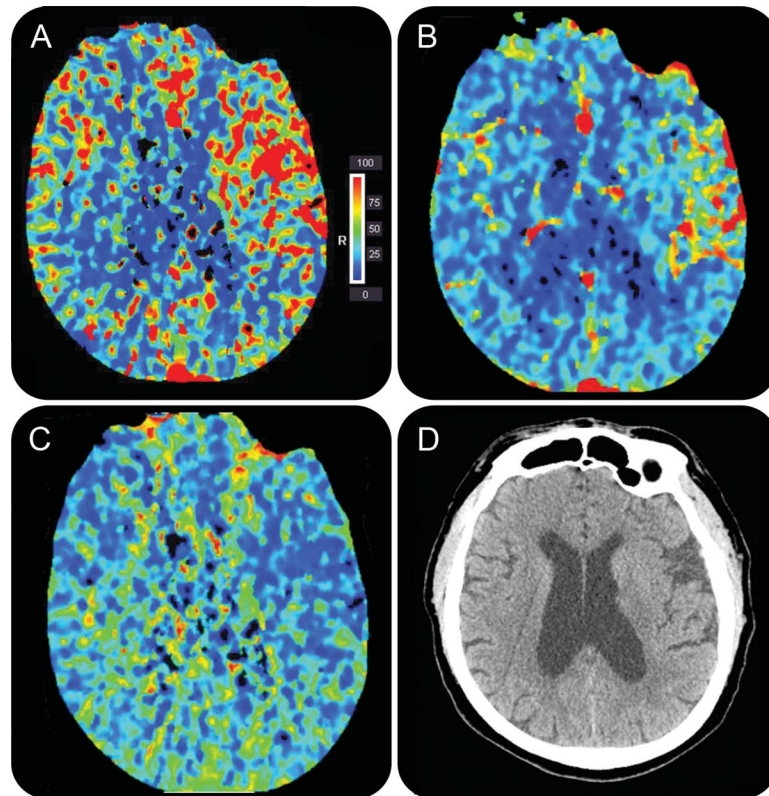


# Teaching NeuroImages: Perfusion imaging of cerebral hyperperfusion syndrome following revascularization

Vivek B. Kalra, MD  
Balaji Rao, MD  
Ajay Malhotra, MD

Correspondence to  
Dr. Kalra:  
Vivek.kalra@yale.edu

**Figure** CT perfusion performed 1 day following left carotid endarterectomy



CT shows left middle cerebral artery distribution increased relative cerebral blood flow (A), increased relative cerebral blood volume (B), and decreased mean transit time (C)—findings are consistent with cerebral hyperperfusion syndrome following revascularization. Noncontrast CT shows no hemorrhage or edema (D).

A 69-year-old man developed acute-onset confusion and hypertension with systolic pressures in the 160s 1 day after carotid endarterectomy for right facial droop from left hemispheric lacunar infarcts. CT perfusion (figure, A–D) demonstrated findings consistent with cerebral hyperperfusion syndrome (CHS) following revascularization. CHS is caused by loss of autoregulation, hypertension, and ischemia-reperfusion injury resulting in increased regional blood flow and vascular congestion.<sup>1</sup> CHS following revascularization may present as ipsilateral headache, focal seizure, or neurologic deficit. Nonperfusion imaging

may show intraparenchymal hemorrhage or edema. Labetalol and clonidine are used for aggressive blood pressure control until cerebral autoregulation is restored.<sup>2</sup>

## AUTHOR CONTRIBUTIONS

Vivek Kalra: drafting/revising the manuscript, analysis or interpretation of data, accepts responsibility for conduct of research and will give final approval. Balaji Rao: study concept or design, analysis or interpretation of data, accepts responsibility for conduct of research and will give final approval, acquisition of data. Ajay Malhotra: drafting/revising the manuscript, study concept or design, analysis or interpretation of data, accepts responsibility for conduct of research and will give final approval, acquisition of data, study supervision.

Download teaching slides:  
[www.neurology.org](http://www.neurology.org)

From the Department of Diagnostic Radiology, Yale-New Haven Medical Center, Yale University, New Haven, CT.

Go to [Neurology.org](http://Neurology.org) for full disclosures. Funding information and disclosures deemed relevant by the authors, if any, are provided at the end of the article.

### STUDY FUNDING

No targeted funding reported.

### DISCLOSURE

The authors report no disclosures relevant to the manuscript. Go to [Neurology.org](http://Neurology.org) for full disclosures.

### REFERENCES

1. Adhiaman V, Alexander S. Cerebral hyperperfusion syndrome following carotid endarterectomy. *QJM* 2007;100:239–244.
2. van Mook WN, Rennenberg RJ, Schurink GW, et al. Cerebral hyperperfusion syndrome. *Lancet Neurol* 2005;4:877–888.

# Neurology®

## Teaching *NeuroImages*: Perfusion imaging of cerebral hyperperfusion syndrome following revascularization

Vivek B. Kalra, Balaji Rao and Ajay Malhotra

*Neurology* 2013;81:e25-e26

DOI 10.1212/WNL.0b013e31829c5cae

**This information is current as of July 22, 2013**

<b>Updated Information &amp; Services</b>	including high resolution figures, can be found at: <a href="http://n.neurology.org/content/81/4/e25.full">http://n.neurology.org/content/81/4/e25.full</a>
<b>Supplementary Material</b>	Supplementary material can be found at: <a href="http://n.neurology.org/content/suppl/2013/07/21/81.4.e25.DC1">http://n.neurology.org/content/suppl/2013/07/21/81.4.e25.DC1</a>
<b>References</b>	This article cites 2 articles, 0 of which you can access for free at: <a href="http://n.neurology.org/content/81/4/e25.full#ref-list-1">http://n.neurology.org/content/81/4/e25.full#ref-list-1</a>
<b>Subspecialty Collections</b>	This article, along with others on similar topics, appears in the following collection(s): <b>All Cerebrovascular disease/Stroke</b> <a href="http://n.neurology.org/cgi/collection/all_cerebrovascular_disease_stroke">http://n.neurology.org/cgi/collection/all_cerebrovascular_disease_stroke</a> <b>CT</b> <a href="http://n.neurology.org/cgi/collection/ct">http://n.neurology.org/cgi/collection/ct</a>
<b>Permissions &amp; Licensing</b>	Information about reproducing this article in parts (figures, tables) or in its entirety can be found online at: <a href="http://www.neurology.org/about/about_the_journal#permissions">http://www.neurology.org/about/about_the_journal#permissions</a>
<b>Reprints</b>	Information about ordering reprints can be found online: <a href="http://n.neurology.org/subscribers/advertise">http://n.neurology.org/subscribers/advertise</a>

*Neurology*® is the official journal of the American Academy of Neurology. Published continuously since 1951, it is now a weekly with 48 issues per year. Copyright © 2013 American Academy of Neurology. All rights reserved. Print ISSN: 0028-3878. Online ISSN: 1526-632X.

